

Reliability of Registration in Imageless Navigation Total Hip Arthroplasty in Semilateral Decubitus Position

Yingyong Suksathien MD*,
Jithayut Suarjui MD*, Adisorn Chongmuenwai MD*

* Department of Orthopedic Surgery, Maharat Nakhon Ratchasima Hospital, Nakhon Ratchasima, Thailand

Background: One of the limitations in imageless navigation is the variability in bony landmark registration among surgeons. If the bony landmark registration is different among surgeons, the final cup position determined by the navigation will also be different.

Objective: To determine intra and inter-observer reliability of the bony landmark registration in three surgeons with varying experience in imageless navigation total hip arthroplasty (THA) in semilateral decubitus position.

Material and Method: The authors reviewed 60 cases receiving cementless THA with imageless navigation between June 2014 and April 2015. All cases were registered for anterior pelvic plane (APP) by three surgeons. The first surgeon (S1-YS) is senior staff with experience in imageless navigation, the second surgeon (S2-JS) is junior staff with one year of experience in imageless navigation (with more than 50 cases), and the third surgeon (S3-AC) is a fourth-year orthopedic resident with no experience in imageless navigation. Using the final cup position of the experienced surgeon as the gold standard to determine the reliability of registration.

Results: There were no significant differences in cup abduction angle between (S1) and (S2) ($p = 0.27$) and (S1) and (S3) ($p = 0.79$). There was no significant difference in cup anteversion angle between (S1) and (S2) ($p = 0.1$) but there was significant difference between (S1) and (S3) ($p < 0.001$). For the intra-observer reliability, the ICCs of abduction angle was 0.95 for (S2) and 0.86 for (S3) and the ICCs of anteversion angle was 0.91 for (S2) and 0.86 for (S3). For the inter-observer reliability, the ICCs of abduction angle between (S1) and (S2) was 0.89 and between (S1) and (S3) was 0.87, the ICCs of anteversion angle between (S1) and (S2) was 0.8 and between (S1) and (S3) was 0.72.

Conclusion: The reliability of registration was acceptable in abduction angle among surgeons. The reliability of registration was not acceptable only in anteversion angle between experienced (S1) and non-experienced surgeons (S3). For the surgeon with one year of experience in imageless navigation, the result of registration process was comparable to and reproducible with the experienced surgeon in both abduction and anteversion angles.

Keywords: Reliability, Imageless navigation, Total Hip Arthroplasty

J Med Assoc Thai 2017; 100 (4): 457-62

Full text. e-Journal: <http://www.jmatonline.com>

In total hip arthroplasty (THA), malposition of the acetabular component has been linked to increase dislocation rate, impingement, pelvic osteolysis, cup migration, and wear of polyethylene⁽¹⁾. The imageless navigation system has been developed to assist operating surgeons in determining acetabular cup orientation intraoperatively. Several researchers⁽²⁻⁸⁾ had demonstrated that imageless navigation offered more precise cup placement compared to the conventional freehand technique. The accuracy of cup placement in imageless navigation depends on the bony landmark registration intraoperatively. One of the limitations in

imageless navigation among surgeons is the variability in bony landmark registration. If the bony landmark registration is different among surgeons, the final cup position determined by the navigation will also be different. Therefore, the intra and intersurgeon variability in bony landmark registration will influence the accuracy of cup position in both abduction and anteversion angles. The authors therefore determine intra and inter-observer reliability of the bony landmark registration in three surgeons with varying experience in imageless navigation THA. The authors hypothesized that the final cup position values should be reproducible among surgeons with varying experiences in using imageless navigation in semilateral decubitus position.

Correspondence to:

Suksathien Y, Department of Orthopedic Surgery, Maharat Nakhon Ratchasima Hospital, Chang Phueak Road, Mueang, Nakhon Ratchasima 30000, Thailand.

Phone: +66-44-235529, Fax: +66-44-259677

E-mail: ysuksathien@yahoo.com

Material and Method

The present study was approved by the Ethics

Committee of Maharat Nakorn Ratchasima Hospital. Between June 2014 and April 2015, patients receiving cementless total hip arthroplasty with imageless navigation were included in the present single-center study. The exclusion criteria were patients who were not suitable for cementless prosthesis (Dorr type C)⁽⁹⁾.

All cases were performed THA by three surgeons with varied experiences in imageless navigation. The first surgeon (S1-YS) is senior staff with experience in imageless navigation, the second surgeon (S2-JS) is junior staff with one year experience in imageless navigation (with more than 50 cases) and the third surgeon (S3-AC) is a fourth-year orthopedic resident with no experience in imageless navigation.

All cases underwent cementless THA (Metha or Excia stems and Plasmakit cup; B. Braun Aesculap, Tuttlingen, Germany) with imageless navigation in semilateral decubitus position with OrthoPilot THA Pro software (Aesculap AG). Two small pins were inserted into the ipsilateral Antero Superior Iliac Spine (ASIS) through a stab incision. The authors modified the technique by inserting another two pins into the medial side of the distal femur instead of using the proximal femoral clamp to measure limb length change (Fig. 1). The navigation trackers were attached to both pin adaptors. In order to define the gold standard for registration in the present study, bony landmarks (ASIS in both sides and pubic symphysis) were determined and digitalized by (S1) with a metal pointer to define anterior pelvic plane (APP) and the native limb length was measured.

All patients were performed with the modified Hardinge's approach. After removal of the femoral head,

the deepest point of the acetabular fossa was registered as an additional reference point. Then, by using the trial cup, the native abduction and anteversion angles of the acetabulum were determined. During reaming, the position of the reamer was acquired by the navigation system and the operating surgeon was provided with real-time information about the resulting position of the reamer (medialization, cranialization and antero-posterior direction) and its orientation (abduction and anteversion) in relation to APP as well as the native acetabulum. After reaching the design reaming position, the final cup was implanted and the operating surgeon was provided with real-time information about the cup position and orientation. Cup orientation was aimed at $40^{\circ} \pm 5^{\circ}$ of abduction and $15^{\circ} \pm 5^{\circ}$ of anteversion in all cases. The final cup position was recorded by the navigation system as Abduction-S1 and Anteversion-S1. After finishing the cup, the operating table was tilted forward until the patient was in the lateral decubitus position then the patient's leg was dropped anteriorly to perform the femoral stem (Fig. 2). After final stem sizing, the operating surgeon was provided with real-time information about the stem position and the amount of the limb length change. After finishing the stem, the stem position and the limb length change were recorded by the navigation system.

Then the navigation system was kicked back to APP registration process again and the (S2) registered the bony landmark and the final cup position was recorded as Abduction-S2.1 and Anteversion-S2.1. The process was repeated and the (S3) registered the bony landmark and the final cup position was recorded as

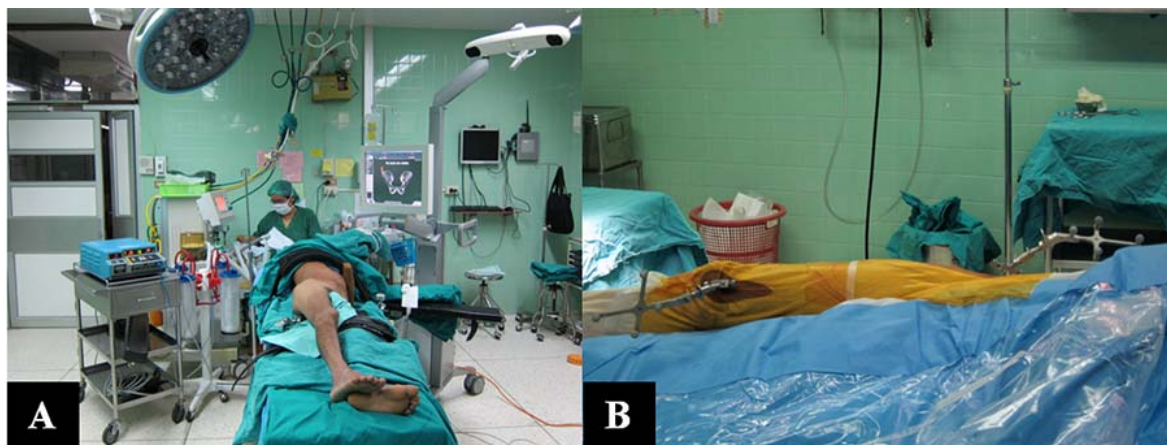


Fig. 1 (A) The patient was performed in semilateral decubitus position. (B) Two pins were inserted into the ipsilateral Antero Superior Iliac Spine (ASIS) and the medial side of the distal femur to measure the limb length change.

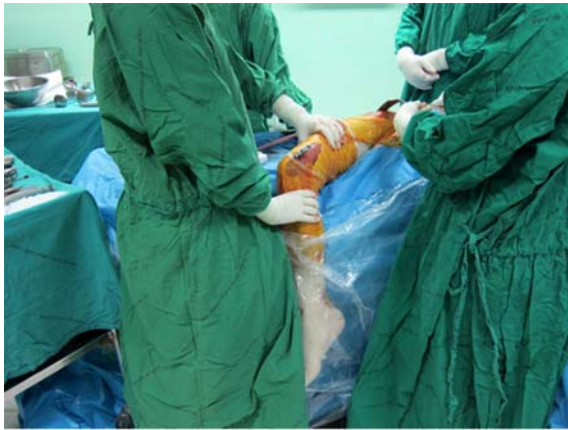

Fig. 2 The patient's leg was dropped anteriorly to perform the femoral stem.

Abduction-S3.1 and Anteversion-S3.1. This process was repeated by both (S2) and (S3) and the final cup positions were recorded as Abduction S2.2, Anteversion S2.2, Abduction S3.2 and Anteversion S3.2 respectively. Patients' age, gender, BMI and diagnosis were recorded as demographic data.

The intra-observer reliability of the abduction angle for (S2) was calculated by comparing Abduction S2.1 to Abduction S2.2 and for (S3) by comparing Abduction 3.1 to Abduction 3.2. The intra-observer reliability of anteversion angle for (S2) was calculated by comparing Anteversion S2.1 to Anteversion S2.2 and for (S3) by comparing Anteversion 3.1 to Anteversion 3.2.

The inter-observer reliability of the abduction angle between (S1) and (S2) was calculated by comparing Abduction S1 to an average of Abduction S2.1 and S2.2 and between (S1) and (S3) by comparing Abduction S1 to an average of Abduction S3.1 and S3.2. The inter-observer reliability of the anteversion angle between (S1) and (S2) was calculated by comparing Anteversion S1 to an average of Anteversion S2.1 and S2.2 and between (S1) and (S3) by comparing Anteversion S1 to an average of Anteversion S3.1 and S3.2.

Statistical analysis

Paired t-test was used to compare the difference in abduction and anteversion angles among three surgeons. A *p*-value less than 0.05 was considered statistically significant. Statistical analysis was performed using STATA, version 12.0 (College Station, TX). Intra and inter-observer reliability were determined with ICC (intraclass correlation coefficients).

Table 1. Demographic data

Characteristic	Total (n = 60)
Gender, n (%)	
Male	39 (65)
Female	21 (35)
Age (years), Mean (range)	50±15.3 (23 to 82)
BMI (kg/m ²), Mean (range, SD)	21.7±3.2 (17.8 to 32.3)
Diagnosis, n (%)	
Osteonecrosis (ONFH)	38 (63.3)
Femoral neck fracture	10 (16.7)
Developmental dysplasia of the hip (DDH)	6 (10)
Primary osteoarthritis	4 (6.7)
Post-traumatic arthritis	2 (3.3)

BMI = body mass index

The sample size was calculated based on 95% CI width at 0.1, three surgeons replicated and expected ICC at 0.88. The calculated sample size were 57 cases, therefore we included 60 cases in the present study.

Results

There were 60 cases in the present study. Thirty-nine cases were men and 21 cases were women. The mean age of the patients was 50 years (23 to 82) with the mean body mass index (BMI) of 21.7 (17.8 to 32.3, SD 3.2). There were 38 cases (63.3%) of osteonecrosis of the femoral head (ONFH), 10 cases (16.7%) of femoral neck fracture, six cases (10%) of developmental dysplasia of the hip (DDH), four cases (6.7%) of primary osteoarthritis, and two cases (3%) of posttraumatic arthritis (Table 1).

The mean abduction angle of (S1) was 40.5 (34 to 54, SD 2.9). The mean abduction angle of (S2) was 40.8 (34 to 54.5, SD 3.6). The mean abduction angle of (S3) was 40.6 (33.5 to 53, SD 3.4). There was no significant difference in cup abduction angle between (S1) and (S2) (*p* = 0.27) and (S1) and (S3) (*p* = 0.79). The mean anteversion angle of the (S1) was 12.6 (9 to 18, SD 2.3). The mean anteversion angle of (S2) was 12 (5.5 to 19.5, SD 3.4). The mean anteversion angle of (S3) was 10.9 (6 to 19.5, SD 2.7). There was no significant difference in cup anteversion angle between (S1) and (S2) (*p* = 0.1) but there was significant difference between (S1) and (S3) (*p* < 0.001) (Table 2).

For the intra-observer reliability, the ICCs of abduction angle was 0.95 for (S2) and 0.86 for (S3) and the ICCs of anteversion angle was 0.91 for (S2) and 0.86 for (S3). For the inter-observer reliability, the ICCs

Table 2. Overview of results

	Abduction mean (range, SD)	<i>p</i> -value	Anteversion mean (range, SD)	<i>p</i> -value
S1	40.5±2.9 (34 to 54)	0.27	12.6±2.3 (9 to 18)	0.1
S2	40.8±3.6 (34 to 54.5)		12±3.4 (5.5 to 19.5)	
S1	40.5±2.9 (34 to 54)	0.79	12.6±2.3 (9 to 18)	<0.001
S3	40.6±3.4 (33.5 to 53)		10.9±2.7 (6 to 19.5)	

S1 = Experienced surgeon; S2 = One year of experience in imageless navigation surgeon; S3 = Non-experienced surgeon

of abduction angle between (S1) and (S2) was 0.89 and between (S1) and (S3) was 0.87, the ICCs of anteversion angle between (S1) and (S2) was 0.8 and between (S1) and (S3) was 0.72 (Table 3).

According to Lewinnek's safe zone⁽¹⁰⁾, the navigation value showed that only one and the same case for each surgeon the abduction angle was an outlier but the anteversion angles were within the safe zone for all surgeons. This case was diagnosed DDH and the BMI was 31.2 kg/m². There was no dislocation in the present study.

Discussion

Several previous studies⁽²⁻⁷⁾ had reported that imageless navigation offered more precise cup placement compared to conventional freehand technique. In addition, in our previous study⁽⁸⁾ about acetabular cup placement comparing between navigated and non-navigated THA, we demonstrated a significant increase in the placement of acetabular cups within the safe zone using imageless navigation. However, the accuracy of cup placement in imageless navigation depends on the bony landmark registration intraoperatively which may be variable among surgeons so we needed to define this variability.

The authors used the final cup orientations of the experienced surgeon as the gold standard for this study because in our previous study⁽¹¹⁾ about the accuracy of registration it showed good reliability, the mean deviation of the navigated value from the CT value was 1.6° (-3.4° to 7.9°) for abduction and 3.2° (-2.6° to 14.9°) for anteversion angles.

In the present study, the authors found no significant difference in cup abduction angle among surgeons. There was only significant difference in cup anteversion angle between (S1) and (S3), which showed that the anteversion angle needed some learning period for (S3) to be as precise as (S1).

In intra-observer reliability analysis, the

Table 3. Intraclass correlation coefficients

	Abduction	Anteversion
Intra-observer		
S2	0.95	0.91
S3	0.86	0.86
Inter-observer		
Between S1-S2	0.89	0.8
Between S1-S3	0.87	0.72

S1 = Experienced surgeon; S2 = One year of experience in imageless navigation surgeon; S3 = Non-experienced surgeon

authors found that the ICCs was acceptable in both abduction and anteversion angles for both (S2) and (S3), which means that these procedures were reproducible by each surgeon. In inter-observer reliability analysis, the authors found that only the ICCs of anteversion angle between (S1) and (S3) was unacceptable (0.72). Both abduction and anteversion angles of (S2) were as precise as (S1), so one year of experience in imageless navigation of (S2) made these registration procedures reproducible as (S1).

Intra and inter-observer reliability of registration in imageless navigation has been reported in previous studies with different registration position. Spencer et al⁽¹²⁾ reported a cadaveric study in lateral position, they found that the intra-observer error was larger variation for anteversion (SD 6.3°) than for abduction (SD 4.3°) and the inter-observer error was larger variation for anteversion (SD 9.6°) than abduction (SD 5.9°). Parrette et al⁽¹³⁾ reported a cadaveric study in supine position, they found acceptable intra-observer repeatability but acceptable inter-observer analysis agreement only in the abduction angle and not in anteversion. Ohashi et al⁽¹⁴⁾ studied in 37 THAs through a direct lateral approach in lateral decubitus position and 15 through modified Smith-

Petersen direct anterior approach in supine position. They reported that in lateral position, the ICCS for intra-observer were 0.65 and 0.81 and the ICCs for inter-observer were 0.59 and 0.72 for abduction and anteversion respectively. In supine position, the ICCS for intra-observer were 0.92 and 0.93 and the ICCs for inter-observer were 0.95 and 0.85 for abduction and anteversion respectively.

Most of the previous studies, consistent with the present study in semilateral decubitus position, showed that the ICCs of anteversion for inter-observer was least reliable, resulting from the thickness of the soft tissue above pubic symphysis. As Lee et al⁽¹⁵⁾ demonstrated that when palpating 10 mm above the pubic symphysis and 0 mm above the ASIS, the anteversion angle would be underestimated at approximately 7°.

In conclusion, the reliability of registration in semilateral decubitus position was acceptable in abduction angle among surgeons with varying experience in imageless navigation. The reliability of registration was not acceptable only in anteversion angle between experienced (S1) and non-experienced surgeons (S3). Despite this result, the navigation values of anteversion angles were within the Lewinnex's safe zone in all cases. For the surgeon with one year of experience in imageless navigation, the result of the registration process was comparable to and reproducible with the experienced surgeon in both abduction and anteversion angles.

What is already known on this topic?

Intra and inter-observer reliability of registration in imageless navigation has been reported in previous studies with supine and lateral registration position. Most of the previous studies showed that the ICCs of anteversion for inter-observer was least reliable, resulting from the thickness of the soft tissue above the pubic symphysis.

What this study adds?

The reliability of registration in semilateral decubitus position was acceptable in abduction angle among surgeons with varying experience in imageless navigation.

The reliability of registration was not acceptable only in anteversion angle between experienced (S1) and non-experienced surgeons (S3).

Acknowledgements

The authors want to thank Dr. Urawit

Piyapromdee MD, for assisting with the statistical analysis.

Potential conflicts of interest

None.

References

1. Kennedy JG, Rogers WB, Soffe KE, Sullivan RJ, Griffen DG, Sheehan LJ. Effect of acetabular component orientation on recurrent dislocation, pelvic osteolysis, polyethylene wear, and component migration. *J Arthroplasty* 1998; 13: 530-4.
2. Parratte S, Argenson JN. Validation and usefulness of a computer-assisted cup-positioning system in total hip arthroplasty. A prospective, randomized, controlled study. *J Bone Joint Surg Am* 2007; 89: 494-9.
3. Hohmann E, Bryant A, Tetsworth K. A comparison between imageless navigated and manual freehand technique acetabular cup placement in total hip arthroplasty. *J Arthroplasty* 2011; 26: 1078-82.
4. Najarian BC, Kilgore JE, Markel DC. Evaluation of component positioning in primary total hip arthroplasty using an imageless navigation device compared with traditional methods. *J Arthroplasty* 2009; 24: 15-21.
5. Gandhi R, Marchie A, Farrokhyar F, Mahomed N. Computer navigation in total hip replacement: a meta-analysis. *Int Orthop* 2009; 33: 593-7.
6. Moskal JT, Capps SG. Acetabular component positioning in total hip arthroplasty: an evidence-based analysis. *J Arthroplasty* 2011; 26: 1432-7.
7. Xu K, Li YM, Zhang HF, Wang CG, Xu YQ, Li ZJ. Computer navigation in total hip arthroplasty: a meta-analysis of randomized controlled trials. *Int J Surg* 2014; 12: 528-33.
8. Suksathien Y, Suksathien R, Chaiwirattana P. Acetabular cup placement in navigated and non-navigated total hip arthroplasty (THA): results of two consecutive series using a cementless short stem. *J Med Assoc Thai* 2014; 97: 629-34.
9. Dorr LD, Faugere MC, Mackel AM, Gruen TA, Bognar B, Malluche HH. Structural and cellular assessment of bone quality of proximal femur. *Bone* 1993; 14: 231-42.
10. Lewinnek GE, Lewis JL, Tarr R, Compere CL, Zimmerman JR. Dislocations after total hip-replacement arthroplasties. *J Bone Joint Surg Am* 1978; 60: 217-20.
11. Suksathien Y, Suksathien R, Chaiwirattana P.

- Accuracy of acetabular cup placement in navigated THA with modified registration technique in semilateral decubitus position. J Med Assoc Thai 2014; 97: 1089-95.
12. Spencer JM, Day RE, Sloan KE, Beaver RJ. Computer navigation of the acetabular component: a cadaver reliability study. J Bone Joint Surg Br 2006; 88: 972-5.
 13. Parratte S, Kilian P, Pauly V, Champsaur P, Argenson JN. The use of ultrasound in acquisition of the anterior pelvic plane in computer-assisted total hip replacement: a cadaver study. J Bone Joint Surg Br 2008; 90: 258-63.
 14. Ohashi H, Matsuura M, Okamoto Y, Okajima Y. Intra- and intersurgeon variability in image-free navigation system for THA. Clin Orthop Relat Res 2009; 467: 2305-9.
 15. Lee YS, Yoon TR. Error in acetabular socket alignment due to the thick anterior pelvic soft tissues. J Arthroplasty 2008; 23: 699-706.

ความน่าเชื่อถือของการกำหนดจุดอ้างอิงในการผ่าตัดเปลี่ยนข้อสะโพกเทียมโดยใช้คอมพิวเตอร์นำร่องช่วยผ่าตัดในท่ากึ่งนอนตะแคง

ยิ่งยง สุขเสถียร, จิรายุทธ เสือจ้อย, อติสร จงหมื่นไวย

ภูมิหลัง: ความแตกต่างของการกำหนดจุดอ้างอิงในการผ่าตัดเปลี่ยนข้อสะโพกเทียมโดยใช้คอมพิวเตอร์นำร่อง ทำให้ค่ามุมของเบ้าสะโพกเทียมมีค่าที่แตกต่างกัน

วัตถุประสงค์: ศึกษาความน่าเชื่อถือของผู้ประเมินและระหว่างผู้ประเมินที่มีประสบการณ์แตกต่างกัน 3 คนในการกำหนดจุดอ้างอิง

วัสดุและวิธีการ: ศึกษาในผู้ป่วย 60 ราย แต่ละรายกำหนดจุดอ้างอิงโดยผู้ประเมิน 3 คน ใช้ค่าการกำหนดจุดอ้างอิงของผู้ประเมินที่มีประสบการณ์มากเป็นค่ามาตรฐาน

ผลการศึกษา: ค่ามุม anteversion มีความแตกต่างอย่างมีนัยสำคัญระหว่างผู้ประเมินที่มีประสบการณ์มากและไม่มีประสบการณ์ พบว่ามีความเชื่อถือค่าระหว่างผู้ประเมินที่มีประสบการณ์มากและไม่มีประสบการณ์ ไม่พบความแตกต่างระหว่างผู้ประเมินที่มีประสบการณ์มากและมีประสบการณ์ 1 ปี

สรุป: ความน่าเชื่อถือของการกำหนดจุดอ้างอิงมีความน่าเชื่อถือมากกว่าระหว่างผู้ประเมินที่มีประสบการณ์มากและมีประสบการณ์ 1 ปี ทั้งค่ามุม abduction และ anteversion