

Case Report

Childhood Follicular Mucinosis Co-Existed with Alopecia Universalis

Sirinee Wipavakul MD*,
Suthep Jirasuthat MD**, Chinmanat Tangjaturonrusamee MD*

* Institute of Dermatology, Department of Medical Services, Ministry of Public Health, Bangkok, Thailand

** Division of Dermatology, Department of Medicine, Faculty of Medicine, Ramathibodi Hospital,
Mahidol University Bangkok, Thailand

We report a case of a 6-year-old girl presented with diffuse scalp and body hair loss and developed multiple groups of follicular papules on the trunk. She was diagnosed as follicular mucinosis co-existed with alopecia universalis. Histopathological study supported the diagnosis and did not find malignancy cells.

Keywords: Follicular mucinosis, Alopecia mucinosa, Alopecia universalis

J Med Assoc Thai 2015; 98 (4): 431-4

Full text. e-Journal: <http://www.jmatonline.com>

Case Report

A 6-year-old girl presented with 3-year history of hair loss. It first started with patchy alopecia, and slowly progressed to diffuse alopecia within six months. She also lost the eyebrows, eyelashes, and body hair for three months, and simultaneously developed multiple groups of papules on the trunk. She had been treated with 10 mg/day of oral prednisolone for five months but did not respond, and then was given topical minoxidil for two months without improvement. She denied medical conditions and her family history of alopecia. Physical examination showed diffuse non-scarring alopecia on the scalp, eyebrows, eyelashes, and body hair as well as multiple groups of skin-colored follicular papules on erythematous patches on the back, chest, and abdomen (Fig. 1). Multiple superficial regular pits on the fingernails and toenails were observed.

Scalp biopsy showed moderate infiltration with lymphocytes surrounding the hair bulbs (Fig. 2). Skin biopsy from the trunk showed lymphocytic infiltration on the infundibulum of the hair shaft with clear intercellular spaces where alcian blue pH 2.5 staining was positive for mucin (Fig 3, 4). There was no epidermotropism or atypical cells. The majority of lymphocytes showed a strong staining reaction in response to T-cell markers, whereas the minority showed a moderate staining of B-cell markers, and

did not lose pan T-cell markers. Serum antinuclear antibody, TSH and ferritin level were normal. The final diagnosis was alopecia universalis coexisted with follicular mucinosis.

Topical triamcinolone acetonide 0.02% cream cleared the lesions on the trunk and extremities. Short contact anthralin, topical minoxidil, and topical betamethasone valerate 0.1% cream failed to initiate hair regrowth after 6-month therapy.

Discussion

Alopecia mucinosa or follicular mucinosis was first described in 1957 by Pinkus⁽¹⁾. It is characterized by follicular papules, plaques, nodules, folliculitis, and acneiform alopecia⁽²⁾. There is speculation that lymphokines stimulated by T-helper

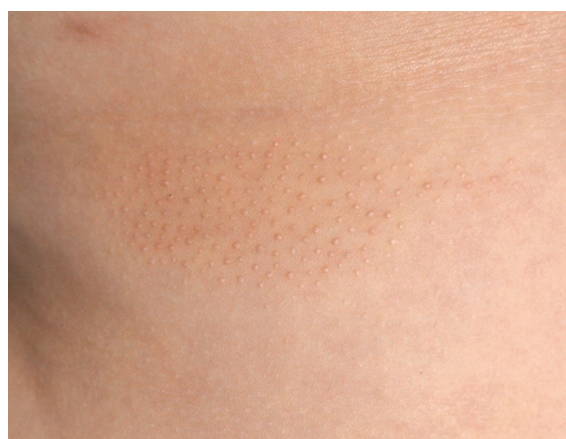

Fig. 1 Groups of multiple skin color follicular papules on trunk.

Correspondence to:

Tangjaturonrusamee C, Institute of Dermatology, 420/7 Rajvithi Road, Phayathai District, Rajthevee, Bangkok 10400, Thailand.
Phone: +66-2-3548037-40, Fax: +66-2-3548042, +66-2-3548046
E-mail: chinmanat@gmail.com

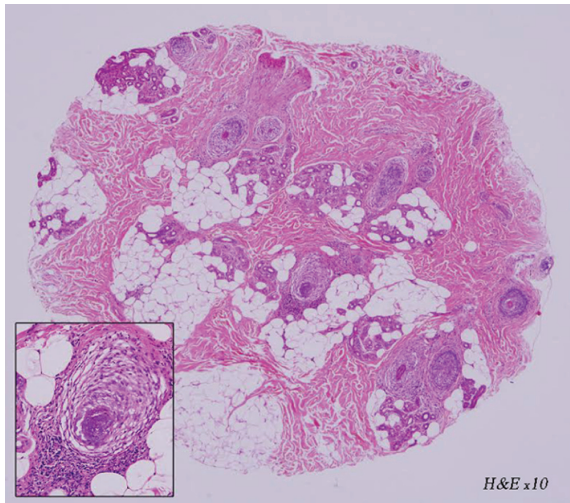


Fig. 2 Horizontal section of scalp biopsy specimen showing moderately dense lymphocytic infiltration at follicular bulb (H&E x10).

lymphocytes may induce mucin secretion, thereby increasing keratinocyte proliferation of the hair follicles⁽³⁾.

This condition was classified in two types, the primary and secondary type. The primary type is idiopathic and classified into acute and chronic form. The acute form is distinguished from the chronic form because it is mostly localized on the head and neck and usually affects young patients. The chronic form has more widespread lesions, usually affects elderly with more persistent course^(4,5). The secondary type is associated with lymphoproliferative disorders especially cutaneous lymphoma and other malignant conditions such as kaposi's sarcoma as well as many benign conditions including two cases of alopecia areata^(4,5). The incidence of cutaneous lymphoma in follicular mucinosis is between 9% and 67%^(4,6). There has been postulated that follicular mucinosis can develop self-limited clones of lymphocytes⁽⁴⁾. Brown et al reported five in seven patients with primary follicular mucinosis who demonstrated positive for clonal T-cell receptor gene rearrangement did not progress to cutaneous lymphoma after at least five year follow-up⁽⁷⁾. There is no specific parameter that helps distinguish between the primary and secondary type including T-cell markers and T-cell receptor gene rearrangement^(6,8,9). The patient was diagnosed as primary follicular mucinosis due to young age and the histopathological findings with an absence of any inflammatory diseases or neoplasms in the lesion. She also was diagnosed as alopecia

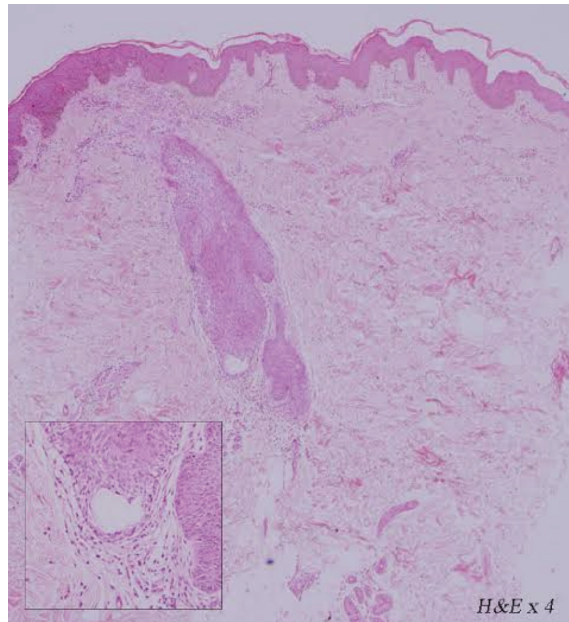


Fig. 3 Vertical section of the skin biopsy of the trunk. Hair shaft showed reticular degeneration and formation of cystic space admixed with some lymphocytes exocytosis (H&E x4).

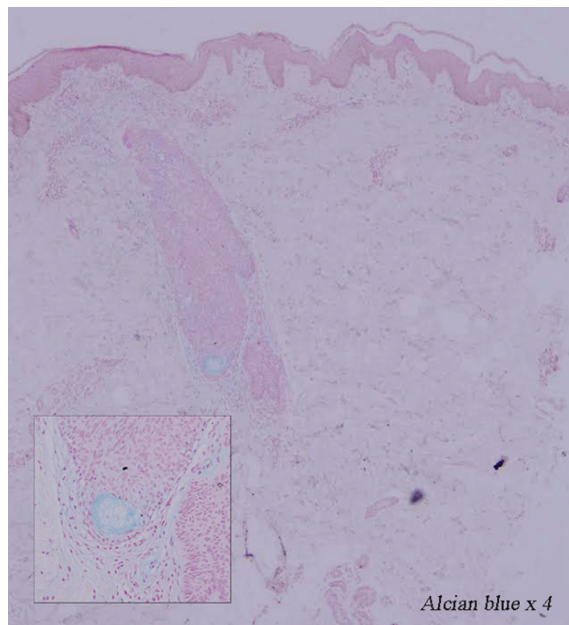


Fig. 4 Alcian blue pH 2.5 staining from the skin biopsy of the trunk was positive for mucin (Alcian blue x4).

universalis regarding to "swarm of bees" around hair bulbs on the scalp biopsy. The differential diagnosis

included atrichia with papular lesions, which was characterized by hair loss soon after birth and developing of diffuse papular rash during childhood. Additionally, the histopathological assessment did not show the mature hair follicles with cysts filled with cornified material, differently from atrichia with papular lesions⁽¹⁰⁾.

There were two case reports of follicular mucinosis associated with alopecia areata. Fanti et al reported the first case of follicular mucinosis with alopecia areata in an 18-year-old woman who presented with 30% of patchy hair loss of the scalp with exclamation mark hairs and histopathology showed lymphocytes infiltration at the upper and bulbar part of the hairs. Mucin deposition was confirmed by alcian blue staining in some hair follicles. The alopecia was completely remission after treatment with squaric acid dibutylester, nevertheless, during three year follow-up, there were two mild relapse courses⁽¹¹⁾. Missal et al⁽¹²⁾ reported the second case of follicular mucinosis with alopecia areata in a 56-year-old woman who presented with multiple areas of hair loss, which progressed to total hair loss in two months. Scalp biopsy showed peribulbar, isthmus and infundibular part of hairs were surrounded and infiltrated by lymphocytes. Some hairs showed mucin deposition. Alopecia areata with secondary follicular mucinosis was diagnosed and the patient was successfully treated with prednisolone⁽¹²⁾.

To our knowledge, the present report is the first case report of follicular mucinosis coexisted with alopecia universalis which developed on the separated area. The exact mechanism of how both disorders present in the same patient is still unknown. The first possibility is the co-incidence of these two unrelated diseases. The second possibility is that these two diseases share the same pathogenesis; while lymphocytes can induce follicular keratinocyte apoptosis in alopecia areata, it also induces mucin production in follicular mucinosis. There are many therapies reported for treatment of primary follicular mucinosis with variable results such as topical, intralesional and systemic steroid, topical and systemic antibiotic, 5% imiquimod cream, isotretinoin, dapson, minocycline, hydroxychloroquine, immunosuppressive drug, indomethacin, interferon, PUVA, photodynamic therapy and excision^(4,8,13-17). Follicular mucinosis on the trunk in our patient responded to topical steroid within two months. It may result either from the anti-inflammatory effect of topical steroid by reducing T-cell proliferation and inducing T-cell apoptosis or from the disease itself that usually has remission in

two years. There is still no data about difference between treatment and prognosis of primary follicular mucinosis alone and primary follicular mucinosis co-existed with alopecia universalis. Further reports are needed, long-term follow-up in this patient is necessary.

Conclusion

The authors presented a case report of primary follicular mucinosis on the trunk coexisted with alopecia universalis. She was successfully treated with topical triamcinolone acetonide 0.02% cream for follicular mucinosis, but failed many treatments for alopecia universalis. Although the symptoms of follicular mucinosis subsided in two years, the long-term follow-up is needed.

What is already known on this topic?

Follicular mucinosis is an uncommon inflammatory disorder. There are two case reports of follicular mucinosis with alopecia areata occurring on the same area. It is possible that the primary follicular mucinosis can develop together with alopecia universalis on the different areas in a single patient.

What this study adds?

The primary acute form of follicular mucinosis is usually found on the head and neck of young patients and it subsides within two years. This patient has been given a diagnosis of primary follicular mucinosis by the following features 1) young age at onset, 2) an absent of any inflammatory or malignant diseases from the histological section. To date, there are still no specific markers that can distinguish primary follicular mucinosis from secondary cutaneous lymphoma, especially folliculotropic mycosis fungoides. Long-term patient monitoring is essential.

Potential conflicts of interest

None.

References

1. Pinkus H. Alopecia mucinosa; inflammatory plaques with alopecia characterized by root-sheath mucinosis. *AMA Arch Derm* 1957; 76: 419-24.
2. Wittenberg GP, Gibson LE, Pittelkow MR, el Azhary RA. Follicular mucinosis presenting as an acneiform eruption: report of four cases. *J Am Acad Dermatol* 1998; 38: 849-51.
3. Reed RJ. The T-lymphocyte, the mucinous epithelial interstitium, and immunostimulation.

- Am J Dermatopathol 1981; 3: 207-14.
4. Arca E, Kose O, Tastan HB, Gur AR, Safali M. Follicular mucinosis responding to isotretinoin treatment. J Dermatolog Treat 2004; 15: 391-5.
 5. Zvulunov A, Shkalim V, Ben Amitai D, Feinmesser M. Clinical and histopathologic spectrum of alopecia mucinosa/follicular mucinosis and its natural history in children. J Am Acad Dermatol 2012; 67: 1174-81.
 6. Kontochristopoulos GJ, Exadaktylou D, Hatzilou E, Tassidou A, Zakopoulou N. Follicular mucinosis associated with early stage cutaneous T-cell lymphoma: successful treatment with interferon alpha-2b and acitretin. J Dermatolog Treat 2001; 12: 117-21.
 7. Brown HA, Gibson LE, Pujol RM, Lust JA, Pittelkow MR. Primary follicular mucinosis: long-term follow-up of patients younger than 40 years with and without clonal T-cell receptor gene rearrangement. J Am Acad Dermatol 2002; 47: 856-62.
 8. Parker SR, Murad E. Follicular mucinosis: clinical, histologic, and molecular remission with minocycline. J Am Acad Dermatol 2010; 62: 139-41.
 9. Cerroni L, Fink-Puches R, Back B, Kerl H. Follicular mucinosis: a critical reappraisal of clinicopathologic features and association with mycosis fungoides and Sezary syndrome. Arch Dermatol 2002; 138: 182-9.
 10. Bansal M, Manchanda K, Lamba S, Pandey S. Atrichia with papular lesions. Int J Trichology 2011; 3: 112-4.
 11. Fanti PA, Tosti A, Morelli R, Cameli N, Sabattini E, Pileri S. Follicular mucinosis in alopecia areata. Am J Dermatopathol 1992; 14: 542-5.
 12. Missall TA, Hurley MY, Burkemper NM. Prominent follicular mucinosis with diffuse scalp alopecia resembling alopecia areata. J Cutan Pathol 2013; 40: 887-90.
 13. Rupnik H, Podrumac B, Zgavec B, Lunder T. Follicular mucinosis in a teenage girl. Acta Dermatovenerol Alp Pannonica Adriat 2005; 14: 111-4.
 14. Guerriero C, De Simone C, Guidi B, Rotoli M, Venier A. Follicular mucinosis successfully treated with isotretinoin. Eur J Dermatol 1999; 9: 22-4.
 15. Alonso de Celada RM, Feito RM, Noguera ML, Beato Merino MJ, De Lucas LR. Treatment of primary follicular mucinosis with imiquimod 5% cream. Pediatr Dermatol 2014; 31: 406-8.
 16. Schneider SW, Metz D, Bonsmann G. Treatment of so-called idiopathic follicular mucinosis with hydroxychloroquine. Br J Dermatol 2010; 163: 420-3.
 17. Emmerson RW. Follicular mucinosis. A study of 47 patients. Br J Dermatol 1969; 81: 395-413.

การพบโรค *follicular mucinosis* ร่วมกับ *alopecia universalis* ในผู้ป่วยรายเดียวกัน: รายงานผู้ป่วย 1 ราย

ศิริณี วิภากุล, สุเทพ จิระสุทัศน์, ชินมนัส ตั้งจาทูรนต์รัศมี

รายงานผู้ป่วยเด็กหญิงหนึ่งราย อายุ 6 ปี มารับการตรวจรักษาด้วยอาการผมร่วงทั่วศีรษะและขนตามตัวร่วงหมด พร้อมกับเกิดคุ่มตรงงูขึ้นที่อกเป็นกลุ่มบริเวณลำตัว ได้รับวินิจฉัยว่าเป็น *follicular mucinosis* ที่พบร่วมกับ *alopecia universalis* ผลการตรวจชิ้นเนื้อทางพยาธิวิทยาสันับสนุนการวินิจฉัยโรคดังกล่าว และตรวจไม่พบเซลล์มะเร็ง