

Focal Fibrosis of the Breast Diagnosed by Core Needle Biopsy under Imaging Guidance

Cholatip Wiratkapun MD*, Orapin Chansanti MD*,
Bussanee Wibulpolprasert MD*, Panuwat Lertsittichai MD, MSc**

* Department of Radiology, Faculty of Medicine, Ramathibodi Hospital, Mahidol University, Bangkok, Thailand

** Department of Surgery, Faculty of Medicine, Ramathibodi Hospital, Mahidol University, Bangkok, Thailand

Background: Focal fibrosis of the breast is an uncommon pathology, recognition of this lesion is important because it could mimic malignant lesions on both mammogram and ultrasonography (US). Concordance with the pathology result from core needle biopsy (CNB) and follow-up are essential to avoid false negative

Objective: To characterize the mammographic and US features of focal fibrosis of the breast and to estimate the false negative rate for breast cancer when focal fibrosis was diagnosed by CNB.

Material and Method: The subjects were 82 patients diagnosed fibrosis of the breast by CNB during 7-year period.

Results: Of 38 mammographic visible lesions there were mass lesions in 12 (32%), calcifications in 14 (37%), mass with calcifications in four (11%), architectural distortion in one (3%) and asymmetrical density in seven (18%). Most of the lesions seen on the US were hypoechoic mass (81%). The suspicious features, which warrant CNB, included irregular shape in 37 (55%), indistinct margin in 38 (57%), and posterior shadowing in 28 (42%). Most of the lesions were categorized as Breast Imaging Reporting and Data System (BI-RADS) 4A (59%). Thirteen cases underwent surgical biopsy and all showed benign pathologic results. No false-negative cases were detected.

Conclusion: Focal fibrosis had some features similar to malignant lesion. CNB showed reliable pathological result. No false negative result was found in the present study.

Keywords: Breast, Focal fibrosis, Core needle biopsy, Mammogram, Ultrasound

J Med Assoc Thai 2013; 96 (3): 340-5

Full text. e-Journal: <http://jmat.mat.or.th>

Focal fibrosis of the breast has become increasingly common in the era of screening mammography. It may present as a palpable mass or may present as a clinically occult, imaging detected abnormality⁽¹⁾. The incidence was reported to be 2.1% to 8.9% of lesions found in patients who underwent imaging-guided core biopsy⁽¹⁻⁵⁾.

Breast fibrosis was believed in the past to be associated with scar and diabetic mastopathy. It is now clear that focal fibrosis of the breast is a benign pathologic entity in itself⁽⁶⁾. The histopathology of focal fibrosis is characterized by proliferation of the stromal connective tissue with obliteration of the mammary ducts and lobules^(1,3-5). The result is a localized area of fibrous tissue associated with hypoplastic mammary ducts and lobules^(1,3). It has been described by a

variety of names, including stromal fibrosis, focal fibrosis of the breast, fibrous tumor of the breast, fibrous mastopathy, and focal fibrous disease of the breast^(1,3).

Focal fibrosis of the breast has many mammographic and ultrasonographic (US) manifestations. It may present as a well-defined benign looking mass to lesions that can simulate malignancy^(1,3).

Core needle biopsy (CNB) under imaging guidance has been widely used. It is an accepted method for pathological diagnosis. Comparison to surgical biopsy, CNB is less invasive, decreases patient's physical and psychological stress, decreases operative and perioperative risk and causes minimal postoperative scarring^(7,8). This method has been reported to have high accuracy and reliability.

A small percentage of cases diagnosed as benign via CNB will change on follow-up mammography. Follow-up clinical and mammographic exams are necessary to determine the stability of the lesion in which CNB yields benign histological finding and to exclude hidden malignancy⁽⁹⁾.

Correspondence to:

Wiratkapun C, Department of Radiology, Faculty of Medicine, Ramathibodi Hospital, Mahidol University, Rama 6 Road, Rajithewee, Bangkok 10400, Thailand.

Phone: 0-2201-1260, Fax: 0-2201-1297

E-mail: cholatipp@gmail.com, racwr@mahidol.ac.th

The present study was conducted to characterize the imaging features of focal fibrosis and to estimate the false negative rate for malignancy of CNB in this pathological entity.

Material and Method

Research ethics committee approval was obtained for this retrospective study, and informed consent was waived.

The patient data from the medical records, mammography, US images, and the pathology reports were retrospectively reviewed.

The present study population was the patients diagnosed with fibrosis from CNB who had subsequent surgical biopsy or had clinical or imaging followed-up at least 12 months. There were 82 eligible patients from 2,696 patients that underwent CNB at the study period (3%).

Breast lesions were detected by the mammography, US, or both. US-guided or stereotactic CNB was performed for suspicious lesions (Breast Imaging Reporting and Data System; BI-RADS category 4), as well as those highly suggestive of malignancy (BI-RADS category 5). Probably benign lesions (BI-RADS category 3) and benign lesions (BI-RADS category 2) underwent US-guided CNB only in cases where the patient or referring physician strongly requested the biopsy.

Mammography was performed in craniocaudal (CC) and mediolateral oblique (MLO) views using two mammographic machines (Lorads M-IV; Danbury, CT, USA and Senographe DMR; GE, Milwaukee, WI, USA). After September 2004, mammography was done using digital mammography (Selenia; Danbury, CT, USA). Lesions seen were characterized using the BI-RADS lexicon.

US was performed for all lesions. Lesions seen were also characterized using the relevant BI-RADS criteria. US was performed using machines HDI 5000 (Phillips ultrasound, Bothell, WA, USA), and after January 2008, iU22 (Phillips ultrasound, Bothell, WA, USA) was used.

Stereotactic guided biopsy was performed using 11-gauge directional vacuum assisted core needle biopsy (VAB) instrument (Mammotome; Biopsy Ethicon Endo-Surgery, Cincinnati, OH, USA) on a prone breast biopsy table (LORAD MultiCare Platinum, Danbury, CT, USA). Before February 2005, vacuum-assisted stereotactic CNB was performed using an add-on stereotactic device with digital imaging (Lorad stereoLoc II, Danbury, CT, USA).

Twelve core specimens were routinely retrieved with this technique.

US-guided biopsy was performed using a 12-5 MHz linear array transducer and 13-gauge co-axial introducer needle and a 14-gauge cutting needle (MDTECH; Gainesville, FL, USA) with a long-throw (22-mm). All needles biopsies were performed using an automated biopsy gun (Magnum; Bard Peripheral Technologies, Covington, GA, USA) with freehand technique. Usually, four to six core specimens were retrieved.

All biopsies were performed by three radiologists specializing in breast imaging.

All CNB specimens were examined by experienced pathologists. Focal fibrosis was defined as the proliferation of stroma with obliteration of the mammary acini and ducts, resulting in a localized area of fibrous tissue associated with hypoplastic mammary ducts and lobules.

The relative frequency of each type of lesion seen on imaging and lesion characteristics were recorded, as well as the lesion size, mode of detection, and the clinical presentation of the patient. Size of the lesion was defined as its maximum diameter.

Mammographic findings of a lesion were characterized as a mass, architectural distortion or asymmetrical density. The mass lesion was classified as circumscribed, lobulated, microlobulated or obscured. Lesions visualized on US were classified as mass, mass with calcifications or asymmetrical echogenicity. The mass lesion was further characterized by its shape, margin, posterior transmission, and echogenicity.

Outcomes were determined by pathology findings from surgical excision, as well as clinical or imaging findings for at least 12 months.

Continuous variables (age, size of lesion, and number of core specimen) were summarized as mean (SD) or median (range) as appropriate. Categorical variables (personal and family history of breast cancer, breast density, mammographic and US findings, BI-RADS category and status at last follow-up) were summarized as counts and percentages. All statistical analyses were performed using Stata V.9 (Stata Corp., College Drive, TX, USA) statistical software.

Results

Histopathologically confirmed focal fibrosis of the breast was diagnosed in 82 lesions in 82 patients (15 stereotactic-guided and 67 US-guided CNB). The mean age of the patients was 51.2 years (SD=9.4 years). Eight patients (10%) had a family history of breast

cancer and 12 patients (15%) had a previous history of breast cancer. However, all new lesions were remote from previous surgical scars. The lesions were found in the left breast more than the right breast (46 versus 36). Most lesions were located at the upper-outer quadrant of each breast (68%).

Thirty-eight patients had abnormal mammographic findings. They included mass lesions in 12 patients (32%), calcifications in 14 (37%), mass with calcifications in four (11%), architectural distortion in one (3%), and asymmetrical density in seven (18%). The margins of masses with or without calcification (n = 16) were circumscribed in seven, microlobulated in one, obscured in five, indistinct in two, and spiculated in one.

Of the 68 lesions detected by US, most manifested as mass (61 lesions, 90%). The mean size was 1.2 cm. (ranged from 0.3-3 cm). All asymmetric densities seen on mammogram were shown to be solid masses on the US. Other US findings were mass with calcifications in six lesions and asymmetrical echogenicity in one lesion. The shape of the masses were round in 20 (30%), ovoid in 10 (15%), and irregular in 37 (55%). The margin were well-circumscribed in 23 (34%), microlobulated in three (5%), indistinct in 38 (57%), spiculated in one (1%), and angular in two (3%). Most of the lesions showed hypoechoogenicity (54/67, 81%). The remaining were isoechoic (1/67, 1%) and mixed echoic (12/67, 18%). Twenty cases had posterior shadowing (42%).

Most of the lesions were classified as BI-RADS 4 (68/82, 83%). Forty-eight were classified as BI-RADS 4A. Two cases were categorized as BI-RADS 4C, one patient was undergone excisional biopsy, disclosing fibrocystic disease. The other was followed for four years without lesion progression. None of the lesions was classified as BI-RADS 5.

Of the 82 lesions, 13 were excised. All were of benign pathology. The pathologic results were fibrocystic changes in five lesions, stromal fibrosis and fibromatosis in three, fibrosis with microcalcification in two, fibrosis with fibroadenosis in two, and xanthohistiocytic inflammation in one. Fifty-four percent of the surgical specimen also reported fibrosis. Imaging features of excised lesions were summarized in Table 1.

Seventy-four lesions were followed by clinical or US and mammographic examination or both. The mean follow-up time was 35 months (SD = 23 months). Of these, 47 lesions were followed for more than two years or underwent excisional biopsy. None of these lesions showed malignancy. Follow-up US was performed on 63 lesions. Only one lesion was re-classified as BI-RADS 4A due to the development of a cluster of microcalcifications within the preexisting mass. This lesion was excised and showed a benign pathology (fibrosis with microcalcification) (Table 2). Nineteen patients did not undergo follow-up imaging.

Examples of mammographic and US findings are shown in Fig. 1, 2, and 3.

Table 1. Ultrasound features and BI-RADS assessment of the excisional biopsy lesions

Patient	Palpable	Shape		Margin		Hypoechoic	Shadowing	BI-RADS
		Oval/round	Irregular	Circumscribed	Ill-defined			
1	+		+		+	+	+	4A
2			+	+				4A
3	+		+		+	+	+	4C
4	+	+			+			4B
5			+		+		+	4A
6	+	+			+	+		4A
7		+		+		+		4A
8	+		+		+		+	4A
9			+		+			4A
10			+		+	+	+	4B
11			+		+	+		4B
12	+	+		+			+	4A

* One lesion showed only calcifications on mammogram without mass, hence; it was not shown on this table.
BI-RADS = breast imaging reporting and data system

Table 2. BI-RADS category before CNB and after, at last follow-up imaging (n = 63)

After/before CNB	BI-RADS 2	BI-RADS 3	BI-RADS 4A	BI-RADS 4B	BI-RADS 4C
BI-RADS 1	0	1 (9%)	3 (8%)	0	0
BI-RADS 2	1 (100%)	10 (91%)	28 (78%)	12 (92%)	2 (100%)
BI-RADS 3	0	0	4 (11%)	1 (8%)	0
BI-RADS 4A	0	0	1 (3%)	0	0
Total	1 (100%)	11 (100%)	36 (100%)	13 (100%)	2 (100%)

BI-RADS = breast imaging reporting and data system; CNB = core needle biopsy

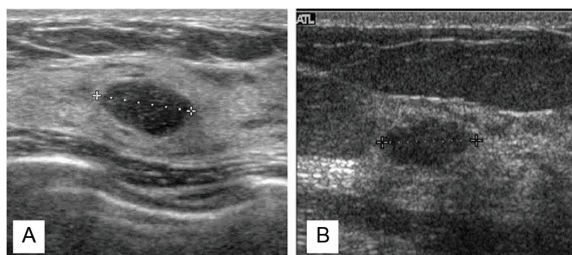


Fig. 1 Focal fibrosis in two patients with unremarkable finding in their mammographies. (A) A 48-year-old woman with ultrasonography revealed a circumscribed oval-shaped hypoechoic nodule size 1.1 cm. (B) A 47-year-old woman with an oval-shaped, hypoechoic nodule with microlobulated margin size 1.2 cm. Both lesions were classified as BI-RADS 3. Core needle biopsy revealed focal fibrosis which were stable (lesion A) and regressed in size (lesion B) on the follow-up ultrasonographies in the next 19 and 24 months, respectively.

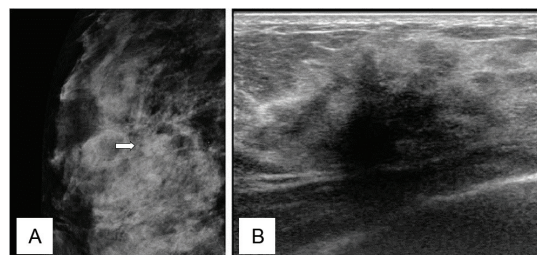


Fig. 3 A 25-year-old woman presented with a palpable right breast mass. (A) Right mammography on mediolateral oblique (MLO) view revealed a focal asymmetrical density at the upper-inner quadrant (arrow). (B) The corresponding ultrasonography revealed a markedly hypoechoic mass with ill-defined border and posterior acoustic shadowing, which concerned for malignant lesion. This mass was categorized as BI-RADS 4C. Focal fibrosis was found from the core needle biopsy. Subsequent excisional biopsy revealed a fibrocystic change.

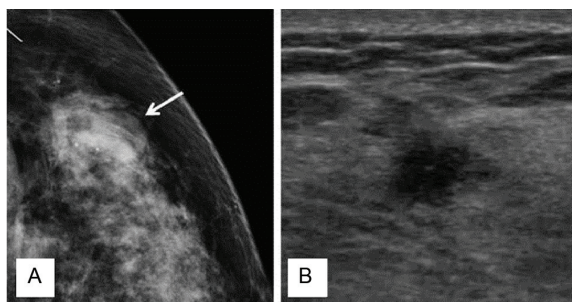


Fig. 2 Focal fibrosis in a 47-year-old woman presented with a palpable breast mass. (A) Left mammography on craniocaudal (CC) view revealed a circumscribed mass at the upper-inner quadrant (arrow). (B) Ultrasonography revealed an irregular hypoechoic nodule with angular margin size 0.7 cm. It was categorized as BI-RADS 4B. The lesion was stable on the follow-up ultrasonography at 6 month.

Discussion

Focal fibrosis is an uncommon benign breast lesion. The cause of this lesion is still uncertain.

Many hypotheses have been suggested, including the result of hormonal stimulation, or a variation of normal breast involution, or the end result of an inflammatory process⁽³⁾.

Various mammographic and US findings associated with focal fibrosis have been described^(1,4-7). These findings range from a well-circumscribed benign appearance to malignant irregular or spiculated mass mimicking malignancy. Previous studies have shown that focal fibrosis commonly present as a mass with or without calcification (>50%) or asymmetrical density (from 10-40%)^(1,3,4,6). Most mammographic findings in the present series also showed mass lesions with or without calcification. In one patient, her lesion manifested as a spiculated mass and was classified as BI-RADS 4B. Less frequent focal asymmetrical density lesions in the present study (18%) were shown as a mass on US and regarded as suspicious abnormality (BI-RADS 4A in 4 cases and BI-RADS 4B in 3 cases).

You et al⁽⁵⁾ evaluated 62 cases of non-palpable focal fibrosis and most were categorized as

BI-RADS 3 (48.2%) or 4 (51.8%), whereas 83% of the lesions in the present study were classified as BI-RADS 4. They also reported that 14.3% had irregular margin, 16.1% was of indistinct margin, 21.4% was hypoechoic and only 14.3% showed posterior shadowing. In contrast, the present study revealed greater frequency of these suspicious sonographic features (irregular shape in 55%, indistinct margin in 57%, hypoechoic in 81%, and posterior shadowing in 42%). The larger size of the lesions in the present study (mean 1.2 cm versus 0.9 cm) might have allowed better depiction of posterior features of the masses. The authors also enrolled both palpable and non-palpable lesion, which should influence the BI-RADS assessment.

No false negative detection for malignancy was seen in the present study, similar to several previous studies^(2,4,5). This suggested that focal fibrosis of the breast could be safely followed after diagnosis using CNB. To our knowledge, only one study⁽¹⁾ reported false negative findings in two of 74 biopsied-lesions (2.7%) and a delayed diagnosis of six months in one case. Because of none or low incidence of missed cancer, a 6-month follow-up is appropriate when there is radiologic-pathologic concordance^(1,5). On the other hand, if the radiographic finding is highly suspicious, prompt excisional biopsy or re-biopsy should be considered.

Thirteen of 82 lesions in this present study had surgical excision. Histopathologic diagnosis was changed in six lesions. These included fibrocystic changes (5 cases) and xanthohistiocytic inflammation (1 case). The opportunity of the pathologists to examine the whole lesion might have explained this finding. The remaining seven cases had fibrosis with other component. Sampling error or inadequate sampling might occur because these lesions only partially contain internal fibrosis. However, due to the benign nature of the pathology, imaging-guided CNB is still preferred.

Limitation in the present study included 19 of 82 lesions with no imaging follow-up and four of these were classified as BI-RADS 4B. This might have led to an underestimation of missed cancers. At least six month follow-up protocol should have been performed to confirm stability of the lesions.

Conclusion

Our data revealed that focal fibrosis of the breast was an uncommon benign breast pathology. These lesions are important because most fibrosis had

similar mammographic and US features as malignant lesions. CNB allow reliable pathological diagnosis, as no false negative findings occurred. However, radiologic-pathologic concordance was essential to ascertain the benignity of the lesion.

Potential conflicts of interest

None.

References

1. Sklair-Levy M, Samuels TH, Catzavelos C, Hamilton P, Shumak R. Stromal fibrosis of the breast. *AJR Am J Roentgenol* 2001; 177: 573-7.
2. Harvey SC, Denison CM, Lester SC, DiPiro PJ, Smith DN, Meyer JE. Fibrous nodules found at large-core needle biopsy of the breast: imaging features. *Radiology* 1999; 211: 535-40.
3. Revelon G, Sherman ME, Gatewood OM, Brem RF. Focal fibrosis of the breast: imaging characteristics and histopathologic correlation. *Radiology* 2000; 216: 255-9.
4. Rosen EL, Soo MS, Bentley RC. Focal fibrosis: a common breast lesion diagnosed at imaging-guided core biopsy. *AJR Am J Roentgenol* 1999; 173: 1657-62.
5. You JK, Kim EK, Kwak JY, Kim MJ, Oh KK, Park BW, et al. Focal fibrosis of the breast diagnosed by a sonographically guided core biopsy of nonpalpable lesions: imaging findings and clinical relevance. *J Ultrasound Med* 2005; 24: 1377-84.
6. Venta LA, Wiley EL, Gabriel H, Adler YT. Imaging features of focal breast fibrosis: mammographic-pathologic correlation of non-calcified breast lesions. *AJR Am J Roentgenol* 1999; 173: 309-16.
7. Rotter K, Haentschel G, Koethe D, Goetz L, Bornhofen-Poschke A, Lebrecht A, et al. Evaluation of mammographic and clinical follow-up after 755 stereotactic vacuum-assisted breast biopsies. *Am J Surg* 2003; 186: 134-42.
8. Wiratkapun C, Wibulpholprasert B, Wongwaisayawan S, Pulpinyo K. Nondiagnostic core needle biopsy of the breast under imaging guidance: result of rebiopsy. *J Med Assoc Thai* 2005; 88: 350-7.
9. Lee CH, Philpotts LE, Horvath LJ, Tocino I. Follow-up of breast lesions diagnosed as benign with stereotactic core-needle biopsy: frequency of mammographic change and false-negative rate. *Radiology* 1999; 212: 189-94.

Focal fibrosis ในเต้านมที่วินิจฉัยโดยการตัดชิ้นเนื้อตรวจโดยใช้เข็ม

ชลทิพย์ วิรัตกพันธ์, อรพิน ชาญสันติ, บุษณี วิบูลผลประเสริฐ, ภาณุวัฒน์ เลิศสิทธิชัย

ภูมิหลัง: Focal fibrosis ในเต้านมเป็นพยาธิสภาพที่พบได้ไม่บ่อย ลักษณะทางแมมโมแกรมและคลื่นเสียงความถี่สูงแยกได้ยากจากมะเร็งเต้านม ความสอดคล้องกับผลพยาธิวิทยาที่ได้จากการตัดชิ้นเนื้อตรวจโดยใช้เข็ม และการติดตามผลมีความจำเป็นเพื่อหลีกเลี่ยงผลลบลง

วัตถุประสงค์: เพื่อศึกษาลักษณะของ focal fibrosis ในแมมโมแกรมและคลื่นเสียงความถี่สูง และศึกษาผลลบลงในการวินิจฉัย focal fibrosis ด้วยวิธีตัดชิ้นเนื้อตรวจโดยใช้เข็ม

วัสดุและวิธีการ: ผู้ที่ได้รับการวินิจฉัยว่าเป็น focal fibrosis จากการตัดชิ้นเนื้อตรวจโดยใช้เข็มจำนวน 82 ราย ในระยะเวลาการศึกษา 7 ปี

ผลการศึกษา: จาก 38 รอยโรคที่ตรวจพบด้วยแมมโมแกรม พบความผิดปกติที่เป็นก้อนทึบ 12 ราย (ร้อยละ 32), แคลเซียม 14 ราย (ร้อยละ 37), ก้อนทึบที่มีแคลเซียม 4 ราย (ร้อยละ 11), การบิดเบี้ยวของเนื้อเต้านม 1 ราย (ร้อยละ 3) ในขณะที่ร้อยละ 81 ของรอยโรคที่พบจากคลื่นเสียงความถี่สูงเป็นก้อนทึบบนแบบ hypoechoic พบลักษณะที่สงสัยต่อมะเร็ง ได้แก่ รูปร่างขรุขระ 37 ราย (ร้อยละ 55), ขอบไม่ชัด 38 ราย (ร้อยละ 57) และเงาหลังก้อน 28 ราย (ร้อยละ 42) รอยโรคร้อยละ 59 จัดอยู่ใน BI-RADS 4A ผู้ป่วย 13 ราย ได้รับการผ่าตัดต่อ ไม่พบมะเร็งในผู้ป่วยที่ทำการศึกษา

สรุป: Focal fibrosis มีลักษณะแมมโมแกรมและคลื่นเสียงความถี่สูงที่แยกได้ยากจากมะเร็งเต้านม การวินิจฉัยที่แน่นอนจำเป็นต้องตัดชิ้นเนื้อตรวจ ซึ่งวิธีการตัดชิ้นเนื้อตรวจโดยใช้เข็มเป็นวิธีที่มีประโยชน์ ไม่พบผลลบลงจากการวินิจฉัย focal fibrosis ด้วยวิธีนี้
