

Anatomical Relationship between the Deep Peroneal Nerve and the Anterolateral Surface of the Tibia in Thai Cadavers

Janyarak Suriyuth MSc*, Kittikun Viwatpinyo PhD*,
Chanakarn Phornphutkul MD**, Pasuk Mahakkanukrauh MD*

* Department of Anatomy, Faculty of Medicine, Chiang Mai University, Chiang Mai, Thailand

** Department of Orthopaedics, Faculty of Medicine, Chiang Mai University, Chiang Mai, Thailand

Background: The deep peroneal nerve innervates muscles of the anterior leg compartment and the dorsum of the foot, and also receives sensation from the first interdigital cleft of the foot. Along its course in lower part of the leg, this nerve is very close to the anterolateral surface of the tibia and might be vulnerable to injury in fractures of the tibia or during surgery.

Objective: The objective of this study is to clarify the relationship between the deep peroneal nerve and anterolateral surface of tibia.

Material and Method: Variations in the course of the deep peroneal nerve related to the anterolateral surface of tibia were investigated by dissection of 82 legs from 45 fresh cadavers. The distance by which the deep peroneal nerve was directly contacted to the tibia was measured and compared to the length from the tibial tuberosity to the medial malleolus. The length of that association, as a percentage of the distance from the tibial tuberosity to the medial malleolus, was calculated.

Results: The fraction of the distance along which the deep peroneal nerve was in direct contact with the anterolateral surface of the tibia as a percentage of the distance between the tibial tuberosity and the medial malleolus ranged from 40.38% to 84.11%, with an average of 64.87% (95% confidence interval: 63.23-66.52%). In the majority of the legs studied (52.44%), the percentage range between 60-70%.

Conclusion: An majority of the deep peroneal nerve was directly in contact with the anterolateral surface of tibia and ranged from 60-70% of the distance between tibia tuberosity and medial malleolus. Surgical incision along this area should be carefully performed.

Keywords: Deep peroneal nerve, Anterolateral surface of tibia, Leg surgery

J Med Assoc Thai 2015; 98 (2): 207-11

Full text. e-Journal: <http://www.jmatonline.com>

The deep peroneal nerve (DPN) is the nerve innervating the muscles of the anterior compartment of the leg, including the tibialis anterior muscle, the extensor hallucis longus muscle, the extensor digitorumlongus muscles and the peroneus tertius muscle. Those muscles are essential for performing dorsiflexion of the ankle joint. The terminal branches of the DPN supply the ankle joint, the extensor digitorumbrevis muscle, and the extensor hallucis brevis muscle, as well as receiving sensation from the interdigital cleft between the great and second toes. As the nerve descends the leg into the ankle region, it passes deep into the extensor digitorumlongus muscle and comes in close contact with the anterolateral surface of the tibia and the adjacent interosseous membrane^(1,2). The location of that portion of the deep peroneal nerve makes it susceptible to injuries such as

during procedures to release compartment syndrome, fractures of the tibia, and surgical fixation of the tibia. A previous study of the deep peroneal nerve course divided the tibia into four equal zones, reporting that the nerve is in direct contact with the tibia and the interosseous membrane primarily in zones 2 and 3, but the study did not specify the precise length of contact in relation to the tibial length⁽³⁾. Other studies found that the deep peroneal nerve becomes significantly dysfunctional in up to 19% of patients following treatment of a tibial fracture involving in tramedullary nailing^(4,5). A case report of a spiral fracture in the distal third of the tibia suggested that iatrogenic injury of neurovascular structures during fracture fixation was of clinical importance, and the location of these structures, particularly at the anterolateral surface of tibia, should be considered⁽⁶⁾. The course of the deep peroneal nerve along the surface of the tibia is also crucial during application of tibial plates and screws, as longer plates might accidentally disrupt neurovascular structures, especially in the distal leg region it has been found in case reports^(7,8). It has also been suggested

Correspondence to:

Mahakkanukrauh P, Department of Anatomy, Faculty of Medicine, Chiang Mai University, Chiang Mai 50200, Thailand.

Phone: +66-53-945312

E-mail: pasuk.m@cmu.ac.th

that motor branches of the deep peroneal nerve in the middle part of the tibia are at risk of injury thereafter from tibial osteotomy procedures⁽⁹⁾. A review of published articles found few detailed anatomical investigations of the relationship between the deep peroneal nerve and the anterolateral side of tibia. The objective of this study is to help clarify the location of the deep peroneal nerve that is directly related with the anterolateral surface of the tibia.

Material and Method

The method in the present study was approved by the Institutional Ethical Review Board of Faculty of Medicine, Chiang Mai University, and informed consent of next of kin was exempted. Cadavers selected to be investigated in this study were obtained following institutional body donation procedures, and donation forms, which were signed by donors prior to their death. Dissection of 82 legs was performed in fresh, non-embalmed cadavers of known sex, height and age at death. All legs used in the study were free from pathologic conditions, malformations, prior surgical treatments and other conditions that could make them unsuitable for detailed measurement. Dissection and data collection were performed from June 2013 to July 2014 in the Surgical and Cadaveric Training Center, Faculty of Medicine, Chiang Mai University. The torso were in supine position, and the dissection procedure began with a skin incision extending from the most prominent point of the tibial tuberosity to the third metatarsophalangeal joints in a vertical line. After careful removal of skin and subcutaneous tissues of the anterior leg region, the common peroneal and the superficial peroneal and the deep peroneal nerves were identified in the area. The course of the deep peroneal nerve was then investigated from its branching point at the common peroneal nerve to its contact point on the anterolateral surface of the tibia (Fig. 1). The distance from the tip of the tibial tuberosity to this contact point was measured and calculated as a percentage of the length of tibia from the tip of the tibial tuberosity to the medial malleolus. Results were statistically analyzed by using the SPSS version 18 (SPSS Inc., Chicago, IL). Descriptive statistics including mean and standard deviation with 95% confidence interval of the obtained data were analyzed and the scatter plot of locations where the DPN was directly related to the anterolateral surface of the tibia in percentages of tibial length were made. For non-metric data, the independent t-test was also performed to compare means between males and

females. Paired t-test was used to compare means between left and right sides, with *p*-value less than 0.05 is considered significantly different.

Results

Eighty-two legs (41 from each side) from 30 male and 15 female cadavers were dissected. The average age of death is 64.95 years, with standard deviation of 12.72 years. The average height of the cadavers was 163.37±6.97 centimeters and the average measured length of the tibia from tibial tuberosity to medial malleolus was 31.78±1.96 centimeters. Dissection of the deep peroneal nerve measured the distance along which that nerve was directly in contact with the anterolateral surface of the tibia. The distance from the tip of the tibial tuberosity to this contact point as a percentage of the length of the tibia ranged from 40.38% to 84.11%, with an average value of 64.87% (95% confidence interval: 63.23-66.52%). A scatter plot of DPN locations where the nerve became related with the anterolateral surface of the tibia in each specimen is shown in Fig. 2.

The data were further analyzed by dividing the range of DPN locations into five intervals and determined the frequency of DPN in each interval. As

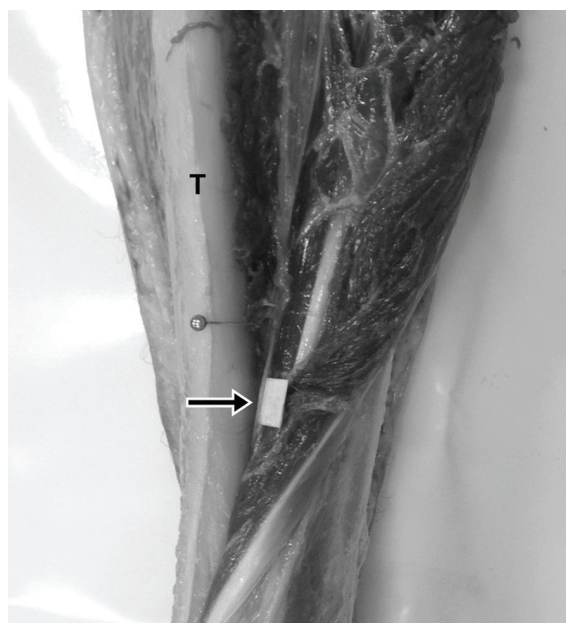

Fig. 1 Dissected left leg of a cadaver showing the deep peroneal nerve (arrow) just lateral to the anterolateral surface of the tibia (T). The muscles of the anterior compartment of the leg are partially reflected laterally for visualization purposes.

shown in Fig. 3, the DPN in a majority of specimens (43 legs or 52.44 percentages) was found within a range of 60.1-70.0% of tibial length. To compare distance of DPN location, there was no statistically significant difference between left and right legs, and between genders (p -value <0.05).

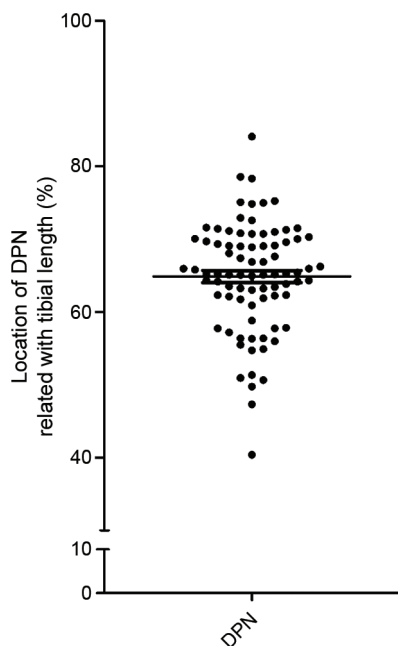


Fig. 2 Scatterplot of locations where the DPN is directly related to the anterolateral surface of the tibia calculated as a percentage of the length from the tibial tuberosity to the medial malleolus. Each dot represents one specimen. The long wide horizontal bar represents the average value and the two short horizontal bars show the standard error of mean (SEM).

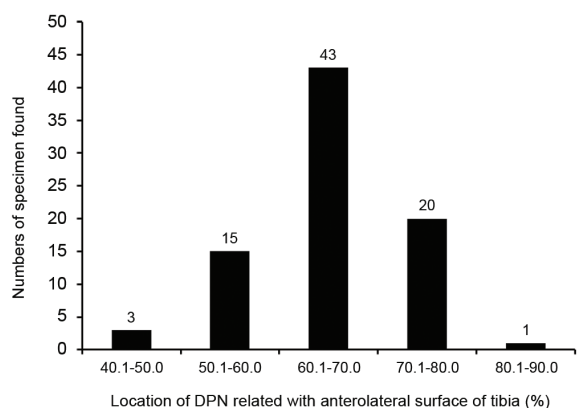


Fig. 3 Bar graph of intervals of percentages of DPN locations related with the anterolateral surface of the tibia by number of specimens.

Discussion

Compared to other neurovascular structures in the leg region, there are relatively few records of anatomical variations in the deep peroneal nerve. There have been case reports of branches from the deep peroneal nerve that receive sensation from the dorsum of the foot instead of from the superficial peroneal nerve⁽¹⁰⁾, and of the motor branch supplying the peroneus longus muscle⁽¹¹⁾. In the present study, no anatomical anomalies were found during dissection of this nerve, all of which were located deep in the extensor digitorum longus muscle and situated adjacent to the anterolateral surface of tibia before descending into the dorsum of the ankle joint. However, the measured distances from the tibial tuberosity to the point that the DPN contacts with the anterolateral tibia were varied. The authors found that the points of direct contact ranged from 40 to 80% of the length from the tibial tuberosity to the medial malleolus and the highest frequency in the 60.1-70.0% group. This study found some locations of the DPN different from those in a related study⁽³⁾ which suggested that the susceptible zone for DPN injury was between 25% to 75% of the tibial length. The present study found that the proximal 40% was the DPN safe zone. No surgical exploration was required. Based on the results of this study, the surgeons should consider this nerve when performing tibial surgery from 40% up to 84% of the relative length of the tibia. The present study confirms that the DPN is a vulnerable structure due to its proximity to the bone and needs to be identified even in certain procedures involving limited incisions such as minimally invasive platingosteosynthesis (MIPO). In addition, the results of the present study suggest that surgeons should consider this nerve when performing surgical exploration on the distal half of anterolateral surface of the tibia, particularly around 60 to 70% distal to tibial tuberosity. As the demographic data suggest, it is recommended that these results be applied to adult patients. Another study found variations of the peroneal nerves in fetuses⁽¹²⁾. In addition, there might be differences in the DPN safe zone in children and adolescents due to rapid bone growth during that period.

Conclusion

The location of the deep peroneal nerve is directly adjacent to the anterolateral surface of the tibia, the site most vulnerable to injuries, and is between 60 to 70% of the length of the tibia from the tibial tuberosity to medial malleolus. This finding should

alert surgeons to be aware of possible DPN damage in trauma patients and to avoid iatrogenic injury during the application of plates, interlocking screws, external fixator pins or other related tibial surgeries.

What is already known on this topic?

Most of the previous studies regarding anatomy of the deep peroneal nerve with relationship to tibia are case studies from iatrogenic nerve injuries, and cadaveric dissections with relatively small number of embalmed specimens. These prior researches mentioned only broad area that need to be avoided by surgeons, about distal one-third length of tibia.

What this study adds?

This present research adds the information about the direct relationship between the deep peroneal nerve and the anterolateral surface of tibia from larger number of specimen studied (82 legs). This study also gives more specific location of the deep peroneal nerve that could be found during tibia surgery, and should be more useful for planning safe surgery and for reduce the chance of nerve damage.

Acknowledgement

This research was financially supported by a basic health science, research grant from the Faculty of Medicine, Chiang Mai University. The authors would also like to thank all the staff of the Gross Anatomy Laboratory, Department of Anatomy, Faculty of Medicine, Chiang Mai University, for preparation of the cadavers. Sirichai Luevitoonvechkij MD, for his helpful suggestions and to G Lamar Robert PhD, for reviewing the manuscript.

Potential conflicts of interest

None.

References

1. Standring S. Leg. In: Standring S, editor. Gray's anatomy: the anatomical basis of clinical practice. 40th ed. Philadelphia: Elsevier Churchill Livingstone; 2008: 1411-28.
2. Lawrence SJ, Botte MJ. The deep peroneal nerve

in the foot and ankle: an anatomic study. *Foot Ankle Int* 1995; 16: 724-8.

3. Lui TH, Chan LK. Deep peroneal nerve injury following external fixation of the ankle: case report and anatomic study. *Foot Ankle Int* 2011; 32: S550-5.
4. Robinson CM, O'Donnell J, Will E, Keating JF. Dropped hallux after the intramedullary nailing of tibial fractures. *J Bone Joint Surg Br* 1999; 81: 481-4.
5. Williams J, Gibbons M, Trundle H, Murray D, Worlock P. Complications of nailing in closed tibial fractures. *J Orthop Trauma* 1995; 9: 476-81.
6. Miki RA, Lawrence JP, Gillon TJ, Lawrence BD, Zell RA. Anterior tibial artery and deep peroneal nerve entrapment in spiral distal third tibia fracture. *Orthopedics* 2008; 31: 1240.
7. Pichler W, Grechenig W, Tesch NP, Weinberg AM, Heidari N, Clement H. The risk of iatrogenic injury to the deep peroneal nerve in minimally invasive osteosynthesis of the tibia with the less invasive stabilisation system: a cadaver study. *J Bone Joint Surg Br* 2009; 91: 385-7.
8. Phisitkul P, McKinley TO, Nepola JV, Marsh JL. Complications of locking plate fixation in complex proximal tibia injuries. *J Orthop Trauma* 2007; 21: 83-91.
9. Kirgis A, Albrecht S. Palsy of the deep peroneal nerve after proximal tibial osteotomy. An anatomical study. *J Bone Joint Surg Am* 1992; 74: 1180-5.
10. Rai R, Ranade AV, Sequeira S, Vadgaonkar R, Jiji PJ, Mamatha T. Unique distribution by the peroneal nerves: a case report. *Surg Radiol Anat* 2012; 34: 559-61.
11. Verma R, Mishra A, Das S, Vasudeva N. An anomalous variation in the innervation pattern of the peroneus longus muscle by deep peroneal nerve: a case report. *Annals of Ibadan Postgraduate Medicine* 2006; 4: 41-4.
12. Wahee P, Aggarwal A, Harjeet, Sahni D. Variable patterns of cutaneous innervation on the dorsum of foot in fetuses. *Surg Radiol Anat* 2010; 32: 469-75.

ความสัมพันธ์ทางกายวิภาคศาสตร์ระหว่างเส้นประสาท *deep peroneal* กับพื้นผิวด้าน *anterolateral* ของกระดูก *tibia* ในกลุ่มประชากรไทยในร่างอาจารย์ใหญ่และความสำคัญทางคลินิก

จรรยารักษ์ สุริยทศ, กิตติคุณ วิวัฒน์ภิญโญ, ชนะการ พรพัฒน์กุล, ผาสุก มหรรณานูเคราะห์

ภูมิหลัง: เส้นประสาท *deep peroneal* อยู่ภายในบริเวณส่วนหน้าของขาส่วนล่างและควบคุมกล้ามเนื้อของขาส่วนล่างด้านหน้าและหลังเท้า รวมทั้งรับสัมผัสจากหลังเท้าระหว่างนิ้วหัวแม่เท้าและนิ้วชี้ในช่วงของขาส่วนล่าง เส้นประสาทนี้จะอยู่ชิดกับพื้นผิวด้าน *anterolateral* ของกระดูก *tibia* และมีความเสี่ยงต่อการบาดเจ็บในภาวะกระดูก *tibia* หักหรือในระหว่างการผ่าตัด

วัตถุประสงค์: เพื่อสำรวจความสัมพันธ์ระหว่างเส้นประสาท *deep peroneal* กับพื้นผิวด้าน *anterolateral* ของกระดูก *tibia* วัดดูและวิธีการ: ศึกษาจากขาจำนวน 82 ขา จากร่างอาจารย์ใหญ่แบบสด จำนวน 45 ร่าง โดยทำการวัดระยะทางจากปลายยอดของ *tibial tuberosity* จนถึงจุดที่เส้นประสาท *deep peroneal* เริ่มต้นทอดชิดกับพื้นผิวด้าน *anterolateral* ของกระดูก *tibia* แล้วเทียบกับความยาวระหว่างปลายยอดของ *tibial tuberosity* ถึง *medial malleolus* โดยคิดเป็นร้อยละของระยะทาง

ผลการศึกษา: พบว่าจุดที่เส้นประสาท *deep peroneal* เริ่มทอดชิดกับพื้นผิวด้าน *anterolateral* ของกระดูก *tibia* คือตั้งแต่ร้อยละ 40.38 ถึง 84.11 โดยมีค่าเฉลี่ยที่ร้อยละ 64.87 ของความยาวระหว่างปลายยอดของ *tibial tuberosity* ถึง *medial malleolus* และพบว่าส่วนใหญ่ (ร้อยละ 52.44) จะมีระยะดังกล่าวอยู่ในช่วงระหว่างร้อยละ 60 ถึง 70 ของความยาวระหว่างปลายยอดของ *tibial tuberosity* ถึง *medial malleolus*

สรุป: การผ่าตัดบริเวณ *anterolateral surface* ของกระดูก *tibia* ในตำแหน่งร้อยละ 60 ถึง 70 ของความยาวระหว่าง *tibial tubercle* ถึง *medial malleolus* อาจเสี่ยงต่อการเกิดภัยอันตรายต่อ *deep peroneal nerve*
