

Comparison of Microcalcifications Detection and Characterization in Digital Breast Tomosynthesis (DBT) With Synthesized 2D Mammography (SM) versus DBT with Full-Field Digital Mammography (FFDM)

Sarunthorn Lapkittichot MD¹, Phitchaya Monsintorn MD¹, Vasiyapha Patanajareet MD¹

¹ Division of Diagnostic Radiology, Department of Diagnostic and Therapeutic Radiology, Faculty of Medicine, Ramathibodi Hospital, Mahidol University, Bangkok, Thailand

Background: Synthesized 2D mammography (SM) has been invented to help lower the radiation dose by circumventing the need for acquiring full-field digital mammography (FFDM) when digital breast tomosynthesis (DBT) is performed. Prior studies have compared microcalcifications detection and characterization in FFDM with SM or with DBT alone. Only few studies have compared DBT plus SM and DBT plus FFDM.

Objective: To determine the performance of DBT with SM versus DBT with FFDM in detection and characterization of microcalcifications.

Materials and Methods: Three hundred three paired examinations of 2D plus DBT images in the same session were performed. Fifty-five biopsy-proven malignancy, 198 biopsy-proven benign microcalcifications, and 50 randomly selected negative screening studies were retrospectively reviewed by two radiologists. Comparison of sensitivity and specificity between the two modalities were performed.

Results: From the 55 malignant microcalcifications, three cases were missed by DBT with FFDM but detected and correctly categorized as malignant by DBT with SM. Only one case of malignant microcalcifications was not detected by DBT with SM, and the present case was also miscategorized as benign by DBT with FFDM. There were no statistically significant differences in both detections ($p=0.42$), and characterization ($p=0.65$) of microcalcification between both modalities. In DBT with SM, the sensitivity was higher, and the specificity was lower for both detection and characterization of microcalcification when compared to DBT with FFDM.

Conclusion: DBT in combination with SM is comparable to DBT in combination with FFDM for detection and characterization of microcalcifications.

Keywords: Synthesized 2D mammography; Full-field digital mammography; Digital breast tomosynthesis; Microcalcifications detection and characterization

Received 6 May 2021 | Revised 27 July 2021 | Accepted 30 July 2021

J Med Assoc Thai 2021;104(9):1503-10

Website: <http://www.jmatonline.com>

In 2011, the U.S. Food and Drug Administration (FDA) approved the clinical use of digital breast tomosynthesis (DBT) in combination with digital mammography. DBT system measure X-ray transmission through the breast over a limited range of angles, followed by reconstruction of a series of images of the breast resulting in slices of images that

represent breast tissue at different focal planes⁽¹⁾. Many studies have supported the use of DBT with full-field digital mammography (FFDM) in breast cancer screening due to higher accuracy in breast cancer detection, especially in cases with masses or architectural distortion in radiographic imaging⁽²⁻⁵⁾.

The main disadvantages of DBT utilization in combination with FFDM are increased radiation dose to almost two times of screening by FFDM alone and longer image acquisition time. Some institutions have opted screening program using DBT alone to decrease the radiation dose. The main limitations of breast cancer screening with DBT alone are lack of overall view of both breasts to evaluate breast density or asymmetry.

Synthesized 2D mammography (SM) was introduced in 2014 as a solution by creating reconstruction 2D images from obtained DBT datasets. Early studies showed no significant cancer detection rate when using DBT in combination with SM when

Correspondence to:

Lapkittichot S.

Department of Diagnostic and Therapeutic Radiology, Faculty of medicine, Ramathibodi Hospital, Mahidol University, Bangkok 10400, Thailand.

Phone: +66-84-2455236, +66-2-2011297

Email: Sarunthorn.lap@gmail.com

How to cite this article:

Lapkittichot S, Monsintorn P, Patanajareet V. Comparison of Microcalcifications Detection and Characterization in Digital Breast Tomosynthesis (DBT) With Synthesized 2D Mammography (SM) versus DBT with Full-Field Digital Mammography (FFDM). *J Med Assoc Thai* 2021;104:1503-10. doi.org/10.35755/jmedassocthai.2021.09.12882

compared to using DBT with FFDM^(5,6), but lower sensitivity in microcalcifications detection was observed when DBT was used alone compared with using FFDM^(7,8). Most available studies compared microcalcifications detection and characterization in FFDM with SM or DBT alone, but not SM as an adjunct to DBT^(7,9,10).

The aim of the present study was to compare microcalcifications detection and characterization in DBT combined with FFDM versus DBT combined with SM.

Materials and Methods

The present study was approved by Human Research Ethics Committee, Faculty of Medicine Ramathibodi Hospital, Mahidol University (COA. MURA2020/328).

Patients

All patients underwent screening mammogram using simultaneous acquisition of DBT, SM, and FFDM as part of the routine clinical care in Ramathibodi Hospital, Mahidol University, Thailand between January 2014 and September 2019. Patients with known breast cancer or incomplete examinations were excluded. Two hundred fifty-three mammographic examinations showing microcalcifications warranting biopsy were identified based on the electronic medical databases of the radiological reports. Another 50 negative screening cases, which were assigned as BI-RADS 1 with at least two years of consecutive negative screening, were randomly selected from the database as negative controls.

Image technique

All the included patients underwent breast cancer screening using the Selenia Dimensions unit with integrated 2D and 3D mammography in the COMBO mode with acquisition of 2D plus DBT images in the same session (Hologic, Bedford, MA, USA). The X-ray tube moved over a 15-degree arc. The 2D and 3D images were acquired at the same examination with a single breast position and compression. Each 2D and 3D image included bilateral mediolateral oblique (MMO) and craniocaudal (CC) mammogram and the DBT datasets were reconstructed into synthesized 2D mammography using C-view™ software.

Image review

Two radiologists with at least four years of experience in breast imaging and have been

interpreting DBT and SM since 2015 participated in the present study. Seventy-five exams were randomly selected from the entire samples and were reviewed by both radiologists for the purpose of inter-reader agreement assessment. The rest of the samples were reviewed solely by the second radiologist for assessment of detection and characterization of microcalcifications.

The interpretations were done independently on a Hologic Secure View reading station in two separate viewing periods using standard hanging protocol. The radiologists retrospectively reviewed all DBT combined with FFDM in the first period. To minimize the learning and memory bias, the DBT combined with SM were reviewed in the second period with at least 4-week interval between sessions. The radiologists were blinded to the patient's clinical information, prior assigned BI-RADS categories, and histopathological reports.

- Breast density was rated using FFDM in the first session and SM in the second session according to ACR BI-RADS categories as follows, almost entirely fatty, scattered fibroglandular, heterogeneously dense, or extremely dense.

- Microcalcification detection were recorded as either present or absent. If there were microcalcifications, the location of the microcalcifications were recorded in term of side as right or left, and quadrant of the breast as upper outer, mid upper, upper inner, mid inner, lower inner, mid lower, lower outer, or mid outer.

- Microcalcifications were characterized utilizing breast imaging lexicon to describe the morphology and BI-RADS categories from 2 to 5 to assess the probability of malignancy. BI-RADS 2 and 3 were identified as benign, while 4 and 5 were identified as malignant. The histopathology findings from stereotactic core needle biopsy and surgery were used as the gold standard for the final diagnosis.

Statistical analysis

Statistical analysis was conducted on per examination basis (taking the most suspicious finding into account) using Stata Statistical Software, version 16.1 (StataCorp LLC, College Station, TX 77845, USA).

Mean age and standard deviation of each patient group were calculated and compared using t-test. Nominal demographic data were described by total number and percentages.

Cohen's kappa values were calculated to assess inter-reader and intra-reader agreement. The kappa

value was interpreted as follows, values of 0 or less as indicating no agreement, 0.01 to 0.20 as none to slight, 0.21 to 0.40 as fair, 0.41 to 0.60 as moderate, 0.61 to 0.80 as substantial, and 0.81 to 1.00 as almost perfect agreement⁽¹¹⁾.

The overall sensitivity and specificity with 95% confidence interval (CI) of both the detection and characterization of microcalcifications evaluated by the second radiologist were calculated for DBT combined with FFDM and DBT combined with SM as following:

Sensitivity of microcalcification detection = [number of cases interpreted as positive for microcalcifications/total no. of true microcalcifications] × 100

Specificity of microcalcification detection = [number of cases interpreted as BI-RADS 1 (no microcalcifications)/total no. of cases without microcalcifications] × 100

Sensitivity of microcalcification detection = [number of cases interpreted as BI-RADS 4 or 5/total no. of pathology-proven malignant microcalcifications] × 100

Specificity of microcalcification detection = [number of cases interpreted as BI-RADS 2 or 3/total no. of pathology-proven benign microcalcifications] × 100

The accuracy of the first radiologist was not calculated due to small sample size.

To assess for differences in detection and characterization between two modes, the mean area under the receiver operating characteristic (ROC) curve with 95% CI was calculated and compared using Exact McNemar's test. All statistical tests were two-sided, where a p-value of less than 0.5 was considered to be statistically significant.

Results

Patient characteristics

Among the 303 patients included in the present study, there were 50 randomized negative examinations, 55 malignant, and 198 benign microcalcifications. All patients were asymptomatic at the time of the examination. The mean age and standard deviation of patients in each category are summarized in Table 1.

The prevalence of each pathological diagnosis of both the benign and malignant calcifications are shown in Table 2. Some cases had more than one pathological diagnosis. The benign histopathological diagnosis with highest frequency was fibrocystic change, followed by fibroadenoma, columnar cell

Table 1. Mean age with SD of each group of patients

Parameters	Diagnosis					
	Malignant microcalcifications (n=55)		Benign microcalcifications (n=198)		Negative controls (n=50)	
	Mean	SD	Mean	SD	Mean	SD
Age (year)	55.3	9.4	55.1	9.7	59.2	8.8

SD=standard deviation

Table 2. Pathological diagnosis of cases with microcalcifications

	Histology	n (%)*
Benign microcalcifications	Fibrocystic changes	93 (46.97)
	Fibroadenoma	33 (16.67)
	Columnar cell change	23 (11.62)
	Atypical ductal hyperplasia	21 (10.61)
	Sclerosing adenosis	16 (8.08)
	Intraductal papilloma	14 (7.07)
	Usual ductal hyperplasia	12 (6.06)
	Apocrine metaplasia	5 (2.53)
	Flat epithelial atypia	4 (2.02)
	Atypical lobular hyperplasia	2 (1.01)
	Others**	35 (17.68)
Malignant microcalcifications	Ductal carcinoma in situ	50 (90.91)
	Invasive ductal carcinoma	7 (12.73)
	Invasive mammary carcinoma	1 (1.82)

* Some cases have more than one pathological diagnosis. The percentages were calculated with total number of patients in each group

** Others included benign breast tissue, dilated or atrophic duct, vascular calcification, and pseudo-angiomatous stromal hyperplasia

change, and atypical ductal hyperplasia. Almost all the malignant microcalcifications had ductal carcinoma in situ (DCIS) as definitive pathological diagnosis. Three patients (5.45%) were determined to have both DCIS and invasive ductal carcinoma (IDC) from the same biopsy sample.

Intra- and inter-observer agreements

There were almost perfect intra-observer agreements when comparing same radiologist using FFDM and DM with using FFDM and SM in both radiologist 1 with 96.00% agreement, kappa value 0.8780, and radiologist 2 with 96.7% agreement, kappa value 0.8935.

Overall interobserver agreements between the two radiologists were moderate with value of 88.00% for both modalities, and the kappa values were 0.5455 for FFDM with DM and 0.5503 for FFDM with SM, respectively. These represented moderate interobserver agreements for both modalities.

Table 3. Breast density in each modality by two radiologists

Breast density	Radiologist 1; n (%)		Radiologist 2; n (%)	
	DBT with FFDM	DBT with SM	DBT with FFDM	DBT with SM
Almost entirely fatty	0 (0.00)	0 (0.00)	8 (2.64)	11 (3.63)
Scattered fibroglandular	10 (13.33)	18 (24.00)	33 (10.89)	27 (8.91)
Heterogeneously dense	56 (74.67)	46 (61.33)	237 (78.22)	227 (74.92)
Extremely dense	9 (12.00)	11 (14.67)	25 (8.25)	38 (12.54)

DBT=digital breast tomosynthesis; FFDM=full-field digital mammography; SM=synthesized 2D mammography

Table 4. BI-RADS distribution of cases with microcalcification in each modality by two radiologists

BI-RADS	Radiologist 1; n (%)		Radiologist 2; n (%)	
	DBT with FFDM	DBT with SM	DBT with FFDM	DBT with SM
2	3 (4.92)	2 (3.23)	4 (1.65)	8 (3.21)
3	13 (21.31)	18 (29.03)	56 (23.05)	49 (19.68)
4	42 (68.85)	38 (61.29)	177 (72.85)	189 (75.90)
4A	22 (36.07)	18 (29.03)	31 (12.76)	62 (24.90)
4B	12 (19.67)	14 (22.58)	109 (44.86)	107 (42.97)
4C	8 (13.11)	6 (9.68)	37 (15.23)	20 (8.03)
5	3 (4.92)	4 (6.45)	6 (2.47)	3 (1.20)

BI-RADS=breast imaging-reporting and data system; DBT=digital breast tomosynthesis; FFDM=full-field digital mammography; SM=synthesized 2D mammography

Breast density and BI-RADS category assignment

Breast density was assessed using DM in the first session and SM in the second session. About three quarter of the patients were assigned with heterogeneously dense breast by both radiologists in both modalities. However, there were higher numbers of patients assigned with extremely dense breast by both radiologists when using DBT combined with SM. The details are described in Table 3.

Table 4 shows the prevalence of each BI-RADS categories assigned to each radiologist in each modality. Most patients with microcalcifications were assigned with BI-RADS 4. The categories with highest numbers and percentages of patients were BI-RADS 4A and 4B for both radiologist in both modalities.

Detection and characterization of microcalcifications

From the 55 malignant microcalcifications, three cases (5.45%) were missed by DBT with FFDM, but detected and correctly categorized as malignant by DBT with SM. All of them were characterized

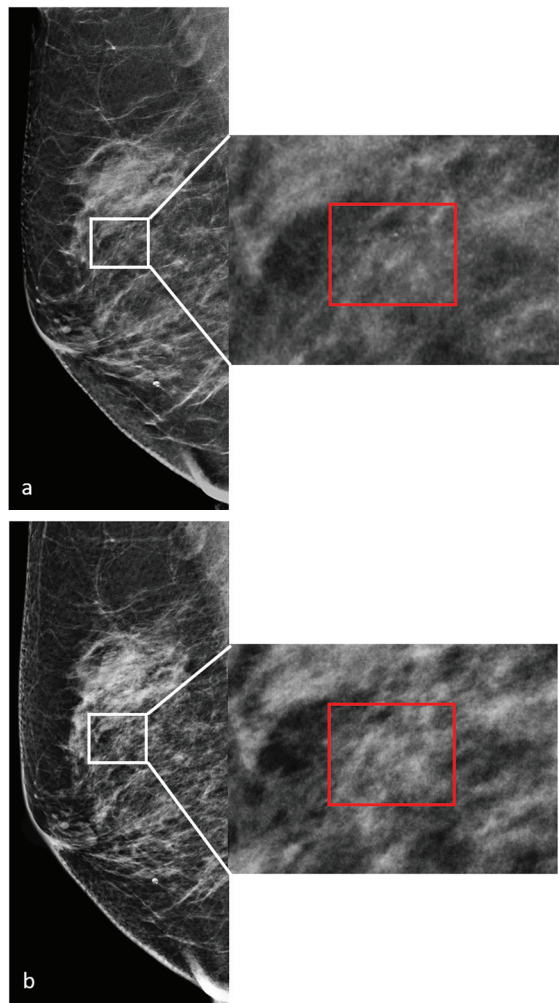


Figure 1. Screening mammography and digital magnification from MLO view images of a 63-year-old woman show (a) a group of amorphous microcalcification (red box) in the right breast when viewed in SM. (b) The same group of microcalcifications is not seen in FFDM. The histologic results from biopsy is DCIS.

as amorphous microcalcifications in one extremely dense breast and two heterogeneously dense breasts by DBT with SM. One example of these cases is shown in Figure 1. Only one case of malignant microcalcifications (1.82%) was not detected by DBT with SM (Figure 2), and this case was also miscategorized as benign (BI-RADS 3) by DBT with FFDM.

From the 198 benign microcalcifications, four cases (2.02%) were not detected by both modalities and the final histologic diagnosis were fibroadenoma, papillary lesion, and usual ductal hyperplasia. Three cases (1.51%) were not detected in DBT with FFDM, but observed in DBT with SM. Only one case (0.51%)

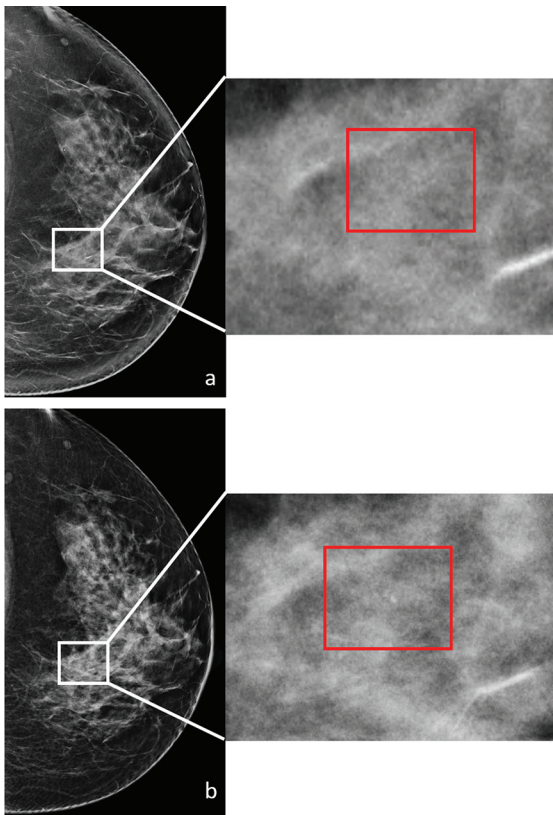


Figure 2. Screening mammography and digital magnification from CC view images of a 56-year-old woman show (a) no clear suspicious microcalcifications in SM, but (b) faint microcalcifications are detected in the left breast by FFDM. The histologic results from biopsy is DCIS with comedonecrosis.

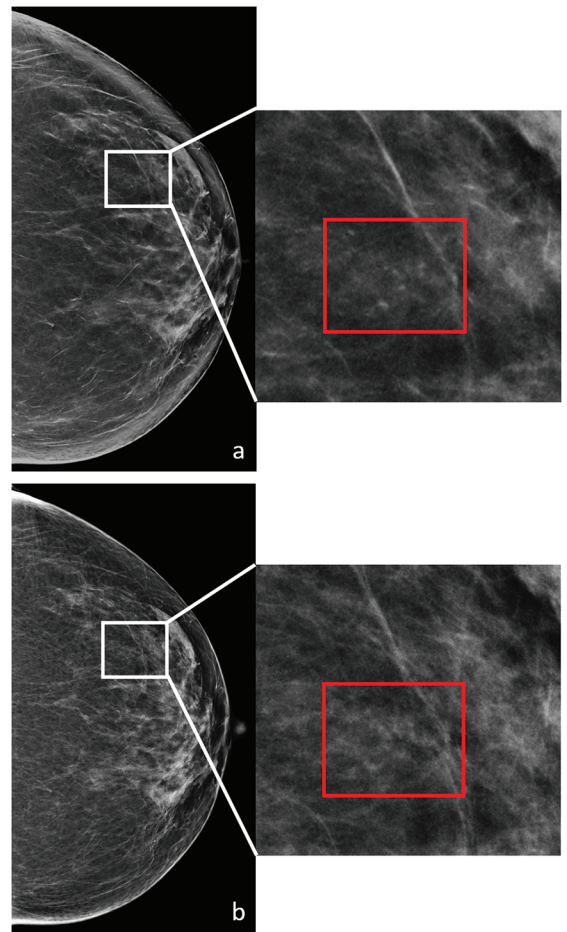


Figure 3. Screening mammography and digital magnification from CC view images of a 76-year-old woman show (a) artifacts interpreted as microcalcifications in SM and (b) no microcalcifications detected in the left breast by FFDM. No biopsy was performed, and the patient has two years of consecutive negative follow-up studies.

was missed by DBT with SM but seen in DBT with FFDM.

All the negative studies were correctly interpreted as no detected microcalcifications by DBT with FFDM. Two of the negative studies (4.00%) were falsely interpreted as positive for suspicious microcalcifications by DBT with SM. The false positive lesion is shown in Figure 3.

To determine the difference in microcalcification detection between the two modes, sensitivity, specificity, and the areas under the ROC curves (AUC) were analyzed and shown in Table 5. Overall microcalcification detection sensitivity was higher for DBT with SM (97.2%, 95% CI 94.4 to 98.9) than for DBT with FFDM (95.7%, 95% CI 92.4 to 97.8). However, the specificity for detection was lower for DBT with SM (96.0%, 95% CI 86.3 to 99.5) than for DBT with FFDM (100%, 95% CI 92.9 to 100). There is no statistically significant difference ($p=0.4222$) between ROC of DBT with FFDM (0.9783, 95% CI

0.9657 to 0.9909) and DBT with SM (0.9662, 95% CI 0.9369 to 0.9954).

There was also no statistically significant difference ($p=0.6508$) in accuracy of microcalcification characterization as benign or malignant between DBT with FFDM (AUC 0.6180, 95% CI 0.5719 to 0.6650) and DBT with SM (AUC 0.6297, 95% CI 0.5924 to 0.6670). Overall sensitivity was again higher for DBT with SM (98.1%, 95% CI 89.9 to 100) than for DBT with FFDM (92.3%, 95% CI 81.5 to 97.9). The specificity was again lower for DBT with SM (28.0%, 95% CI 21.8 to 34.9) than for DBT with FFDM (29.3%, 95% CI 23.0 to 36.3%) (Table 6). The ROC curves of DBT with FFDM and DBT with SM in microcalcification characterization are shown in Figure 4.

Table 5. Diagnostic performance of DBT with FFDM and DBT with SM for breast microcalcifications detection

	Sensitivity (%)	95% CI	Specificity (%)	95% CI	AUC	95% CI
DBT with FFDM	95.7 (242/253)	92.4 to 97.8	100 (50/50)	92.9 to 100	0.9783	0.9657 to 0.9909
DBT with SM	97.2 (246/253)	94.4 to 98.9	96.0 (48/50)	86.3 to 99.5	0.9662	0.9369 to 0.9954

DBT=digital breast tomosynthesis; FFDM=full-field digital mammography; SM=synthesized 2D mammography; CI=confidence interval; AUC=area under the receiver operating characteristic curve

Table 6. Diagnostic performance of DBT with FFDM and DBT with SM for microcalcification characterization

	Sensitivity (%)	95% CI	Specificity (%)	95% CI	AUC	95% CI
DBT with FFDM	92.3 (47/51)	81.5 to 97.9	29.3 (56/191)	23.0 to 36.3	0.6180	0.5719 to 0.6640
DBT with SM	98.1 (53/54)	89.9 to 100	28.0 (54/193)	21.8 to 34.9	0.6297	0.5914 to 0.6670

DBT=digital breast tomosynthesis; FFDM=full-field digital mammography; SM=synthesized 2D mammography; CI=confidence interval; AUC=area under the receiver operating characteristic curve

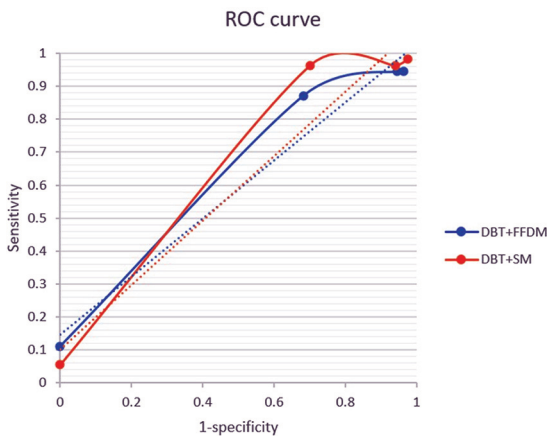


Figure 4. Receiver operating characteristic (ROC) curve of DBT with FFDM and DBT with SM for characterization of microcalcifications.

Discussion

The present studies have shown that using DBT combined with FFDM increases sensitivity and specificity of mammography in detecting cancer mainly by better detection of masses, asymmetries, and architectural distortion compared to FFDM alone. There are some concerns about using DBT alone to completely replace FFDM especially in cases where microcalcification is the dominant feature⁽¹²⁾. One early study compared the clarity of calcifications identified in DBT compared to FFDM⁽¹³⁾. Out of 110 cases reviewed, two radiologists determined that 41.6% calcifications are observed more clearly in DBT, and the clarity is the same in 50.4% of the cases. Only 8% of calcifications are seen more clearly in FFDM.

There is still controversy regarding the optimal

screening protocol after the invention of DBT. Most institutions that started implementing DBT use the modality in combination with FFDM. In a study by Gartner et al⁽¹⁴⁾ after implementing DBT combined with SM as the screening tool for breast cancer decreased the callback rate to 8.8% from 10.4% using FFDM alone, and increased detection rate to 5.4 from 4.4 cancers per 1,000, respectively.

In a summary by Ratanaprasatporn et al, DBT combined with FFDM increased radiation dose by a factor of 2.25 when compared to FFDM alone, which was still below the limit of 3 mGy per view by The Mammography Quality and Standards Act (MQSA) enforced the FDA. But it is about a twofold increase in radiation exposure⁽¹⁵⁾. To solve this problem, SM was introduced as a substitute for FFDM in the hope of using DBT with SM or SM alone as the main screening protocol. Some studies had tried to compare SM alone with FFDM alone^(16,17). However, in clinical practice, if DBT dataset was obtained with reconstruction of SM, radiologists will most likely review all images, if no certain data supported the use of SM alone as comparable to DBT combined with SM.

Murphy et al⁽¹⁸⁾ found that no lesion appeared less concerning for malignancy either in DBT or SM when compared to FFDM. But 13.3% of the lesion was assigned as BI-RADS 5 only by DBT alone. Therefore, SM is useful as a replacement for FFDM to reduce radiation and gives additional information but should be used in conjunction with DBT. Not only will reviewing the DBT dataset help detect some lesions missed by SM alone, but it will also increase the confidence for the radiologist in making the diagnosis.

The present study shows that DBT combined with

SM performance is not inferior to DBT combined with FFDM for the detection and characterization of microcalcifications in clinical setting of screening mammography. The sensitivity and specificity of the present study are slightly different from Gilbert et al⁽¹⁹⁾, which the sensitivity in microcalcification detection of DBT plus FFDM is slightly higher than DBT plus SM and the specificity in microcalcification detection of DBT plus SM is slightly higher than DBT plus FFDM. This may be due to inter-observer errors or demographic differences.

There is almost perfect agreement in the present study when the same radiologist used different modalities. There is some variability in assessment when interpretations were done by different readers using the same modality. This may eliminate the use of FFDM in screening protocol for breast cancer.

There are some limitations to implementing DBT combined with SM in breast cancer screening. First is the learning curve of radiologists after introduction of DBT to clinical practice. One study⁽²⁰⁾ showed that overall cancer detection rates for DBT were higher than those of FFDM only when cumulative DBT volume was 1,200 to 1,599 studies for radiologist who were not breast imaging subspecialists (OR 1.62, 95% CI 1.04 to 2.5, $p=0.03$). However, in the subgroup analysis, there was improvement in performance within-radiologist with increasing DBT volume both in breast imaging subspecialists and non-subspecialists with decreased recall rates. Second is the pseudocalcifications artifact that may be seen in SM, which is caused by enhancement of prominent structures such as Cooper's ligament in the breast by the algorithm used to synthesize 2D image⁽²¹⁾. This artifact may explain the two negative studies that were misinterpreted as having suspicious microcalcifications in the present study. The suggested solutions include looking at the same area in FFDM or magnification view. However, these suggestions also increase the radiation dose in the same patient to confirm the absence of a lesion. Another solution, which is also effective and does not subject the patient to more radiation, is to review the same area in another view of SM and images in the DBT dataset. The pseudocalcifications are usually not identifiable in other planes. If the lesions still existed, they would not appear as discrete findings but aligned with vessels or ligaments⁽²²⁾.

The main limitation of the present study is the study population is not comparable to the general population. The percentage of mammography with positive finding seen as microcalcifications is much

higher than general population. The radiologists assigned to retrospectively review the images were not aware of the exact number of patients in each group but certainly aware of the high concentration of positive cases with microcalcification in the present study. This may lead to higher disposition to interpret positive results than negative ones.

Conclusion

Digital breast tomosynthesis in combination with synthesized 2D mammography is comparable to digital breast tomosynthesis in combination with FFDM for detection and characterization of microcalcifications in breast cancer screening. Implementing digital breast tomosynthesis with synthesized 2D mammography without acquiring FFDM in appropriate clinical setting, such as breast cancer screening in patients with microcalcifications, will help lower patient's exposure to radiation.

What is already known on this topic?

SM has been invented by using the dataset of DBT to replace digital mammography.

What this study adds?

SM in combination with DBT is not inferior to FFDM in combination with DBT for detection and characterization of microcalcifications in breast cancer screening.

Conflicts of interest

The authors declare no conflict of interest.

References

1. Van Engen RE, Bosmans H, Bouwman RW, Dance DR, Heid P, Lazzari B, et al. Introduction. In: Protocol for the Quality control of the physical and technical aspects of digital breast tomosynthesis systems, version 1.03. Nijmegen, Netherlands: EUREF; 2018. p. 7-14.
2. Baker JA, Lo JY. Breast tomosynthesis: state-of-the-art and review of the literature. *Acad Radiol* 2011;18:1298-310.
3. Krammer J, Stepniowski K, Kaiser CG, Brade J, Riffel P, Schoenberg SO, et al. Value of additional digital breast tomosynthesis for preoperative staging of breast cancer in dense breasts. *Anticancer Res* 2017;37:5255-61.
4. Bian T, Lin Q, Cui C, Li L, Qi C, Fei J, et al. Digital breast tomosynthesis: A new diagnostic method for mass-like lesions in dense breasts. *Breast J* 2016;22:535-40.
5. Aujero MP, Gavenonis SC, Benjamin R, Zhang

- Z, Holt JS. Clinical Performance of Synthesized Two-dimensional Mammography Combined with Tomosynthesis in a Large Screening population. *Radiology* 2017;283:70-6.
6. Freer PE, Riegert J, Eisenmenger L, Ose D, Winkler N, Stein MA, et al. Clinical implementation of synthesized mammography with digital breast tomosynthesis in a routine clinical practice. *Breast Cancer Res Treat* 2017;166:501-9.
 7. Spangler ML, Zuley ML, Sumkin JH, Abrams G, Ganott MA, Hakim C, et al. Detection and classification of calcifications on digital breast tomosynthesis and 2D digital mammography: a comparison. *AJR Am J Roentgenol* 2011;196:320-4.
 8. Peppard HR, Nicholson BE, Rochman CM, Merchant JK, Mayo RC, 3rd, Harvey JA. Digital breast tomosynthesis in the diagnostic setting: indications and clinical applications. *Radiographics* 2015;35:975-90.
 9. Tagliafico A, Mariscotti G, Durando M, Stevanin C, Tagliafico G, Martino L, et al. Characterisation of microcalcification clusters on 2D digital mammography (FFDM) and digital breast tomosynthesis (DBT): does DBT underestimate microcalcification clusters? Results of a multicentre study. *Eur Radiol* 2015;25:9-14.
 10. Clauser P, Nagl G, Helbich TH, Pinker-Domenig K, Weber M, Kapetas P, et al. Diagnostic performance of digital breast tomosynthesis with a wide scan angle compared to full-field digital mammography for the detection and characterization of microcalcifications. *Eur J Radiol* 2016;85:2161-8.
 11. McHugh ML. Interrater reliability: the kappa statistic. *Biochem Med (Zagreb)* 2012;22:276-82.
 12. Horvat JV, Keating DM, Rodrigues-Duarte H, Morris EA, Mango VL. Calcifications at digital breast tomosynthesis: imaging features and biopsy techniques. *Radiographics* 2019;39:307-18.
 13. Kopans D, Gavenonis S, Halpern E, Moore R. Calcifications in the breast and digital breast tomosynthesis. *Breast J* 2011;17:638-44.
 14. Roth RG, Maidment AD, Weinstein SP, Roth SO, Conant EF. Digital breast tomosynthesis: lessons learned from early clinical implementation. *Radiographics* 2014;34:E89-102.
 15. Ratanaprasatporn L, Chikarmane SA, Giess CS. Strengths and weaknesses of synthetic mammography in screening. *Radiographics* 2017;37:1913-27.
 16. Mariscotti G, Durando M, Houssami N, Fasciano M, Tagliafico A, Bosco D, et al. Comparison of synthetic mammography, reconstructed from digital breast tomosynthesis, and digital mammography: evaluation of lesion conspicuity and BI-RADS assessment categories. *Breast Cancer Res Treat* 2017;166:765-73.
 17. Choi JS, Han BK, Ko EY, Ko ES, Hahn SY, Shin JH, et al. Comparison between two-dimensional synthetic mammography reconstructed from digital breast tomosynthesis and full-field digital mammography for the detection of T1 breast cancer. *Eur Radiol* 2016;26:2538-46.
 18. Murphy MC, Coffey L, O'Neill AC, Quinn C, Prichard R, McNally S. Can the synthetic C view images be used in isolation for diagnosing breast malignancy without reviewing the entire digital breast tomosynthesis data set? *Ir J Med Sci* 2018;187:1077-81.
 19. Gilbert FJ, Tucker L, Gillan MG, Willsher P, Cooke J, Duncan KA, et al. Accuracy of digital breast tomosynthesis for depicting breast cancer subgroups in a UK retrospective reading study (TOMMY Trial). *Radiology* 2015;277:697-706.
 20. Miglioretti DL, Abraham L, Lee CI, Buist DSM, Herschorn SD, Sprague BL, et al. Digital breast tomosynthesis: radiologist learning curve. *Radiology* 2019;291:34-42.
 21. Sujlana PS, Mahesh M, Vedantham S, Harvey SC, Mullen LA, Woods RW. Digital breast tomosynthesis: Image acquisition principles and artifacts. *Clin Imaging* 2019;55:188-95.
 22. Durand MA. Synthesized mammography: clinical evidence, appearance, and implementation. *Diagnostics (Basel)* 2018;8:22.