

Transradial Access for Non-Coronary Intervention: Initial Experience of Ramathibodi Hospital

Orapin Chansanti MD¹, Suthinee Hengriprasopchoke MD¹, Banjongsak Wedsart MD¹, Tharintorn Treesit MD¹, Chinnarat Bua-ngam MD¹, Tanapong Panpikoon MD¹,

¹ Faculty of Medicine, Ramathibodi Hospital, Mahidol University, Bangkok, Thailand

Objective: To describe initial experience of transradial access (TRA) for non-coronary intervention performed at body interventional radiology unit.

Materials and Methods: A retrospective descriptive study was performed and included 31 cases from 27 patients that underwent TRA in the present study's unit between May 2018 and January 2019. All cases were pre-operatively evaluated for radial artery size by ultrasound (US) and verified palmar arch patency using Barbeau test. To proceed to TRA, the radial artery diameter must be at least 1.8 mm and the Barbeau test must not be classified in type D. The primary endpoint was success rate. Secondary endpoints were patency of radial artery and other access site complication after TRA.

Results: The technical success rate was 100% without crossover to transfemoral access (TFA). Asymptomatic radial artery occlusion (RAO) was observed in four cases (12.9%) using US at 24-hour after the procedure. According to statistical analysis, none of the present studied parameters showed statistically significant association with the RAO. The other access site complication detected was pseudoaneurysm, which was found in two cases.

Conclusion: TRA is a promising alternative access for non-coronary intervention. Vascular access site complications are rarely clinically significant but nevertheless still a concern.

Keywords: Transradial access; Non-coronary intervention; Complication; Radial artery; Patency

Received 25 May 2020 | Revised 30 September 2020 | Accepted 5 October 2020

J Med Assoc Thai 2021;104(9): 1415-20

Website: <http://www.jmatonline.com>

Transradial access (TRA) for coronary angiography and intervention has an increasing popularity as many publications suggested lower rate of local vascular complications, shorter length of hospital stay, and more cost savings compared to transfemoral access (TFA)⁽¹⁻⁴⁾.

Recently, TRA has been applied for non-coronary interventions such as transarterial chemoembolization (TACE)⁽⁵⁻⁷⁾, selective internal radiation therapy (SIRT)⁽⁸⁾, uterine and prostatic artery embolization^(9,10), renal artery intervention⁽¹¹⁾, and other endovascular procedure^(12,13). Many published studies reported safety and feasibility of TRA and revealed better

patient satisfaction provided by TRA compared to TFA⁽¹⁴⁻¹⁶⁾.

The body interventional radiology unit, Ramathibodi Hospital has adopted TRA for some procedures since May 2018. The present study aimed to describe the authors' experience of TRA according to success and complications, particularly radial artery patency after TRA.

Materials and Methods

After being approved by the Ethical Committee of the study Institute (COA MURA 2019/527), a single-center retrospective analysis was done. The present study enrolled TRA cases performed in body interventional radiology unit, between May 2018 and January 2019. Every patient underwent pre-procedural ultrasonography to evaluate for radial artery size and verification of ulnopalmar arch patency using Barbeau test⁽¹⁷⁾ (Figure 1). The patients who had radial artery diameter less than 1.8 mm and Barbeau type D were excluded from transradial procedures.

TRA was done under local anesthesia. The radial artery was single-wall punctured with a 22-gauge Jelco needle under ultrasound (US) guidance. A 5-F radial vascular sheath (5-F Glidesheath slender,

Correspondence to:

Chansanti O.

Department of Diagnostic Radiology, Faculty of Medicine, Ramathibodi Hospital, Mahidol University, 270 Rama VI Road, Ratchathewi, Bangkok 10400, Thailand.

Phone: +66-2-2012465, Fax: +66-2-2011297

Email: orapin.chansanti@outlook.com

How to cite this article:

Chansanti O, Hengriprasopchoke S, Wedsart B, Treesit T, Bua-ngam C, Panpikoon T. Transradial Access for Non-Coronary Intervention: Initial Experience of Ramathibodi Hospital. J Med Assoc Thai 2021;104:1415-20.

doi.org/10.35755/jmedassocthai.2021.09.11439

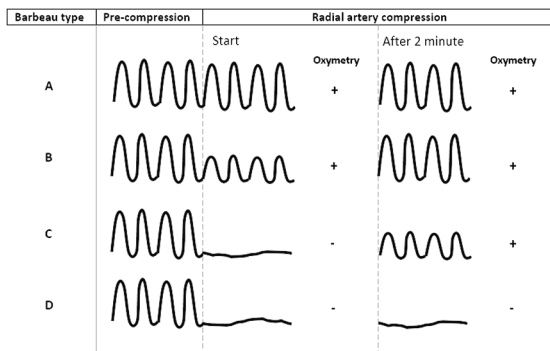


Figure 1. Barbeau classification of pulse waveform responses to compression of radial.

Terumo Corp., Japan or 5-F Prelude sheath introducer, Merit medical system, Inc., USA) was subsequently placed in modified Seldinger technique. Heparin 3,000 IU and NTG 200 to 300 µg were instilled intraarterially via the vascular sheath. A 5-F selective catheter was used to catheterize target vessels and a microcatheter was applied as necessary.

After completion of the procedure, the catheter and vascular sheath were removed. Hemostasis of the radial artery was achieved using pneumatic radial compression device (TR band radial compression device, Terumo Corp., Japan; PreludeSYNC radial compression device, Merit medical system, USA; Safeguard radial compression device, Merit medical system, USA) or manual compression. Doppler US was performed at 24-hour afterward to assess radial artery patency.

Statistical analysis

Categorical data were presented as number (percentage). Continuous data were reported as mean (standard deviation, SD) and median (range). Comparison between groups were done using chi-square (χ^2) test, Fisher's exact test, t-test, or Mann-Whitney U test as applicable. A p-value of less than 0.05 was considered statistically significant. Statistical analysis was conducted using PASW Statistics software, version 18.0 (SPSS Inc., Chicago, IL, USA).

Results

The patient's baseline characteristics are demonstrated in Table 1. Thirty-one cases from 27 patients of transradial procedures were collected during the studied period. TACE were accounted for 27 cases. The rest were splenic artery embolization with two cases, aortogram with femoral run-off

Table 1. Patient characteristics (n=31)

Characteristics	Value; n (%)
Age (year); mean±SD	64.9±9.1
Sex	
Male	20 (64.5)
Female	11 (35.4)
Weight (kg); mean±SD	70.5±19
Height (cm); mean±SD	159.5±120.2
BMI (kg/m ²); mean±SD	28.1±8.8
Procedure	
TACE	27 (87)
Others*	4 (12.9)
Prior TRA	
Naïve	25 (80.6)
≥1 time	6 (19.4)
Barbeau type	
A	3 (9.6)
B	20 (64.5)
C	8 (25.8)

SD=standard deviation; BMI=body mass index; TACE=transarterial chemoembolization; TRA=transradial access
* Splenic artery embolization, femoral run off, embolization for AVM

with one case, and right brachial angiogram and embolization for arteriovenous malformation at the right arm with one case. Reasons for considering TRA were thrombocytopenia in 17 cases (54%), morbid obesity with a BMI greater than 40 kg/m² in two cases, inability to select target vessel from transfemoral approach in four cases, and operator preference in six cases. One case of the TRA was performed for TACE in a patient with infrarenal abdominal aortic aneurysm (AAA) of 8.2 cm in diameter and the other one was performed for aortogram with femoral run-off in a patient who had aorto-iliac occlusive disease.

Pre-procedural evaluation showed mean radial artery diameter of 2.6 mm (SD 0.48). Most of the patients were allocated in Barbeau type B (64.5%). Almost all the cases performed TRA on the left radial artery except for the right brachial angiogram and embolization for AVM at the right arm, which radial artery was accessed on the right side. Six patients underwent repeated TRA for either TACE or splenic artery embolization. The radial artery was punctured to get access more than one attempt in seven cases. All procedures were successfully performed without crossover to TFA. Mean procedural time was 98 minutes (SD 38.1). Hemostasis was obtained by radial compression device in 27 cases (87.1%). The

Table 2. Analysis of radial artery patency

Parameter	Patent RA (n=27); n (%)	Occluded RA (n=4); n (%)	p-value
Age (year); mean±SD	63.9±7.8	72.0±14.8	0.354 [†]
Sex			0.115 [†]
Male	19 (61)	1 (3)	
Female	8 (26)	3 (10)	
Weight (kg); mean±SD	70.0±19.7	73.5±15.5	0.703 [†]
BMI (kg/m ²); mean±SD	27.6±9.1	31.6±6.1	0.306 [†]
Prior TRA			0.402 [†]
Naïve	21 (68)	4 (13)	
≥1 time	6 (19)	0 (0)	
Platelet count ×10 ³ ; median (IQR)	93 (41, 137)	118.5 (51.8, 260)	0.911 ^M
Barbeau type			1.0 ^x
A	3 (9)	0 (0)	
B	17 (55)	3 (10)	
C	7 (23)	1 (3)	
RA diameter (mm); mean±SD	2.58±0.51	2.7±0.29	0.665 [†]
Puncture attempt			0.253 ^x
1	21 (68)	3 (10)	
2	5 (16)	0 (0)	
3	1 (3)	1 (3)	
Procedural time (minute); mean±SD	92±30.8	133±65.9	0.303 [†]
Compression duration (minute); mean±SD	218±66.5	277±16.6	0.261 [†]
Compression method			0.137 ^x
<4 hours compression device	21 (68)	1 (3)	
>4 hours compression device	3 (10)	2 (6)	
Manual compression	3 (10)	1 (3)	

SD=standard deviation; IQR=interquartile range; BMI=body mass index; TRA=transradial access; RA=radial artery

[†] t-test; [†] Fisher's exact test; ^x Pearson chi-square; ^M Mann-Whitney test

other four cases received manual compression as a result of the too large size of the patient's wrist for the available compression device and the technical error while implementing the radial compression device.

Doppler US of the radial artery at 24-hour after the procedure detected asymptomatic radial artery occlusion (RAO) in four cases. Regarding statistical analysis, none of the present studied parameters showed statistically significant association with RAO. The detail are displayed in Table 2. All cases were managed conservatively. Complete recanalization was found at three weeks in one patient who had thrombocytopenia and received antiplatelet with aspirin 81 mg daily, due to her underlying medical condition. Two patients showed shorter length of the thrombus at 2-week follow-up US. The other patient was dropped out of the follow-up US owing to the change of treatment plan to palliative home care.

The other TRA-related complication found in the present study was radial artery pseudoaneurysm, which was demonstrated in two cases. The first case was noticed by US due to wrist swelling after removal of the radial compression device, measuring 3.3 mm in size, and was thrombosed after a 30-minute US-guided compression. The other case was detected at a month after the procedure on the US evaluation prior to the second transradial TACE. The lesion measured 5.7 mm in size. US-guided compression was done but failed to obliterate the pseudoaneurysm. TRA was repeatedly performed in this patient by puncture distal to the lesion. At 24-hour after the TRA, the pre-existing pseudoaneurysm was still seen. No new vascular complication was observed. However, a month after latest TRA, during US evaluation for the third transradial TACE, a new tiny pseudoaneurysm was detected, measuring

0.9 mm. The old pseudoaneurysm appeared to be slightly smaller in size, measuring 3.1 mm. Both lesions persisted after US-guided compression. Since the lesions had been small and asymptomatic, conservative management was employed.

Discussion

The present study presented an initial data regarding TRA for non-coronary intervention in the body interventional radiology unit.

Formerly, TFA has been routinely used for non-coronary procedure in the authors' unit. However, most cases were hepatocellular carcinoma patients that needed TACE. A portion of these patients had thrombocytopenia as their underlying disease were liver cirrhosis with portal hypertension and hypersplenism. Correction of platelet count to meet requirement for TFA has been problematic, then came the main reason for a change to transradial approach, which demanded for lower platelet threshold. Apart from thrombocytopenia, the rest of the reasons for choosing TRA were obesity, inability to select the target vessels from transfemoral approach, and operator preference.

Despite a technical success rate of 100% without crossover to TFA, there were concerning complications such as RAO and radial artery pseudoaneurysm (RAP).

Although RAO are mostly clinically silent due to dual circulation to the hand via palmar arch, the occlusion causes limitation for future access, particularly in the case of TACE, which repeating procedure might be necessary.

RAO after TRA is thought to be due to thrombotic process triggered by local endothelial damage and flow cessation in the radial artery⁽¹⁸⁾.

According to a systemic review and meta-analysis conducted by Rashid et al⁽¹⁹⁾, the incidence of RAO ranged between less than 1% to 33% and varied with timing of assessment, which was 7.7% within 24-hour and declining to 5.5% at one month. Furthermore, the study also suggested that RAO could be underestimated in consequence of detection methods with the absence of radial pulse versus US, since it observed the increased incidence of RAO from 5.6% to 7.8% when using the US.

As for the present study, RAO was found in four cases (12.9%), which was quite higher incidence than other studies performing TRA for non-coronary intervention^(5,6,16). The reason behind this could be due to early US screening protocol for radial artery patency at 24-hour in the authors' unit.

Several factors influencing RAO stated in the literatures were including age, gender, weight, diameter of radial artery, sheath to artery diameter, duration of compression, patent hemostasis, and anticoagulation⁽¹⁸⁻²¹⁾. However, none of the parameters in the present study exhibited statistically significant association with the RAO, which was probably due to a limited sample size.

In a published study on radial artery thrombosis following coronary angiography by Zankl et al⁽²²⁾, they concluded that treatment with low molecular weight heparin (LMWH) in symptomatic RAO significantly increased patency after four weeks. Still, all of RAO cases in the present study were treated conservatively without receiving anticoagulant because of being asymptomatic occlusion and risk of bleeding as one of the patients had ongoing bleeding wound at the right arm and the others had underlying liver cirrhosis with portal hypertension and thrombocytopenia. Thus, the role of anticoagulation therapy for RAO should be individualized. In addition, Barnett et al⁽²³⁾ suggested ipsilateral ulnar artery compression to increase blood flow in radial artery and improve recanalization of the occluded radial artery. Combining these measures might help restoration of radial artery patency.

Some methods are proposed to reduce rate of RAO such as higher dose of heparin⁽¹⁹⁾, patent hemostasis⁽²¹⁾, and prophylactic ulnar compression^(20,24). In a clinical study in TRA for hepatic chemoembolization by Yamada et al⁽¹⁶⁾ that included 52 procedures, Heparin 2,000 to 3,000 IU was administered through the vascular sheath immediately after sheath placement and additional 1,000 IU of heparin was given every 30 minutes. The authors found two cases of partial radial artery thrombosis on the US at the 30-day follow-up. These management are being considered to apply to the present study hospital setting to decrease rate of RAO, especially in the case of prolonged procedural time.

The other complication observed in the present study was radial artery pseudoaneurysm. The pseudoaneurysm needing closure was defined as a major vascular complication and 0.2% of incidence was reported⁽³⁾. The factors predisposing development of the pseudoaneurysm included multiple puncture attempts, systemic anticoagulation, inadequate hemostasis and post procedural compression, infection, and large sheath size⁽²⁵⁻²⁷⁾. US-guided compression, intralesional thrombin injection, or surgical repair are available treatment options.

During TRA of both authors' pseudoaneurysm cases, the radial artery was successfully punctured

under US guidance in one attempt.

In the first case, the pseudoaneurysm was found on the US performed due to wrist swelling following removal of the compression device. The color Doppler US showed direction of the flow projecting from lateral wall of the radial artery filling into the pseudoaneurysm. This finding produced possibility that the arterial puncture site was located laterally while the compression device was placed anteriorly on the arterial wall resulting in inadequate compression leading to pseudoaneurysm formation. However, the pseudoaneurysm was completely thrombosed after 30-minute US-guided compression with no recurrence on the US at 1-week follow-up.

In the second case, the pseudoaneurysms were not visualized at 24-hour post-procedural US but were incidentally detected on the pre-operative US evaluation for the next transradial procedure. The cause of delayed occurrence is uncertain. The hypothesis could be reopening of the small arterial tear or abnormality of the vessel wall.

Small sample size is a major limitation of the present study. Patients offered for TRA were not randomized, which subject to selection bias. Radiation exposure, patient satisfaction, and quality of life as well as cost-effectiveness comparing transradial and TFA were not documented in the present study.

Conclusion

The present study suggested TRA as a promising alternative access route for non-coronary intervention especially in patients who have limitations for TFA. Vascular complications at access site such as RAO and pseudoaneurysm are rarely clinically significant but nevertheless still in concern. Of note, the present study was an early report with small number of cases and limited experience of the transradial operators, long-term data is required.

What is already known on this topic?

Transradial access is well-established in coronary artery intervention and has been started in other body vascular intervention.

What this study adds?

1. Transradial access is an alternative approach for non-coronary vascular intervention with high success and low incidence for crossover to traditional transfemoral access.

2. Ultrasound doppler of radial artery performing immediate post-treatment provide an early detection of complication that may not show clinical sign.

Conflicts of interest

The authors declare no conflict of interest.

References

1. Mitchell MD, Hong JA, Lee BY, Umscheid CA, Bartsch SM, Don CW. Systematic review and cost-benefit analysis of radial artery access for coronary angiography and intervention. *Circ Cardiovasc Qual Outcomes* 2012;5:454-62.
2. Amin AP, House JA, Safley DM, Chhatrwalla AK, Giersiefen H, Bremer A, et al. Costs of transradial percutaneous coronary intervention. *JACC Cardiovasc Interv* 2013;6:827-34.
3. Jolly SS, Yusuf S, Cairns J, Niemelä K, Xavier D, Widimsky P, et al. Radial versus femoral access for coronary angiography and intervention in patients with acute coronary syndromes (RIVAL): a randomised, parallel group, multicentre trial. *Lancet* 2011;377:1409-20.
4. Romagnoli E, Biondi-Zoccai G, Sciahbasi A, Politi L, Rigattieri S, Pendenza G, et al. Radial versus femoral randomized investigation in ST-segment elevation acute coronary syndrome: the RIFLE-STEACS (Radial Versus Femoral Randomized Investigation in ST-Elevation Acute Coronary Syndrome) study. *J Am Coll Cardiol* 2012;60:2481-9.
5. El-Gharib M, Ali-Eldin ZA. Transradial approach for transarterial chemoembolization of hepatocellular carcinoma in Egyptian patients: Initial study. *Egypt J Radiol Nucl Med* 2016;47:833-7.
6. Posham R, Biederman DM, Patel RS, Kim E, Tabori NE, Nowakowski FS, et al. Transradial approach for noncoronary interventions: a single-center review of safety and feasibility in the first 1,500 cases. *J Vasc Interv Radiol* 2016;27:159-66.
7. Wu T, Sun R, Huang Y, Wang Z, Yin X, Zhu Z, et al. Transradial arterial chemoembolization reduces complications and costs in patients with hepatocellular carcinoma. *Indian J Cancer* 2015;52 Suppl 2:e107-11.
8. Kis B, Mills M, Hoffe SE. Hepatic radioembolization from transradial access: initial experience and comparison to transfemoral access. *Diagn Interv Radiol* 2016;22:444-9.
9. Bhatia S, Harward SH, Sinha VK, Narayanan G. Prostate artery embolization via transradial or transulnar versus transfemoral arterial access: technical results. *J Vasc Interv Radiol* 2017;28:898-905.
10. Resnick NJ, Kim E, Patel RS, Lookstein RA, Nowakowski FS, Fischman AM. Uterine artery embolization using a transradial approach: initial experience and technique. *J Vasc Interv Radiol* 2014;25:443-7.
11. Ruzsa Z, Tóth K, Jambrik Z, Kovács N, Nardai S, Nemes B, et al. Transradial access for renal artery intervention. *Interv Med Appl Sci* 2014;6:97-103.
12. Kumar AJ, Jones LE, Kollmeyer KR, Feldtman RW, Ferrara CA, Moe MN, et al. Radial artery access for

- peripheral endovascular procedures. *J Vasc Surg* 2017;66:820-5.
13. Meertens MM, Ng E, Loh SEK, Samuel M, Mees BME, Choong A. Transradial approach for aortoiliac and femoropopliteal interventions: a systematic review and meta-analysis. *J Endovasc Ther* 2018;25:599-607.
 14. Shiozawa S, Tsuchiya A, Endo S, Kato H, Katsube T, Kumazawa K, et al. Transradial approach for transcatheter arterial chemoembolization in patients with hepatocellular carcinoma: comparison with conventional transfemoral approach. *J Clin Gastroenterol* 2003;37:412-7.
 15. Iezzi R, Pompili M, Posa A, Annicchiarico E, Garcovich M, Merlino B, et al. Transradial versus transfemoral access for hepatic chemoembolization: inpatient prospective single-center study. *J Vasc Interv Radiol* 2017;28:1234-9.
 16. Yamada R, Bracewell S, Bassaco B, Camacho J, Anderson MB, Conrad A, et al. Transradial versus transfemoral arterial access in liver cancer embolization: randomized trial to assess patient satisfaction. *J Vasc Interv Radiol* 2018;29:38-43.
 17. Barbeau GR, Arsenault F, Dugas L, Simard S, Larivière MM. Evaluation of the ulnopalmar arterial arches with pulse oximetry and plethysmography: comparison with the Allen's test in 1010 patients. *Am Heart J* 2004;147:489-93.
 18. Kotowycz MA, Dzavik V. Radial artery patency after transradial catheterization. *Circ Cardiovasc Interv* 2012;5:127-33.
 19. Rashid M, Kwok CS, Pancholy S, Chugh S, Kedev SA, Bernat I, et al. Radial artery occlusion after transradial interventions: a systematic review and meta-analysis. *J Am Heart Assoc* 2016;5:e002686.
 20. Mason PJ, Shah B, Tamis-Holland JE, Bittl JA, Cohen MG, Safirstein J, et al. An update on radial artery access and best practices for transradial coronary angiography and intervention in acute coronary syndrome: a scientific statement from the American Heart Association. *Circ Cardiovasc Interv* 2018;11:e000035.
 21. Pancholy S, Coppola J, Patel T, Roke-Thomas M. Prevention of radial artery occlusion-patent hemostasis evaluation trial (PROPHET study): a randomized comparison of traditional versus patency documented hemostasis after transradial catheterization. *Catheter Cardiovasc Interv* 2008;72:335-40.
 22. Zankl AR, Andrassy M, Volz C, Ivandic B, Krumsdorf U, Katus HA, et al. Radial artery thrombosis following transradial coronary angiography: incidence and rationale for treatment of symptomatic patients with low-molecular-weight heparins. *Clin Res Cardiol* 2010;99:841-7.
 23. Bernat I, Bertrand OF, Rokyta R, Kacer M, Pesek J, Koza J, et al. Efficacy and safety of transient ulnar artery compression to recanalize acute radial artery occlusion after transradial catheterization. *Am J Cardiol* 2011;107:1698-701.
 24. Pancholy SB, Bernat I, Bertrand OF, Patel TM. Prevention of radial artery occlusion after transradial catheterization: The PROPHET-II randomized trial. *JACC Cardiovasc Interv* 2016;9:1992-9.
 25. Collins N, Wainstein R, Ward M, Bhagwandeem R, Dzavik V. Pseudoaneurysm after transradial cardiac catheterization: case series and review of the literature. *Catheter Cardiovasc Interv* 2012;80:283-7.
 26. Hamid T, Harper L, McDonald J. Radial artery pseudoaneurysm following coronary angiography in two octogenarians. *Exp Clin Cardiol* 2012;17:260-2.
 27. Kanei Y, Kwan T, Nakra NC, Liou M, Huang Y, Vales LL, et al. Transradial cardiac catheterization: a review of access site complications. *Catheter Cardiovasc Interv* 2011;78:840-6.