

# Schizencephaly in Children: Clinical Features and Associated Findings

Wongnate J, MD<sup>1</sup>, Danchaivijitr N, MD<sup>2</sup>, Likasitwattanakul S, MD<sup>1</sup>

<sup>1</sup> Department of Pediatrics, Faculty of Medicine Siriraj Hospital, Mahidol University, Bangkok, Thailand

<sup>2</sup> Department of Radiology, Faculty of Medicine Siriraj Hospital, Mahidol University, Bangkok, Thailand

**Objective:** To evaluate clinical features and associated findings of schizencephaly in children.

**Materials and Methods:** Children with a diagnosis of schizencephaly aged less than 15 years between January 2005 and December 2015 were retrospectively reviewed. Demographic data, age at the onset, clinical features, and associated central nervous system (CNS) malformation were reviewed, retrieved, and recorded into a standard case record form.

**Results:** Seventy-five patients were included in the present study. Bilateral open-lip schizencephaly was the most common type and found in 35 patients (46.7%), followed by unilateral open-lip in 21 patients (28%), and unilateral closed-lip schizencephaly in 10 patients (13.3%). The most common clinical features of schizencephaly were motor disability (92%), other developmental disability (86.7%), and epilepsy (45.3%). Bilateral open-lip schizencephaly has the worst overall outcome in terms of motor deficits, other developmental disability, and epilepsy. Associated CNS findings were absent of septum pellucidum (ASP) in 60/75 (80%), optic nerve hypoplasia (ONH) in 32/63 (50.8%), septo-optic dysplasia (SOD) in 33/75 (44%), and pituitary hormone abnormalities in 12/49 (24.5%).

**Conclusion:** There are wide varieties of clinical manifestations in patients with schizencephaly. Since association with SOD is found in up to 44% in these patients, the authors recommend that if schizencephaly was found on neuroimaging study, other associated CNS abnormalities such as ASP and dysgenesis of corpus callosum should be looked for. If SOD was considered, a formal ophthalmologic evaluation for ONH and pituitary hormone evaluation are necessary to treat these patients appropriately.

**Keywords:** Schizencephaly, Clinical features, Associated findings, SOD

Received 11 Jun 2018 | Revised 23 Dec 2019 | Accepted 26 Dec 2019

**J Med Assoc Thai 2020;103(1):14-21**

**Website:** <http://www.jmatonline.com>

Schizencephaly is a rare congenital central nervous system (CNS) malformation with a prevalence of approximately 1.5:100,000 population<sup>(1,2)</sup>. It is characterized by gray matter-lined clefts extending from the pial surface to the cerebral hemispheres<sup>(3)</sup>. The cleft is most commonly found in the perisylvian areas<sup>(4)</sup> and lined by abnormal cortical lining most commonly in the form of polymicrogyria<sup>(5)</sup>. It was first described and classified in to two types, closed, when

there is no communication of the cleft to the ventricle, and open lip, when the cleft connects to ventricle with the subarachnoid space<sup>(6,7)</sup>. Schizencephaly can occur unilaterally or bilaterally in any hemispheric regions<sup>(8)</sup>.

It is classified in the group of malformation secondary to abnormal post-migrational development<sup>(9)</sup>. The exact cause of schizencephaly is still unknown. One of the potential causes of schizencephaly is vascular disruption<sup>(9-11)</sup>. Non-CNS abnormalities were also found in these patients due to vascular disruption such as gastroschisis, bowel atresia, and amniotic band syndrome<sup>(9)</sup>. Some authors found association with congenital cytomegalovirus (CMV) infection<sup>(12)</sup>. Some authors report EMX2 gene<sup>(13)</sup> as a potential cause of schizencephaly, but more studies suggested that this gene is not a common cause of this defect<sup>(14)</sup>.

## Correspondence to:

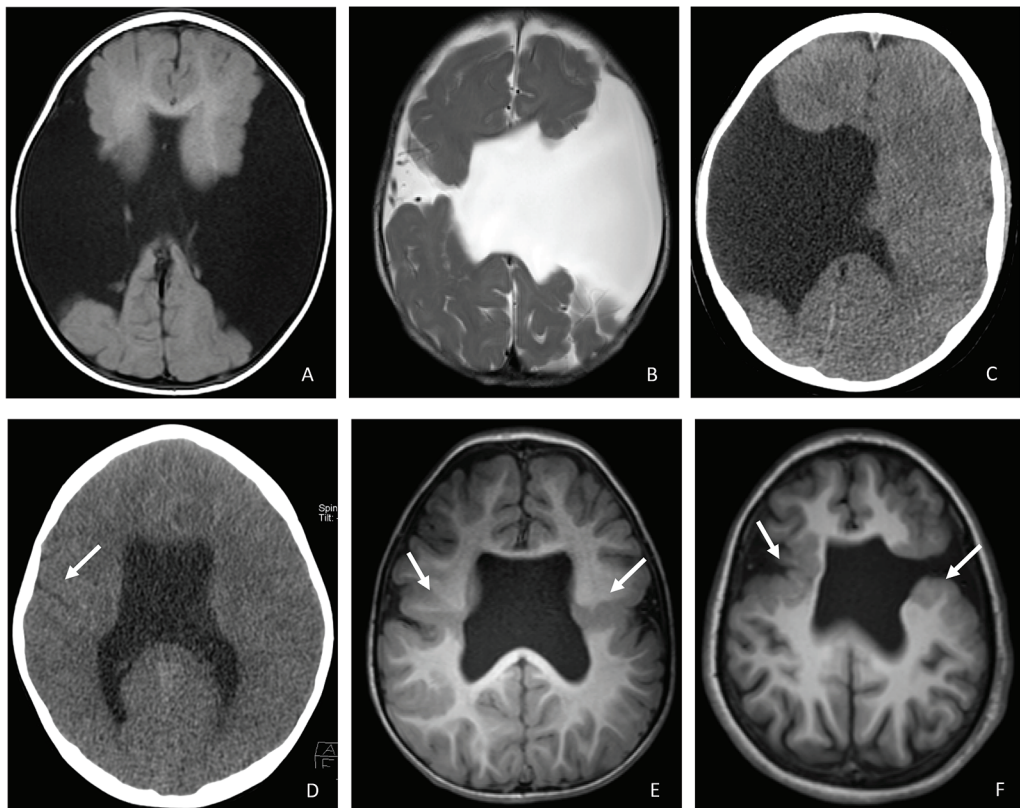
Likasitwattanakul S.

Division of Neurology, Department of Pediatrics, Faculty of Medicine Siriraj Hospital, Mahidol University, 2 Wang Lang Road, Bangkokknoi, Bangkok 10700, Thailand.

**Phone:** +66-2-4195890, **Fax:** +66-2-4192238

**Email:** [surachai.lik@mahidol.ac.th](mailto:surachai.lik@mahidol.ac.th)

**How to cite this article:** Wongnate J, Danchaivijitr N, Likasitwattanakul S. Schizencephaly in Children: Clinical Features and Associated Findings. J Med Assoc Thai 2020;103:14-21.



**Figure 1.** Neuroimaging abnormalities in different types of schizencephaly. (A) Axial T1-weighted MRI shows large, bilateral open-lip schizencephaly. (B) Axial T2-weighted MRI shows bilateral open-lip schizencephaly, large on the left, small on the right side. (C) Axial CT shows unilateral open-lip schizencephaly on the right with agenesis of septum pellucidum (D) Axial CT show unilateral closed-lip schizencephaly on the right (arrowhead) with agenesis of septum pellucidum. (E) Axial T1-weighted MRI shows bilateral closed-lip schizencephaly lined with polymicrogyria (arrowhead) with agenesis of septum pellucidum. (F) Axial T1-weighted MRI shows bilateral schizencephaly, closed-lip on the right side and open-lip on the left side and agenesis of septum pellucidum. Polymicrogyrias are found along the clefts (arrowhead).

Schizencephaly is associated with septo-optic dysplasia (SOD)<sup>(15,16)</sup>, which can be diagnosed when a patient has two or more features of 1) optic nerve hypoplasia (ONH), 2) pituitary hormone abnormalities, and 3) midline brain defects, including agenesis of the septum pellucidum or corpus callosum<sup>(17)</sup>.

Clinical features of schizencephaly vary widely ranging from developmental delay, microcephaly, hydrocephalus, spasticity, epilepsy, endocrine abnormalities in the hypothalamus-pituitary-adrenal (HPA) axis, and visual abnormality<sup>(10,18,19)</sup>.

The aim of the present study was to evaluate clinical features and associated findings of schizencephaly in children at Siriraj Hospital, a major tertiary referral center in Thailand.

### Materials and Methods

A retrospective medical chart review was performed on all patients, aged less than 15 years,

diagnosed with schizencephaly in pediatric neurology clinic at Siriraj Hospital between January 2005 and December 2015 study period. The authors identified from a hospital database by using the International Classification of Disease, Tenth revision (ICD-10) code of congenital cerebral cyst (Q04.6). The protocol of the present study was approved by the Siriraj Institutional Review Board, Faculty of Medicine Siriraj Hospital, Mahidol University, Bangkok, Thailand (278/2559).

The diagnosis was made by the presence of schizencephaly by cranial computed tomography (CCT) or brain magnetic resonance imaging (BMRI). The patients were classified into open-lip or closed-lip and were further sub-classified into unilateral or bilateral schizencephaly. Demographic data, time at diagnosis, clinical features, and associated CNS malformation were reviewed, retrieved, and recorded into a standard case record form. Motor

**Table 1.** Demographic data and clinical features of 75 patients with schizencephaly

	Schizencephaly (n=75) n (%)
Sex (male:female)	45:30
Time at diagnosis	
Prenatal	19 (25.3)
Post-natal (months)	
• Median (range)	9.9 (1 to 111)
• Mean±SD	20.6±25.9
Clinical features	
Motor disability	69 (92.0)
• Hemiparesis	24 (32.0)
• Quadriparesis	45 (60.0)
Developmental disability (other than motor)	65 (86.7)
Epilepsy	34 (45.3)
• Intractable seizure	18 (52.9)
Nystagmus (n=63)	23 (36.5)
Microcephaly	34 (45.3)
Macrocephaly	14 (18.7)
Hydrocephalus	12 (16.0)
Types of schizencephaly	
Unilateral	31 (41.3)
• Closed	10 (13.3)
• Open	21 (28.0)
Bilateral	44 (58.7)
• Closed	3 (4.0)
• Open	35 (46.7)
• Open and closed	6 (8.0)

SD=standard deviation

impairment were classified as normal, hemiparesis, or quadriparesis. Other developmental disability was defined when the patient had abnormal mental neurodevelopmental and language abnormalities. ONH was diagnosed by ophthalmologist. Pituitary hormone abnormalities were performed and interpreted by pediatric endocrinologists. Pituitary hormone tests included thyroid function test, adrenocorticotrophic hormone stimulation test, and water deprivation test. Neuroimaging studies were reviewed by the neuroradiologist (Danchaivijitra N) who was unaware of the clinical features. SOD was diagnosed when the patients had two or more features of 1) ONH, 2) pituitary hormone abnormalities, and 3) midline brain defects, including agenesis of the septum pellucidum or corpus callosum<sup>(17)</sup>.

### Statistical analysis

The authors used IBM SPSS Statistics software, version 21.0 (IBM Corp., Armonk, NY, USA) to perform all statistical calculations to analyze the data. Patient characteristics were summarized by using descriptive statistics of all variables were obtained a median (range) or frequency (percentage). The chi-square test was used to determine the association between outcomes and the factors that associated with the outcomes. A p-value of less than 0.05 was considered statistically significant.

### Results

During study period, 75 patients were found to have schizencephaly. Demographic, clinical features, and types of schizencephaly are shown in Table 1. Of the 75 patients, 58 had CCT, 15 had BMRI, and two had both CCT and BMRI as neuroimaging studies.

The most common clinical features of schizencephaly were motor disability (92%), other developmental disability (86.7%), and epilepsy (45.3%). Of the 63 patients with a formal ophthalmologic examination, 23 patients (36.5%) have nystagmus.

Bilateral open-lip schizencephaly was the most common type and found in 35 patients (46.7%), followed by unilateral open-lip in 21 patients (28%), and unilateral closed-lip schizencephaly in 10 patients (13.3%). Examples of each type of schizencephaly are shown in Figure 1.

Table 2 shows the associated findings among different types of schizencephaly. The absent of septum pellucidum (ASP) was found in 60 patients (80%). ONH was found in 33/63 patients (50.8%). Pituitary hormone evaluations were obtained in 49 patients, 12 (24.5%) had abnormalities. Of these, six patients had multiple hormone deficiencies and six had single hormonal deficiency. Overall hormonal abnormalities were as followed, central hypothyroid in seven, adrenal insufficiency in six, and diabetes insipidus in eight patients. SOD was diagnosed in 33 patients (44%).

Different clinical features between bilateral and unilateral schizencephaly are shown in Table 3. Patients with bilateral schizencephaly had significantly more motor deficits ( $p=0.004$ ), quadriparesis ( $p<0.001$ ), other developmental disability ( $p=0.001$ ), epilepsy ( $p=0.02$ ), nystagmus ( $p=0.004$ ), and associated with ASP ( $p=0.008$ ) than unilateral schizencephaly. Hemiparesis was more common in unilateral schizencephaly ( $p<0.001$ ). Hydrocephalus were only seen in patients with bilateral schizencephaly, and

**Table 2.** Associated findings among different types of schizencephaly

	No. of positive findings/No. tested (%)			
	ASP	ONH	SOD	Pituitary hormone abnormalities
Bilateral open lip	34/35 (97.1)	16/30 (53.3)	17/35 (48.5)	6/26 (23.0)
Unilateral open lip	13/21 (61.9)	7/15 (46.6)	7/21 (33.3)	1/12 (8.3)
Unilateral closed lip	7/10 (70.0)	5/9 (55.5)	5/10 (50.0)	3/6 (50.0)
Bilateral closed & open lip	4/6 (66.6)	3/6 (50.0)	3/6 (50.0)	2/4 (50.0)
Bilateral closed lip	2/3 (66.6)	1/3 (33.3)	1/3 (33.3)	0/1 (0.0)
Total	60/75 (80.0)	32/63 (50.8)	33/75 (44.0)	12/49 (24.5)

ASP=absent septum pellucidum; ONH=optic nerve hypoplasia; SOD=septo-optic dysplasia

**Table 3.** Comparison of clinical features of bilateral and unilateral schizencephaly

	Bilateral schizencephaly (n=44) n (%)	Unilateral schizencephaly (n=31) n (%)	p-value
Clinical features			
Motor disability	44 (100)	25 (80.6)	0.004
• Hemiparesis	5 (11.4)	19 (61.3)	<0.001
• Quadriparesis	39 (88.6)	6 (19.4)	<0.001
Developmental disability (other than motor)	43 (97.7)	22 (71.0)	0.001
Epilepsy	25 (56.8)	9 (29.0)	0.020
• Intractable seizure	14 (56.0)	4 (44.4)	0.098
Visual problem			
• Nystagmus	14/42 (33.3)	9/21 (42.9)	0.004
Microcephaly	20 (45.5)	14 (45.3)	1.000
Macrocephaly	12 (27.3)	2 (6.5)	0.051
Hydrocephalus	12 (27.3)	0 (0.0)	0.003
Aggenesis of septum pellucidum	40 (90.9)	20 (64.5)	0.008
Optic nerve hypoplasia	20/39 (51.3)	12/24 (50.0)	0.492
Pituitary hormone abnormalities	8/31 (25.8)	4/18 (22.2)	0.567
Septo-optic dysplasia	21 (47.7)	12 (38.7)	0.486

all underwent ventriculoperitoneal shunt insertion. SOD was diagnosed more frequently in bilateral schizencephaly (47.7% versus 38.7%,  $p=0.48$ ).

Table 4 shows the clinical features between open- and closed-lip schizencephaly. Patients with open-lip schizencephaly had significant more motor deficits ( $p=0.001$ ), quadriparesis ( $p<0.001$ ), other developmental disability ( $p=0.009$ ), and epilepsy ( $p=0.03$ ) than closed-lip schizencephaly. Hemiparesis was more common in closed-lip schizencephaly ( $p<0.001$ ).

Table 5 shows the difference of clinical features the most common types of schizencephaly. Bilateral open-lip schizencephaly are the most severe form having more motor deficits (quadriparesis), other

developmental disabilities epilepsy, nystagmus, hydrocephalus than the other two types of schizencephaly.

## Discussion

The authors retrospectively reviewed clinical features of 75 patients who had schizencephaly at a tertiary care hospital in Thailand. Types of schizencephaly vary among studies. Unilateral schizencephaly are more frequent in most studies<sup>(8,15,20)</sup>. However, one study showed equal number among unilateral and bilateral<sup>(18)</sup>. The most common form of the present study was bilateral schizencephaly, similar to another report<sup>(10)</sup>. The most common clinical features were motor deficits, developmental

**Table 4.** Comparison of clinical features of open-lip and closed-lip schizencephaly

	Open-lip schizencephaly (n=56) n (%)	Close-lip schizencephaly (n=13) n (%)	p-value
Clinical features			
Motor disability	55 (98.2)	8 (61.5)	0.001
• Hemiparesis	15 (26.8)	6 (46.2)	<0.001
• Quadriparesis	40 (71.4)	2 (15.4)	<0.001
Developmental disability (other than motor)	52 (92.9)	8 (61.5)	0.009
Epilepsy	29 (51.8)	2 (15.4)	0.03
• Intractable seizure	16 (55.2)	1 (50.0)	0.16
Visual problem			
• Nystagmus	17/45 (37.8)	4/12 (33.3)	0.65
Microcephaly	28 (50.0)	3 (23.1)	0.15
Macrocephaly	13 (23.2)	0 (0.0)	0.08
Hydrocephalus	12 (21.4)	0 (0.0)	0.10
Agenesis of septum pellucidum	47 (83.9)	9 (69.2)	0.32
Optic nerve hypoplasia	23/45 (51.1)	6/12 (50)	0.62
Pituitary hormone abnormalities	7/38 (18.4)	3/7 (42.9)	0.33
Septo-optic dysplasia	24 (42.9)	6 (46.2)	1.000

**Table 5.** Comparison of clinical feature of bilateral open-, unilateral open- and unilateral closed-lip schizencephaly

	Bilateral open-lip schizencephaly (n=35) n (%)	Unilateral open-lip schizencephaly (n=21) n (%)	Unilateral closed-lip schizencephaly (n=10) n (%)
Clinical features			
Motor disability	35 (100)	21 (100)	5 (50.0)
• Hemiparesis	1 (2.9)	14 (66.6)	5 (50.0)
• Quadriparesis	34 (97.1)	7 (33.3)	0 (0.0)
Developmental disability (other than motor)	35 (100)	17 (80.9)	5 (50.0)
Epilepsy	22 (62.9)	7 (33.3)	2 (20.0)
• Intractable seizure	13 (37.1)	3 (14.2)	1 (10.0)
Nystagmus	12/33 (36.4)	5/12 (41.7)	4/9 (44.4)
Microcephaly	16 (45.7)	12 (57.1)	2 (20.0)
Macrocephaly	11 (31.4)	3 (14.2)	0 (0.0)
Hydrocephalus	12 (34.3)	0 (0.0)	0 (0.0)
Agenesis of septum pellucidum	34 (97.1)	14 (66.6)	7 (70.0)
Optic nerve hypoplasia	16/30 (53.3)	7/15 (46.7)	5/9 (55.6)
Pituitary hormone abnormalities	6/26 (23.1)	1/12 (8.3)	3/6 (50.0)
Septo-optic dysplasia	17 (48.6)	7 (33.3)	5 (50.0)

disabilities, and epilepsies, which are similar to other studies<sup>(10,15,18,19)</sup>.

Motor deficits are the most common clinical features of schizencephaly. Motor deficits correlate with the involvement of the frontal lobes and the size of the clefts<sup>(8)</sup>. Most cases have clinical correlations,

quadriparesis in bilateral open and hemiparesis in unilateral open- or closed-lip schizencephaly. However, some have atypical correlation. Some patients with unilateral schizencephaly in the present study have quadriparesis, which may be explained by contralateral cortical dysplasia that may have not

been detected by CCT<sup>(4)</sup>. Five patients out of ten in the present study with closed-lip schizencephaly had a small cleft at the parietal area and did not have any weakness on examination.

The present study showed that other developmental disability (cognitive and language skills) were more severe in bilateral schizencephaly, especially in bilateral open-lip schizencephaly. The severity of the clinical features among these patients are claimed to be related to the amount of the involved brain<sup>(3,18,21)</sup>. These observations confirm this assumption.

Epilepsies were found in 36% to 65% of the patients and 9% to 38% of these patients were refractory to antiepileptic drugs<sup>(8,18-20)</sup>. In the present study, 34 patients (45.3%) had epilepsy and 18 (52.9%) were refractory to antiepileptic drugs.

Concomitant congenital defects among patients with schizencephaly are ASP, corpus callosum dysgenesis, and polymicrogyria<sup>(4,8,15,18,20-23)</sup>. ASP is found in approximately 70% of the patients (ranges from 43% to 75%)<sup>(3,18,23,24)</sup>. ASP is almost always absent with bilateral schizencephaly at the frontal areas<sup>(23)</sup>. ASP is found in 60 patients (80%) in the present study and found in 97.1% in bilateral open-lip schizencephaly (one has partial ASP). Polymicrogyria was identified in 46% along the clefts and 66% in other parts of cerebral hemispheres. It can be found in 29% in the contralateral hemisphere in a location symmetrical to the clefts<sup>(25)</sup>. Corpus callosum dysgenesis and polymicrogyria are found in 30%<sup>(4)</sup>. These findings suggest a widespread developmental disorders in most cases<sup>(4)</sup>. As most of the neuroimaging method in the present study were CCT, it is very difficult to evaluate the concomitant findings of polymicrogyria or dysgenesis of corpus callosum in these patients.

ONH was found in half of the patients who had a formal examination by pediatric ophthalmologists. Twelve out of 49 patients (24.5%) who had pituitary hormone test performed had abnormal results. Twelve out of 33 patients (36.4%) with SOD had abnormal pituitary hormone abnormalities that required treatments. Six patients had combined hormonal deficiencies and six had single hormone deficiency.

Another important concomitant finding associated with schizencephaly is SOD. SOD is a rare congenital developmental disorder with agenesis of septum pellucidum, ONH, and endocrine abnormalities, which has been found to be associated with patients with cortical malformation including schizencephaly<sup>(16,26-28)</sup>. Recently, SOD is classified

into three types, classic SOD (septum pellucidum or corpus callosum abnormalities with either ONH or pituitary dysfunction without cortical malformation), SOD-like (ONH and pituitary dysfunction without septum pellucidum or corpus callosum abnormalities or cortical malformation), and SOD-plus with cortical malformation<sup>(16,29)</sup>. Schizencephaly is consistently reported in patients with SOD-plus<sup>(16,26,28,30)</sup>. Other CNS malformations are polymicrogyria and transmantal cortical dysplasia<sup>(16,28)</sup>.

In the present study, 33 patients (44%) reached the diagnostic criteria for SOD and were further classified to SOD-plus group. In a recent report, SOD-plus is the most common subclass in SOD and polymicrogyria and schizencephaly are the most common cortical malformations<sup>(28)</sup>. In this series, both unilateral and bilateral schizencephaly are found in SOD-plus group<sup>(28)</sup>. SOD is found in 50% among patients with unilateral closed-lip (5/10) and bilateral closed and open-lip schizencephaly (3/6), and 33.3% in unilateral open (7/21), and bilateral closed-lip (1/3).

Schizencephaly is generally accepted as abnormal CNS development during post-migrational development at or before the sixth week of gestation<sup>(9)</sup>, the same time that development of eyes and the laminar terminalis occurs<sup>(22,30)</sup>. As septum pellucidum, corpus callosum, and the anterior commissure are derived from the embryonic laminar terminalis, a structure that borders the area of the developing optic structures, hypothalamus, and septal nuclei, this suggests that some patients with schizencephaly have wide spread developmental defects of the developing CNS and possibly time specific<sup>(30)</sup>.

There are several mentionable limitations in the present studies. First, giving the retrospective design, some data may be missing or incomplete, and some of the patients did not have a complete ophthalmologic or hormonal investigation. Second, most of the neuroimaging studies in the present study is CCT, thus identifying closed lip schizencephaly and other CNS malformation such as cortical dysplasia may be missing. However, the present study showed that clinical features of these patients are not different from other studies.

## Conclusion

The present study revealed that there are varieties of clinical features of schizencephaly. The most common clinical features are motor deficits, developmental disabilities, and epilepsy. Once schizencephaly is found on neuroimaging study. The physician should also look for other associated CNS

malformations such as agenesis of septum pellucidum, polymicrogyria, and dysgenesis of corpus callosum. The present study emphasizes that these patients should have further ophthalmologic and pituitary hormonal evaluation since SOD may be associated with these patients in up to 44%.

### What is already known on this topic?

Schizencephaly is a rare congenital CNS malformation. Clinical features of these patients are variable. Most of the previous studies emphasized mainly on clinical features and associated findings on neuroimaging studies such as agenesis of septum pellucidum and focal cortical dysplasia.

### What this study adds?

This study has a significant number of patients with schizencephaly. When analyzing the presence of associated finding along with pituitary hormone abnormalities all together, the authors found up to 44% of these patients also have SOD. Some of these patients required hormonal therapy in addition to symptomatic treatment. Thus, the authors emphasize to the physicians to actively look for the association between schizencephaly and SOD.

### Acknowledgement

The present study was supported by a grant from the Siriraj Research Development Fund (R015931075). Danchaivijitr N and Likasitwattanakul S were supported by the Chalermprakit Grant, Faculty of Medicine Siriraj Hospital, Mahidol University, Bangkok, Thailand.

### Conflicts of interest

The authors declare no conflicts of interest in relation to this research and its publication of this article.

### References

1. Curry CJ, Lammer EJ, Nelson V, Shaw GM. Schizencephaly: heterogeneous etiologies in a population of 4 million California births. *Am J Med Genet A* 2005;137:181-9.
2. Howe DT, Rankin J, Draper ES. Schizencephaly prevalence, prenatal diagnosis and clues to etiology: a register-based study. *Ultrasound Obstet Gynecol* 2012;39:75-82.
3. Barkovich AJ, Raybaud C. Congenital malformations of the brain and skull. In: Barkovich AJ, Raybaud C, editors. *Pediatric neuroimaging*. 5th ed. Philadelphia: Wolter Kluwer/Lippincott Williams & Wilkins; 2012. p. 367-568.
4. Granata T, Freri E, Caccia C, Setola V, Taroni F, Battaglia G. Schizencephaly: clinical spectrum, epilepsy, and pathogenesis. *J Child Neurol* 2005;20:313-8.
5. Guerrini R, Dobyns WB. Malformations of cortical development: clinical features and genetic causes. *Lancet Neurol* 2014;13:710-26.
6. Yakovlev PI, Wadsworth RC. Schizencephalies; a study of the congenital clefts in the cerebral mantle; clefts with hydrocephalus and lips separated. *J Neuropathol Exp Neurol* 1946;5:169-206.
7. Yakovlev PI, Wadsworth RC. Schizencephalies; a study of the congenital clefts in the cerebral mantle; clefts with fused lips. *J Neuropathol Exp Neurol* 1946;5:116-30.
8. Barkovich AJ, Kjos BO. Schizencephaly: correlation of clinical findings with MR characteristics. *AJNR Am J Neuroradiol* 1992;13:85-94.
9. Barkovich AJ, Guerrini R, Kuzniecky RI, Jackson GD, Dobyns WB. A developmental and genetic classification for malformations of cortical development: update 2012. *Brain* 2012;135:1348-69.
10. Kopyta I, Jamroz E, Kluczevska E, Sarecka-Hujar B. Clinical and radiologic features of unilateral and bilateral schizencephaly in polish pediatric patients. *J Child Neurol* 2014;29:442-9.
11. Landrieu P, Lacroix C. Schizencephaly, consequence of a developmental vasculopathy? A clinicopathological report. *Clin Neuropathol* 1994;13:192-6.
12. Iannetti P, Nigro G, Spalice A, Faiella A, Boncinelli E. Cytomegalovirus infection and schizencephaly: case reports. *Ann Neurol* 1998;43:123-7.
13. Faiella A, Brunelli S, Granata T, D'Incerti L, Cardini R, Lenti C, et al. A number of schizencephaly patients including 2 brothers are heterozygous for germline mutations in the homeobox gene EMX2. *Eur J Hum Genet* 1997;5:186-90.
14. Tietjen I, Bodell A, Apse K, Mendonza AM, Chang BS, Shaw GM, et al. Comprehensive EMX2 genotyping of a large schizencephaly case series. *Am J Med Genet A* 2007;143A:1313-6.
15. Maeda T, Akaishi M, Shimizu M, Sekiguchi K, Anan A, Takano T, et al. The subclassification of schizencephaly and its clinical characterization. *Brain Dev* 2009;31:694-701.
16. Miller SP, Shevell MI, Patenaude Y, Poulin C, O'Gorman AM. Septo-optic dysplasia plus: a spectrum of malformations of cortical development. *Neurology* 2000;54:1701-3.
17. Kelberman D, Dattani MT. Septo-optic dysplasia - novel insights into the aetiology. *Horm Res* 2008;69:257-65.
18. Denis D, Chateil JF, Brun M, Brissaud O, Lacombe D, Fontan D, et al. Schizencephaly: clinical and imaging features in 30 infantile cases. *Brain Dev* 2000;22:475-83.
19. Lopes CF, Cendes F, Piovesana AM, Torres F, Lopes-Cendes I, Montenegro MA, et al. Epileptic features of patients with unilateral and bilateral schizencephaly.

- J Child Neurol 2006;21:757-60.
20. Packard AM, Miller VS, Delgado MR. Schizencephaly: correlations of clinical and radiologic features. *Neurology* 1997;48:1427-34.
  21. Liang JS, Lee WT, Peng SS, Yu TW, Shen YZ. Schizencephaly: correlation between clinical and neuroimaging features. *Acta Paediatr Taiwan* 2002; 43:208-13.
  22. Miller GM, Stears JC, Guggenheim MA, Wilkening GN. Schizencephaly: a clinical and CT study. *Neurology* 1984;34:997-1001.
  23. Raybaud C, Girard N, Levrier O, Peretti-Viton P, Manera L, Farnarier P. Schizencephaly: correlation between the lobar topography of the cleft(s) and absence of the septum pellucidum. *Childs Nerv Syst* 2001;17:217-22.
  24. Barkovich AJ, Norman D. Absence of the septum pellucidum: a useful sign in the diagnosis of congenital brain malformations. *AJR Am J Roentgenol* 1989;152:353-60.
  25. Hayashi N, Tsutsumi Y, Barkovich AJ. Morphological features and associated anomalies of schizencephaly in the clinical population: detailed analysis of MR images. *Neuroradiology* 2002;44:418-27.
  26. Barkovich AJ, Fram EK, Norman D. Septo-optic dysplasia: MR imaging. *Radiology* 1989;171:189-92.
  27. Polizzi A, Pavone P, Iannetti P, Manfre L, Ruggieri M. Septo-optic dysplasia complex: a heterogeneous malformation syndrome. *Pediatr Neurol* 2006;34: 66-71.
  28. Alt C, Shevell MI, Poulin C, Rosenblatt B, Saint-Martin C, Srour M. Clinical and Radiologic Spectrum of Septo-optic Dysplasia: Review of 17 Cases. *J Child Neurol* 2017;32:797-803.
  29. Nagasaki K, Kubota T, Kobayashi H, Sawada H, Numakura C, Harada S, et al. Clinical characteristics of septo-optic dysplasia accompanied by congenital central hypothyroidism in Japan. *Clin Pediatr Endocrinol* 2017;26:207-13.
  30. Kuban KC, Teele RL, Wallman J. Septo-optic-dysplasia-schizencephaly. Radiographic and clinical features. *Pediatr Radiol* 1989;19:145-50.