

# Cytomorphologic and Clinical Factors of Having High-Grade Cervical Intraepithelial Neoplasia/Invasive Carcinoma in Women with Atypical Squamous Cells, Cannot Exclude High-Grade Squamous Intraepithelial Lesion (ASC-H) Smears

Thiti Atjimakul MD\*, Sathana Boonyapipat MD\*,  
Saibua Chichareon MD\*, Monlika Phukaoloun MD\*\*

\*Department of Obstetrics and Gynecology, Faculty of Medicine, Prince of Songkla University, Hat Yai, Songkhla, Thailand

\*\* Department of Pathology, Faculty of Medicine, Prince of Songkla University, Hat Yai, Songkhla, Thailand

**Objective:** To determine the predictors for high-grade cervical intraepithelial neoplasia (CIN)/invasive carcinoma in women with atypical squamous cells, cannot exclude the high-grade squamous intraepithelial lesion (ASC-H) smears.

**Material and Method:** All women with ASC-H, who underwent colposcopy and had histopathologic diagnosis between January 2004 and December 2011, were recruited. Clinical and cytomorphologic features were correlated with final histological diagnosis. Univariate and multivariate analysis were used to determine predicting factors for high-grade CIN/invasive cancer.

**Results:** Among 136,638 smears performed, 193 (0.14%) smears were reported as ASC-H and 121 smears were available for review. The underlying pathology were negative/reactive (N/R) 57 (47.1%), CIN 1 23 (19.0%), CIN 2-3 39 (32.0%), and invasive cancer 2 (1.6%). On univariate analysis, predicting factors of having high-grade CIN included a high N/C ratio, greater nuclear hyperchromasia, nuclear membrane irregularities, and the coarse chromatin. The multivariate analysis showed that a high nuclear-to-cytoplasmic (N/C) ratio (OR = 8.6, 95% CI = 1.1-70.1) and greater nuclear hyperchromasia (OR = 5.8, 95% CI = 1.6-20.8) were the independent predictors for high-grade CIN or invasive carcinoma.

**Conclusion:** The presence of a high N/C ratio and greater nuclear hyperchromasia could be used to predict high-grade CIN or invasive carcinoma in ASC-H smears.

**Keywords:** Atypical squamous cells, High-grade squamous intraepithelial lesion, Cervical smears, Cervical cancer

*J Med Assoc Thai* 2013; 96 (11): 1389-94

Full text. e-Journal: <http://jmat.mat.or.th>

Cervical cytology screening has been introduced to be the mainstay of cervical cancer prevention. The Bethesda nomenclature system for cervical cytology was first developed at a National Cancer Institute US in 1988<sup>(1)</sup> to provide a uniform terminology classification that was reproducible and that correlated with histology of underlying cervical lesions. 'Atypical squamous cells includes high-grade squamous intraepithelial lesion (ASC-H), which is a new diagnostic classification in the 2001 Bethesda nomenclature system<sup>(2)</sup>. The ASC-H category denotes

cases with some but not all of the cytomorphological criteria for a high-grade squamous intraepithelial lesion (HSIL). There are several studies illustrating the various underlying cervical histopathology of women with ASC-H. The rates of underlying high-grade cervical intraepithelial neoplasia range from 24 to 94%<sup>(3-8)</sup>.

Due to a high prevalence of high-grade lesion, the recommended initial management is immediate colposcopy<sup>(9)</sup>. Treatment option after colposcopy may be either colposcopically-directed biopsy (CDB) followed by cytological reviewed or immediate treatment using loop electrosurgical excision procedure (LEEP), or the so-called 'see and treat' approach<sup>(10)</sup>. The treatment option after colposcopy usually depends on the prevalence of high-grade cervical intraepithelial neoplasia (CIN), patient factors, and doctor preference.

## Correspondence to:

Boonyapipat S, Department of Obstetrics and Gynecology, Faculty of Medicine, Prince of Songkla University, Hat Yai, Songkhla 90112, Thailand.

Phone & Fax: 074-429-617

E-mail: [sathana.t@psu.ac.th](mailto:sathana.t@psu.ac.th), [thitiatjimakul@yahoo.com](mailto:thitiatjimakul@yahoo.com)

Recently, there are studies concentrating on potential biomarkers as a predicting factor of high-grade CIN such as HPV testing and p16 immunostaining<sup>(11)</sup>. Although positive HPV testing predicts high-grade cervical disease, role of HPV testing is not included in the initial management of ASC-H and a negative test is mainly used to reassure of the absence of disease<sup>(12)</sup>. The utility of p16 immunostaining for predicting CIN 2+ in ASC-H smears is inconclusive<sup>(11)</sup>.

There is limited data regarding to predicting value of pertinent patient information, especially cytomorphological and the clinical data that may be helpful for deciding management options in women with ASC-H smears. The purpose of the present study was to determine the risk factors focusing on cytomorphological and clinical features of having high-grade CIN/invasive carcinoma in women with ASC-H smears.

#### **Material and Method**

The cross-sectional study was conducted at Songklanagarind Hospital, a University Hospital, which is a tertiary center for gynecologic oncology in southern Thailand. The present study was approved by the Institute of Ethics Committee of Faculty of Medicine at Prince of Songkla University, Hat Yai, Songkhla, Thailand. The medical records of women who had had a conventional pap-smear featuring ASC-H, and who underwent immediate colposcopy were retrospectively reviewed between January 1, 2004 and December 31, 2011. According to a proportion of factors related to the risk of CIN/invasive carcinoma in previous studies<sup>(13)</sup>, 121 specimens from women who had ASC-H smear needed to be reviewed. The primary outcomes of interest were the incidence of the ASC-H smears, the patient characteristics, the details and morphologic features of the smear, histopathologic diagnoses on colposcopically directed biopsy (CDB) or subsequent loop electrosurgical excision procedure (LEEP) or hysterectomy. The follow-up histology was obtained for up to six months after the colposcopy.

In Songklanagarind Hospital, during the study period, all cervical smears were conventional preparations. The same pathologist reviewed the specimens cervical smears of all eligible records. All the suspected lesions based on colposcopic findings were biopsied by using one of these method punch biopsy, loop excision, or entire transformation zone excision. Endocervical curettage was performed in cases where the squamocolumnar junction or the

boundaries of the lesions were deeply located in the cervical canal. Cytomorphologic features present in ASC-H focused on higher number of atypical cells, single atypical cells, high nuclear/cytoplasm (N/C) ratio, nucleoli, chromocenters, single nuclear groove, coarse chromatin, nuclear hyperchromasia, nuclear membrane irregularity and inflamed background.

All data was double entered into EpiData 2.0 and analyzed by R software version 2.7.0 (the R Foundation for Statistical Computing 2008, Austria). Demographic characteristics and clinicocytological features were analyzed using univariate and multivariate analysis. The normal distribution of continuous data was tested then unpaired t-test or the Mann-Whitney U-test was used as appropriate. The categorical data were analyzed using Chi-square or Fisher's exact test as appropriate. A backward stepwise logistic regression model was used to identify the independent predictors of high-grade CIN/invasive carcinoma with a p-value of less than 0.05 as a significant difference. The Receiver Operating Characteristics (ROC) curve of predictors was created using fitting value obtained from a logistic regression model. Finally, the sensitivity, specificity, and likelihood ratios of prediction were calculated.

#### **Results**

Over an 8-year period, 193 of 136,638 smears were reported as ASC-H. The incidence was 0.14%. Of these, 121 smears had cytomorphologic available for review. All slides were satisfactory for evaluation. The mean age was 47 years, with a range of 24 to 77 years. Ninety-four women (77.7%) were more than 40 years old. Eighty-six women (71.1%) were pre-menopausal and twelve (9.9%) were nulliparous. Contraception data was available in 56 women. Of these, seventeen women (30.4%) had used hormonal contraception.

All of the women with ASC-H smears underwent colposcopy and histological diagnosis. Sixty-eight (56.2%) women had a satisfactory colposcopy. Colposcopic-directed biopsies were performed in 53 (65.9%) women. The remaining had LEEP done at the first approach. Endocervical curettage was carried out in 109 women (90.1%). The histopathologic results of women demonstrated negative/reactive (N/R) 57 (47.1%), CIN 1 23 (19.0%), CIN 2-3 39 (32.0%), and invasive cancer 2 (1.6%).

Univariate analysis showed that cytomorphologic features of ASC-H smears predicting high-grade lesions diagnosis included

a high N/C ratio, greater nuclear hyperchromasia, nuclear membrane irregularities, and the coarse chromatin. No demographic characteristics were associated with high-grade lesions (Table 1). The final model of the multivariate logistic regression is shown in Table 2. A high N/C ratio and greater

**Table 1.** Univariate analysis of cytomorphological features and demographic characteristics between benign disease/low-grade cervical intraepithelial neoplasia (CIN) and high-grade CIN/invasive carcinoma

Factors	Benign/CIN 1, n = 80 [n (%)]	CIN 2+, n = 41 [n (%)]	p-value
<b>Cytomorphologic features</b>			
Higher number of atypical cells			0.54
Mild	56 (70.0)	32 (78.0)	
Moderate	16 (20.0)	7 (17.1)	
Severe	8 (10.0)	2 (4.9)	
Single atypical cells	40 (50.0)	24 (58.5)	0.37
High nuclear/cytoplasmic ratio	69 (86.3)	40 (97.6)	0.05
Nucleoli	2 (2.5)	0	0.55
Single nuclear groove	16 (20.0)	6 (14.6)	0.47
Coarse chromatin	54 (67.5)	36 (87.8)	0.02
Nuclear hyperchromasia	58 (72.5)	38 (92.7)	0.01
Nuclear membrane irregularity	14 (17.5)	15 (36.6)	0.02
Inflamed background			0.57
0	16 (20.0)	7 (17.1)	
1	46 (57.5)	21 (51.2)	
2	18 (22.5)	13 (31.7)	
HPV cytopathic effect	8 (72.3)	4 (66.7)	0.79
Cell aggregate syncytial-liked	18 (32.7)	23 (34.9)	0.81
<b>Demographic characteristics</b>			
Age group (years)			0.39
<40	16 (20.0)	11 (26.8)	
≥40	64 (80.0)	30 (73.1)	
Reproductive status			0.43
Premenopause	55 (68.7)	31 (75.6)	
Postmenopause	25 (31.3)	10 (24.4)	
Parity			1.00
Nullipara	8 (10.0)	4 (9.8)	
Multipara	72 (90.0)	37 (90.2)	
Hormonal contraception			0.22
Nonhormonal	23 (76.7)	16 (61.5)	
Hormonal	7 (23.3)	10 (38.5)	
HIV status			1.00
Non reactive	54 (94.7)	30 (93.7)	
Reactive	3 (5.3)	2 (6.3)	

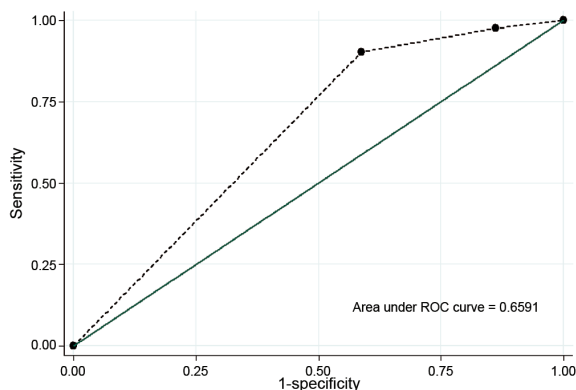
CIN 1 = low-grade cervical intraepithelial neoplasia

CIN 2+ = high-grade cervical intraepithelial neoplasia (CIN 2/3) and carcinoma

**Table 2.** Final model of significant predictors in multivariate analysis

Predictors	Crude OR (95% CI)	Adjusted OR (95% CI)	p-value (LR-test)
High N/C ratio			0.009
No	1	1	
Yes	6.4 (0.8, 51.2)	8.7 (1.1, 70.1)	
Nuclear hyperchromasia			0.002
No	1	1	
Yes	4.8 (1.3, 17.2)	5.8 (1.6, 20.8)	

N/C = nuclear/cytoplasm; LR = likelihood ratio; OR = odds ratio



**Fig. 1** ROC curve using fitting value from logistic regression model.

nuclear hyperchromasia were the independent predictors for high-grade CIN or invasive carcinoma.

According to two significant factors, the ROC curve is constructed and shown in Fig. 1. The sensitivity using a cut point of combining two factors in predicting high-grade CIN/invasive cancer was 90% and the specificity was 41%. The likelihood ratio (LR) for predicting high-grade CIN/invasive cancer in the presence of high N/C ratio without nuclear hyperchromasia was 0.27. LR in case of having nuclear hyperchromasia without high N/C ratio was 0.18. As all of the ASC-H smears illustrated at least one significant factor, the LR for the absence of both factors was not available.

## Discussion

The 2001 Bethesda Conference has categorized findings ASC-H described the cases with some but not all of the cytomorphological criteria for a high-grade squamous intraepithelial lesion (HSIL) demonstrating small, squamous appearing cells with dense cytoplasm that exhibit nuclear enlargement, an increased N/C ratio, and nuclear hyperchromasia and/or irregularities<sup>(2)</sup>. The significant cytomorphologic differences in the ASC-H category with a CIN compared with N/R diagnosis were fewer atypical cells, more often discohesive or seen singly, more monomorphic, a high N/C ratio, greater nuclear hyperchromasia, coarser, more prominent nuclear membrane irregularities, lack of nucleoli, chromocenters or nuclear grooves, and lack of an inflammatory background<sup>(13)</sup>.

In the present study, the authors have identified two cytomorphologic features that were associated with a diagnosis of high-grade CIN or

invasive carcinoma, particularly a higher N/C ratio and greater nuclear hyperchromasia. These findings are similar to those of Alli et al<sup>(13)</sup>, in their review of 72 ASC-H smears, they noted that nuclear enlargement was present in 80% of cases, hyperchromasia in 80%, coarse chromatin in 70%, and irregular nuclear membrane in 80% of women diagnosed as CIN/invasive cancer whereas such features were found 15%, 30%, 15%, and 30% respectively in N/R.

The mean age of women with ASC-H smears in the present study was 47 years old, which was corresponding to the other studies<sup>(3)</sup>. Previous studies have attempted to identify clinical variables for predicting high-grade CIN in women with ASC-H smears. Louro et al noted a significantly higher detection rate of biopsy-proven CIN following a cytologic interpretation of ASC-H smears in women younger than 40 years<sup>(8)</sup>. Seventy-five percent of these women were in pre-menopausal status with a diagnosis of high-grade CIN. Saad et al<sup>(14)</sup> demonstrated that ASC-H in pre-menopausal women was significantly associated high-grade lesion in 22% cases, as opposed to fewer than 6% in the post-menopausal group. In the present study, however, the proportion of women with clinically significant lesions, when stratified by age and menopausal status was not significantly different.

In the literature, almost all of these studies report the histopathologic results of ASC-H smears with a low incidence of invasive cervical cancer. The detection rate of high-grade lesions in such studies varied from 10% to 80% and invasive cancer 2% to 8%<sup>(3)</sup>. This wide variation might be from the lack of definitive criteria for ASC-H smears and subjectivity of cytomorphology resulting in poor interobserver agreement<sup>(6,15)</sup>. In our study with low incidence of ASC-H (0.14%), the detection of CIN 2-3 and invasive cancer had a rate of 33.62%. Invasive cancer in the present study was 1.65%. Based on the authors' findings, women with ASC-H should undergo reviewed smears and immediate colposcopy.

Based on findings from multivariate analysis, presence of both factors provided high sensitivity (90%) and moderate specificity (41%) making the predictors less meaningful in clinical decisions making. Nevertheless, the likelihood ratios could be used to predict the probability of disease. In the present study, the LR associated with having only one predictor is low (0.18-0.27), which means that having only one predicting factor indicated decrease probability of high-grade cervical lesions compared with pretest probability. In women, having only one factor

especially in younger or pre-menopausal age group should consider management with more conservative treatment to avoid risk of overtreatment.

The limitation of the study is that intraobserver and interobserver variation is not yet determined. In addition, interobserver variation should be further investigated in different study. In the new era, more studies are needed to evaluate molecular categorization in the management of women with ASC-H smears.

### Conclusion

The presence of a high N/C ratio and greater nuclear hyperchromasia could be used to predict high-grade CIN or invasive carcinoma in ASC-H smears. All ASC-H slides should be intensive reviewed respecting to N/C ratio and nuclear hyperchromasia. Women who have only one factor should consider more conservative management.

### Acknowledgement

This research project was supported by a grant from Prince of Songkla University. We wish to thank Alan Geater in the Epidemiology Unit who provided us with the statistical consultants.

### Potential conflicts of interest

None.

### References

1. The 1988 Bethesda System for reporting cervical/vaginal cytological diagnoses. National Cancer Institute Workshop. *JAMA* 1989; 262: 931-4.
2. Solomon D, Davey D, Kurman R, Moriarty A, O'Connor D, Prey M, et al. The 2001 Bethesda System: terminology for reporting results of cervical cytology. *JAMA* 2002; 287: 2114-9.
3. Kietpeerakool C, Srisomboon J, Tantipalakorn C, Suprasert P, Khunamornpong S, Nimmanhaeminda K, et al. Underlying pathology of women with "atypical squamous cells, cannot exclude high-grade squamous intraepithelial lesion" smears, in a region with a high incidence of cervical cancer. *J Obstet Gynaecol Res* 2008; 34: 204-9.
4. Wright TC Jr, Cox JT, Massad LS, Twiggs LB, Wilkinson EJ. 2001 Consensus Guidelines for the management of women with cervical cytological abnormalities. *JAMA* 2002; 287: 2120-9.
5. Cytryn A, Russomano FB, Camargo MJ, Zardo LM, Horta NM, Fonseca RC, et al. Prevalence of cervical intraepithelial neoplasia grades II/III and cervical cancer in patients with cytological diagnosis of atypical squamous cells when high-grade intraepithelial lesions (ASC-H) cannot be ruled out. *Sao Paulo Med J* 2009; 127: 283-7.
6. Quddus MR, Sung CJ, Steinhoff MM, Lauchlan SC, Singer DB, Hutchinson ML. Atypical squamous metaplastic cells: reproducibility, outcome, and diagnostic features on ThinPrep Pap test. *Cancer* 2001; 93: 16-22.
7. Duncan LD, Jacob SV. Atypical squamous cells, cannot exclude a high-grade squamous intraepithelial lesion: the practice experience of a hospital-based reference laboratory with this new Bethesda system diagnostic category. *Diagn Cytopathol* 2005; 32: 243-6.
8. Louro AP, Roberson J, Eltoun I, Chhieng DC. Atypical squamous cells, cannot exclude high-grade squamous intraepithelial lesion. A follow-up study of conventional and liquid-based preparations in a high-risk population. *Am J Clin Pathol* 2003; 120: 392-7.
9. American College of Obstetricians and Gynecologists. ACOG Practice Bulletin No. 99: management of abnormal cervical cytology and histology. *Obstet Gynecol* 2008; 112: 1419-44.
10. Kietpeerakool C, Cheewakriangkrai C, Suprasert P, Srisomboon J. Feasibility of the 'see and treat' approach in management of women with 'atypical squamous cell, cannot exclude high-grade squamous intraepithelial lesion' smears. *J Obstet Gynaecol Res* 2009; 35: 507-13.
11. Guo M, Warriage I, Mutyala B, Patel S, Lin E, Gong Y, et al. Evaluation of p16 immunostaining to predict high-grade cervical intraepithelial neoplasia in women with Pap results of atypical squamous cells of undetermined significance. *Diagn Cytopathol* 2011; 39: 482-8.
12. Apgar BS, Kittendorf AL, Bettcher CM, Wong J, Kaufman AJ. Update on ASCCP consensus guidelines for abnormal cervical screening tests and cervical histology. *Am Fam Physician* 2009; 80: 147-55.
13. Alli PM, Ali SZ. Atypical squamous cells of undetermined significance—rule out high-grade squamous intraepithelial lesion: cytopathologic characteristics and clinical correlates. *Diagn Cytopathol* 2003; 28: 308-12.
14. Saad RS, Dabbs DJ, Kordunsky L, Kanbour-Shakir A, Silverman JF, Liu Y, et al. Clinical significance of cytologic diagnosis of atypical squamous cells, cannot exclude high grade, in perimenopausal and postmenopausal women.



Am J Clin Pathol 2006; 126: 381-8.  
15. Sherman ME, Solomon D, Schiffman M.  
Qualification of ASCUS. A comparison of

equivocal LSIL and equivocal HSIL cervical  
cytology in the ASCUS LSIL Triage Study. Am J  
Clin Pathol 2001; 116: 386-94.

---

**ปัจจัยทางโครงสร้างเซลล์และทางคลินิกที่สามารถทำนายรอยโรคภายในเยื่อปากมดลูกชั้นสูงและมะเร็งปากมดลูก  
ในสตรีที่มีเซลล์วิทยา ASC-H**

ธิตี อัจฉิมากุล, สาธนา บุญยพิพัฒน์, สายบัว ชีเจริญ, มัลลิกา ภูแก้วล้วน

**วัตถุประสงค์:** ศึกษาปัจจัยทางโครงสร้างเซลล์และทางคลินิกที่สามารถทำนายรอยโรคภายในเยื่อปากมดลูกชั้นสูง และมะเร็งปากมดลูก  
ในสตรีที่มีเซลล์วิทยา ASC-H

**วัสดุและวิธีการ:** สตรีที่มีเซลล์วิทยา ASC-H ที่ตรวจด้วยคอลโปสโคปและมีผลทางพยาธิวิทยาระหว่างเดือนมกราคม พ.ศ. 2547  
ถึง เดือนธันวาคม พ.ศ. 2554 รวบรวมข้อมูลทางคลินิกและทบทวนโครงสร้างทางเซลล์วิทยาที่สัมพันธ์กับการวินิจฉัยผลทาง  
พยาธิวิทยาของเนื้อเยื่อปากมดลูก นำมาวิเคราะห์แบบตัวแปรเดียวและความถดถอยเชิงพหุ เพื่อหาปัจจัยที่สามารถทำนายรอยโรค  
ภายในเยื่อปากมดลูกชั้นสูงและมะเร็งปากมดลูก

**ผลการศึกษา:** ผลตรวจเซลล์วิทยา ASC-H ร้อยละ 0.14 ของเซลล์วิทยาทั้งหมด ในช่วงเวลาที่ศึกษามีสไลด์เซลล์วิทยา ASC-H  
121 แผ่นที่ได้ทบทวนโครงสร้างทางเซลล์วิทยาและมีผลทางพยาธิวิทยา ผลไม่พบรอยโรค ร้อยละ 47.1 พบรอยโรครุนแรงน้อยกว่า  
เยื่อปากมดลูกชั้นสูง ร้อยละ 19 รอยโรคเยื่อปากมดลูกชั้นสูง ร้อยละ 32 และมะเร็งระยะลุกลาม ร้อยละ 1.6 เมื่อวิเคราะห์  
ความถดถอยเชิงพหุพบปัจจัยทางโครงสร้างเซลล์วิทยา ที่ทำนายรอยโรคภายในเยื่อปากมดลูกชั้นสูงและมะเร็งปากมดลูกคือ  
อัตราส่วนระหว่างนิวเคลียสกับไซโตพลาสซึมเพิ่มขึ้น [OR 8.6 (1.1-70.1)] และโครมาตินดัดสีเข้มขึ้น [OR 5.8 (1.6-20.8)]

**สรุป:** ปัจจัยที่สามารถทำนายรอยโรคภายในเยื่อปากมดลูกชั้นสูง และมะเร็งปากมดลูกในสตรีที่มีเซลล์วิทยา ASC-H คือ อัตราส่วน  
ระหว่างนิวเคลียสกับไซโตพลาสซึมเพิ่มขึ้นและโครมาตินดัดสีเข้มขึ้น

---