

Off-Loading Total Contact Cast in Combination with Hydrogel and Foam Dressing for Management of Diabetic Plantar Ulcer of the Foot

Tanawat Vaseenon MD*,
Songwut Thitiboonsuwan MD*, Chaiyarit Cheewawattanachai MD*,
Punngam Pimchoo MSc*, Areerak Phanphaisarn BSc*

* Department of Orthopaedics, Faculty of Medicine, Chiang Mai University, Chiang Mai, Thailand

Background: The total contact cast is considered to be an effective method of off-loading a diabetic non-infected pressure ulcer. However, complications have been reported in 1 to 15% of cases, e.g. prolonged healing of the ulcer. Debridement with modern dressings has been reported to be effective in promoting wound healing; however, there have been few reported studies of the combination of modern dressings with the cast.

Objective: To evaluate the effectiveness of a combination of treatments on healing rates in diabetic non-infected plantar ulcer of the foot.

Material and Method: This retrospective study with prospective data collection was conducted between September 2010 and August 2012. Twenty diabetic patients with plantar neuropathic ulcer were treated using a combination of a contact cast plus hydrogel and foam dressings. The size and location of the ulcer, ulcer healing, foot deformities and complications were evaluated.

Results: Of 21 ulcers, 20 (95.2%) healed completely in a mean time of 30.1 days (range 14 to 70 days). Healing times for forefoot and midfoot ulcers were 22.6 and 26.8 days, respectively, which is significantly shorter than the 51.7 days for heel ulcers. One patient who had an unhealed ulcer developed a severe infection two months after treatment, which necessitated below the knee amputation. There were three cases of recurrence of the ulcers after casting.

Conclusion: Off-loading casting combined with modern dressings had a high rate of healing in short-term treatment of diabetic non-infected pressure ulcers. Recurrence of ulcers and new site abrasions were common complications; those complications may have been caused by association with bone deformity or improper footwear.

Keywords: Off-loading, Total contact cast, Diabetes, Ulcer, Hydrogel, Foam dressing

J Med Assoc Thai 2014; 97 (12): 1319-24

Full text. e-Journal: <http://www.jmatonline.com>

A diabetic ulcer is the major cause of diabetic-related amputations of the lower extremity. Incidence of diabetic ulcers is increasing and continues to be a cause of prolonged hospitalization and rising treatment costs⁽¹⁾. Up to 4% of diabetic patients have plantar foot ulcers at any given time⁽²⁾. Impairment of sensation including absence of pain, pressure and impaired proprioception causes loss of protective mechanisms in the foot that lead to ulceration. Moreover, impairment of motor control and intrinsic muscle can result in foot deformity or Charcot foot syndrome. Mechanical stresses from walking can contribute to ulcer formation⁽³⁾. Most diabetic ulcers are caused by excessive loading of an area of the foot that is

incapable of withstanding those forces. In cases of non-infection and non-ischemic ulcers, off-loading the ulcer results in promoting healing⁽⁴⁾.

A variety of methods have been reported for off-loading the foot to promote healing⁽⁵⁻⁷⁾. A total contact cast (TCC) is considered an effective method of off-loading a diabetic pressure ulcer. A number of studies have described the effectiveness of treating foot ulcers in diabetic patients by TCC. That method has the additional socio-economic benefits of keeping the patient mobile and avoiding prolonged hospitalization^(3,4,8,9). The mechanisms of TCC which improve ulcer healing include distribution of plantar pressure across adjacent areas as well as promotion of venous pumping which occurs with walking. Although this method has been demonstrated to be effective, complications such as recurrence of the ulcer and prolonged healing time have been reported in 1 to 15% of cases^(10,11).

Correspondence to:

Vaseenon T, Department of Orthopaedics, Faculty of Medicine, Chiang Mai University, Chiang Mai 50200, Thailand.

Phone: 053-945-544, Fax: 053-946-442

E-mail: tvaseenon@yahoo.com

Treatments of diabetic ulcer include patient education, blood sugar control, correction of arterial insufficiency, off-loading, debridement and the use of wound dressings. Dressings are used in wound care to promote wound healing and for wound protection. The foam dressing normally consists of hydrophilic polyurethane foam, which is designed to absorb wound exudate and to maintain a moist wound surface. Hydrogel is a hydroactive colloid gel that contains acidic chemical polymers based on a type of acrylate. The gel is used to remove necrotic tissue from the wound bed by inducing lysis of necrotic tissue and reducing crust formation through hydration which promotes the autolytic process⁽¹²⁾. A moist controlled environment is thought to provide optimal conditions to promote cell healing while allowing autolytic debridement⁽¹³⁾. Treatment with hydrogel and foam dressing has been shown to be effective in promoting healing of diabetic ulcers.

The present study assesses the effects of a combination of a total contact cast combined with a hydrogel and foam dressing on the healing of diabetic plantar ulcers of the foot.

Material and Method

This prospective study was conducted between September 2010 and August 2012. Twenty diabetic patients with a plantar neuropathic ulcer were included in the study. Neuropathy was defined as insensitivity to a Semmes-Weinstein 5.07 monofilament at the toes, plantar aspect of the metatarsal heads, midfoot and heel⁽¹⁴⁾. Inclusion criteria were a full-thickness plantar foot ulceration of Wagner grade 1 or 2 with no clinical and radiographic evidence of soft tissue and bone infection. Individuals with peripheral vascular diseases, presence of osteomyelitis or cellulitis, and personality or psychiatric disorders were also excluded. The patient's age, date of ulcer development, size and location of the ulcer, the foot's structural pathology, the time to ulcer closure, and complications during and after the treatment period were recorded. The ulcers were first debrided and cultured to identify bacterial contamination. A vascular specialist performed vascular examination in all cases. Diabetic plantar ulcers that had no bacterial infection were then measured and cleaned followed by hydrogel with foam dressing. The TCC was then applied. The patients initially walked with a cane or a walker in a weight bearing as tolerated program. At each weekly visit, the ulcer dressing and the cast were changed. Clinical demographic data is summarized in Table 1.

Technique of total contact cast for forefoot and midfoot ulcer

After hydrogel and foam were applied to the ulcer, a tubular stockinette was put on over the leg and stretched to prevent folds. Bony prominences e.g. the tibial crest, both malleoli, bunions and the dorsum of the foot were protected with special three mm thick felt. A roll of soft cast (3M Health Care) was applied over the stockinette, covering all toes with a well-molded technique. A 4x30 inch Primacast[®] was applied as a posterior short leg slab from five cm below the popliteal fossa to the toes. Finally, another roll of soft cast was applied in circular fashion.

Technique of total contact cast for hindfoot ulcer

Wound dressing was done using the same technique described above. A tubular stockinette was worn over the leg and stretched to prevent folds. Bony prominences, e.g. the tibial crest, malleoli, bunions and the dorsum of the foot, were protected with a special three mm thick felt. A roll of soft cast (3M Health Care) was applied over the stockinette covering all toes with a well-molded technique. A 4x30 inch Primacast[®] (3M Health Care) was applied as a U slab from five cm below the popliteal fossa with its distal end two cm below the foot. Finally, an additional two rolls of soft cast were applied in a circular pattern to attach to the previous rolls.

Results

Twenty of 21 ulcers healed completely (95.2%). The mean time for healing was 30.1 days (range 14 to 70 days, SD ±15.3 days). The mean healing times of forefoot ulcers (22.6 days) and midfoot ulcers (26.8 days) were both significantly shorter than heel ulcers at 51.7 days ($p < 0.001$ and $p < 0.014$, respectively) (Fig. 1, 2). The mean healing time of ulcers associated with bone deformity was longer than without deformity, but the difference was not significant ($p = 0.457$). Common foot deformities associated with plantar ulcer include rocker bottom foot, hallux valgus and pes cavus. Additional procedures implemented following the off-loading cast were tendoachilles lengthening, dorsiflexion osteotomy of the first ray and tibiototalcalcaneal fusion. One patient who had midfoot ulcers developed a deep wound infection with septicemia that was not discovered until three months after the ulcer had closed. Finally, a below the knee amputation was accomplished. Three patients developed recurrent superficial ulcers after the initial ulcer healed, caused by unstable Charcot arthropathy

Table 1. Demographics of diabetic patients with a plantar neuropathic ulcer

Number	Age	Sex	DM type	Location	Initial ulcer size (cm ²)	Deformities
1	44	F	I	Midfoot	4.0	No
2	54	F	I	5 th metatarsal head	3.5	No
3	47	F	I	5 th metatarsal head	0.9	Pes cavus
4	49	F	I	Midfoot	0.4	No
5	52	M	I	5 th metatarsal head	1.8	No
6	55	F	II	Midfoot	0.3	No
7	57	M	I	5 th metatarsal head	1.9	Rocker bottom
8	62	F	II	Midfoot	3.2	No
9	25	M	I	Heel	1.9	No
10	55	M	II	1 st metatarsal head	6.0	Hallux valgus
11	38	F	I	Heel	6.5	No
12	56	M	II	Midfoot	1.3	Rocker bottom
13	55	F	II	Heel	4.4	No
14	59	M	II	1 st metatarsal head	0.4	No
15	48	F	II	Heel	0.4	No
16	56	F	II	1 st metatarsal head	0.4	No
17	55	M	II	1 st metatarsal head	2.3	Hallux valgus
18	59	M	II	Midfoot	1.4	Rocker bottom
19	42	F	II	Heel	2.7	No
20	54	M	II	Midfoot	2.3	No

DM = diabetes mellitus; F = female; M = male

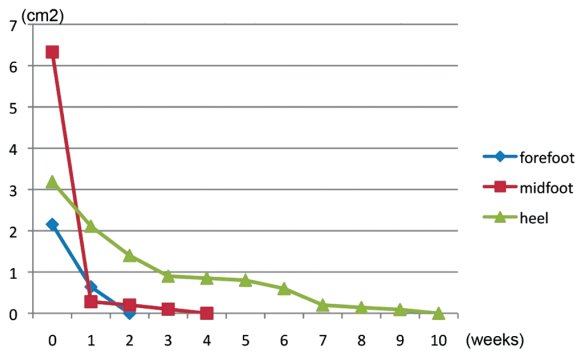


Fig. 1 Size of ulcers (forefoot, midfoot and heel) and time to healing after initial treatment.

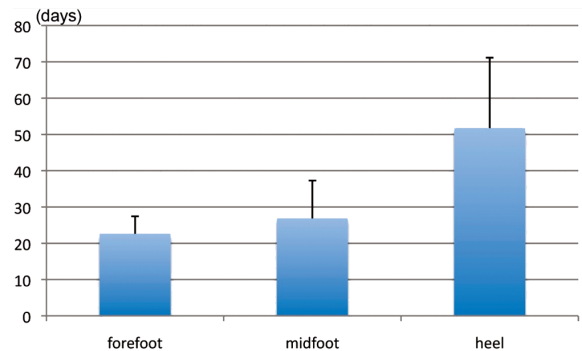


Fig. 2 Difference in healing times of forefoot, midfoot and heel ulcers.

and wearing improper shoes. A new abrasion wound developed in one patient that was continuously treated with added padding and the cast was modified.

Discussion

Twenty patients with 21 diabetic ulcers successfully treated with a combination of hydrocellular dressing and total contact cast were studied. Recurrent wounds developed an average of seven weeks after

initial ulcer healing which is comparable to other published studies⁽¹⁵⁾. Poor patient compliance may be one of the factors resulting in high recurrence rates. The effectiveness and safety of the combination of hydrocellular dressing and total contact cast has been demonstrated. Long-term follow-up and randomized control trials of future treatments are anticipated.

Healing of diabetic foot ulcers is affected by ulcer size, by the presence of ischemia and by infection;

however, it is not affected by the ulcer site, the age and gender of the patient, the DM type or the duration of diabetes⁽¹⁶⁾. Amputations are correlated with wound depth, presence of ischemia and infected ulcers. Total contact casts are the gold standard treatment for diabetic ulcers^(4,17). The role of the casts is to reduce pressure at the ulcer site by about 70-92%⁽¹⁸⁾. Histologic studies have shown granulation neoangiogenesis and a predominance of fibroblasts⁽¹⁹⁾. Total contact casts were found to have a better rate of healing than standard wound care, removable cast walkers and half shoes^(4,20). Hydrogel also increases the healing rate of diabetic ulcers^(21,22). Studies have shown that standard wound care heals only 24% of diabetic ulcers within 12 weeks⁽²³⁾. Total contact casts have been found to heal diabetic ulcers in a mean healing time of about 33.5 days⁽⁴⁾. Another study found that at least 81% of forefoot ulcers can be healed within 12 weeks⁽²⁴⁾. That study also mentioned that ulcer grade and width are correlated with healing time when using the off-loading technique. Using a lognormal regression model, adjusted healing times by ulcer grade and width were found to be no different from alternative off-loading methods or total contact casts. That result may be a consequence of bias in treatment selection during the study. In the present study, the mean healing time was 30.1 days, less than what has been reported in the literature. Forefoot ulcers were found to heal completely more rapidly than ulcers at other locations and somewhat quicker than reported in previous studies^(4,24). The authors believe that the hydrogel and the foam dressing help to promote moist balance in the ulcer that support the off-loading function of total contact cast that improves venous circulation during patient's walk.

Total contact casts do, however, present risks of complications such as recurrence of ulcers at the original sites or at new sites, calluses, blisters, stress fractures of metatarsal bones, cellulitis, amputation and drop foot⁽²⁵⁾. There were 14.3% recurrences of ulcers in this study. Mean ulcer recurrence was 21.6 weeks after initial healing⁽²⁶⁾, the most common reason being patients' lack of compliance. The reason is similar to previous studies that needed aggressive education from multidisciplinary physician teams for future ulcer prevention. Other reasons included foot deformities, early and late Charcot changes or osteomyelitis. Therapeutic shoes which are wider, deeper and fitted with custom insoles can reduce one year recurrence rates by from 58% to 28%⁽²⁷⁾. Therefore, patient education, appropriate footwear

and earlier prophylactic operations should be stressed⁽²⁵⁾.

There are three main limitations to the present study. The first is the limited number of cases. Although diabetic foot ulcers are common, some patients were reluctant to participate in the study because of the discomfort caused by wearing a cast in a humid country and by transportation issues related to the need to return to the hospital every week for casting. The second limitation is that the follow-up study was only short-term. Mid- and long-term follow-ups are important because of variability in disease progression and because complications due to diabetes can cause foot problems to worsen. The third limitation is the lack of randomized control trials. A future study with randomized control trials for diabetic ulcer treatments of the foot is anticipated.

Conclusion

Off-loading casting combined with modern dressings resulted in a high rate of ulcer healing during short-term treatment of diabetic non-infected pressure ulcers. Recurrence of ulcers and new site abrasions were common complications and were associated with bone deformity and improper footwear.

What is already known on this topic?

The total contact cast is a potential treatment in diabetic neuropathic foot ulcer. The treatment period is in average of 6-8 weeks after casting until the ulcer healed.

What this study adds?

Adding modern dressing with hydrocolloid dressing and hydrogel reduce the treatment period to 3-5 weeks in average. The results may be from combination of two ulcer treatments.

Acknowledgement

The authors wish to thank the orthopedics casting teams and the orthopedic residents for their help in the present study, Sirichai Luevitoonvechkij MD and G Lamar Robert PhD for manuscript reviewing.

Potential conflicts of interest

None.

References

1. Pecoraro RE, Reiber GE, Burgess EM. Pathways to diabetic limb amputation. Basis for prevention. *Diabetes Care* 1990; 13: 513-21.

2. Abbott CA, Carrington AL, Ashe H, Bath S, Every LC, Griffiths J, et al. The North-West Diabetes Foot Care Study: incidence of, and risk factors for, new diabetic foot ulceration in a community-based patient cohort. *Diabet Med* 2002; 19: 377-84.
3. Shaw GY, Searl JP. Laryngeal manifestations of gastroesophageal reflux before and after treatment with omeprazole. *South Med J* 1997; 90: 1115-22.
4. Armstrong DG, Nguyen HC, Lavery LA, van Schie CH, Boulton AJ, Harkless LB. Off-loading the diabetic foot wound: a randomized clinical trial. *Diabetes Care* 2001; 24: 1019-22.
5. Myerly SM, Stavosky JW. An alternative method for reducing plantar pressures in neuropathic ulcers. *Adv Wound Care* 1997; 10: 26-9.
6. Catanzariti AR, Haverstock BD, Grossman JP, Mendicino RW. Off-loading techniques in the treatment of diabetic plantar neuropathic foot ulceration. *Adv Wound Care* 1999; 12: 452-8.
7. Birke JA, Patout CA Jr, Foto JG. Factors associated with ulceration and amputation in the neuropathic foot. *J Orthop Sports Phys Ther* 2000; 30: 91-7.
8. Sinacore DR, Withrington NC. Recognition and management of acute neuropathic (Charcot) arthropathies of the foot and ankle. *J Orthop Sports Phys Ther* 1999; 29: 736-46.
9. Lavery LA, van Houtum WH, Harkless LB. In-hospital mortality and disposition of diabetic amputees in The Netherlands. *Diabet Med* 1996; 13: 192-7.
10. Boulton AJ. The diabetic foot: a global view. *Diabetes Metab Res Rev* 2000; 16 (Suppl 1): S2-5.
11. Myerson M, Papa J, Eaton K, Wilson K. The total-contact cast for management of neuropathic plantar ulceration of the foot. *J Bone Joint Surg Am* 1992; 74: 261-9.
12. de la Brassinne M, Thirion L, Horvat LI. A novel method of comparing the healing properties of two hydrogels in chronic leg ulcers. *J Eur Acad Dermatol Venereol* 2006; 20: 131-5.
13. Cardinal M, Eisenbud DE, Armstrong DG, Zelen C, Driver V, Attinger C, et al. Serial surgical debridement: a retrospective study on clinical outcomes in chronic lower extremity wounds. *Wound Repair Regen* 2009; 17: 306-11.
14. Sosenko JM, Kato M, Soto R, Bild DE. Comparison of quantitative sensory-threshold measures for their association with foot ulceration in diabetic patients. *Diabetes Care* 1990; 13: 1057-61.
15. Smith J. Debridement of diabetic foot ulcers. *Cochrane Database Syst Rev* 2002; (4): CD003556.
16. Oyibo SO, Jude EB, Tarawneh I, Nguyen HC, Armstrong DG, Harkless LB, et al. The effects of ulcer size and site, patient's age, sex and type and duration of diabetes on the outcome of diabetic foot ulcers. *Diabet Med* 2001; 18: 133-8.
17. American Diabetes Association. Consensus Development Conference on Diabetic Foot Wound Care: 7-8 April 1999, Boston, Massachusetts. *Diabetes Care* 1999; 22: 1354-60.
18. Landsman AS, Sage R. Off-loading neuropathic wounds associated with diabetes using an ankle-foot orthosis. *J Am Podiatr Med Assoc* 1997; 87: 349-57.
19. Piaggese A, Viacava P, Rizzo L, Naccarato G, Baccetti F, Romanelli M, et al. Semiquantitative analysis of the histopathological features of the neuropathic foot ulcer: effects of pressure relief. *Diabetes Care* 2003; 26: 3123-8.
20. Mueller MJ, Diamond JE, Sinacore DR, Delitto A, Blair VP III, Drury DA, et al. Total contact casting in treatment of diabetic plantar ulcers. Controlled clinical trial. *Diabetes Care* 1989; 12: 384-8.
21. Dumville JC, O'Meara S, Deshpande S, Speak K. Hydrogel dressings for healing diabetic foot ulcers. *Cochrane Database Syst Rev* 2013; 7: CD009101.
22. Edwards J, Stapley S. Debridement of diabetic foot ulcers. *Cochrane Database Syst Rev* 2010; (1): CD003556.
23. Margolis DJ, Kantor J, Berlin JA. Healing of diabetic neuropathic foot ulcers receiving standard treatment. A meta-analysis. *Diabetes Care* 1999; 22: 692-5.
24. Birke JA, Pavich MA, Patout CA Jr, Horswell R. Comparison of forefoot ulcer healing using alternative off-loading methods in patients with diabetes mellitus. *Adv Skin Wound Care* 2002; 15: 210-5.
25. Matricali GA, Deroo K, Dereymaeker G. Outcome and recurrence rate of diabetic foot ulcers treated by a total contact cast: short-term follow-up. *Foot Ankle Int* 2003; 24: 680-4.
26. Helm PA, Walker SC, Pullium GF. Recurrence of neuropathic ulceration following healing in a total contact cast. *Arch Phys Med Rehabil* 1991; 72: 967-70.
27. Uccioli L, Faglia E, Monticone G, Favales F, Durola L, Aldeghi A, et al. Manufactured shoes in the prevention of diabetic foot ulcers. *Diabetes Care* 1995; 18: 1376-8.

การใส่ฝือกลดการลงน้ำหนักร่วมกับการใช้ไฮโดรเจลกับแผ่นโพรรักษาแผลเบาหวานใต้ฝ่าเท้า

ธนวัฒน์ วัฒนินท์, ทรงวุฒิ จิตินุญสุวรรณ, ไชยฤทธิ์ ชีวาวัฒนชัย, พรรณงาม พิมพ์ชู, อารีรักษ์ พันธุ์ไพศาล

ภูมิหลัง: การใส่ฝือกลดการลงน้ำหนักก็มีประสิทธิภาพในการรักษาแผลเบาหวานใต้ฝ่าเท้าชนิดที่ไม่ติดเชื้อ แต่อย่างไรก็ตามยังมีรายงานว่าโรคแทรกซ้อนหรือแผลหายช้ายังพบได้บ่อยถึงร้อยละ 15 การผ่าตัดชำระล้างบาดแผลร่วมกับการใช้การทำแผลแบบใหม่ มีรายงานว่าได้ผลดีต่อการรักษาแผล ปัจจุบันยังไม่มีรายงานที่รวมการรักษาโดยใช้การใส่ฝือกลดการลงน้ำหนักร่วมกับการใช้การทำแผลแบบใหม่ในการรักษาแผลเบาหวานใต้ฝ่าเท้า

วัตถุประสงค์: เพื่อดูผลการรักษาของการรวมการรักษาโดยใช้การใส่ฝือกลดการลงน้ำหนักร่วมกับการใช้การทำแผลแบบใหม่ในการรักษาแผลเบาหวานใต้ฝ่าเท้า

วัสดุและวิธีการ: การศึกษารวบรวมผู้ป่วยจำนวน 20 ราย ที่เป็นแผลเบาหวานจากเส้นประสาทเสื่อมใต้ฝ่าเท้าชนิดไม่ติดเชื้อมารักษารักษาโดยใช้การใส่ฝือกลดการลงน้ำหนักร่วมกับการใช้การทำแผลแบบใหม่ เก็บรวบรวมข้อมูล ขนาดตำแหน่งของแผล ความผิดปกติของเท้า และโรคแทรกซ้อน

ผลการศึกษา: จำนวนแผล 21 แผล จากจำนวนผู้ป่วย 20 ราย คิดเป็นร้อยละ 95.2 หายเป็นปกติในเวลาเฉลี่ย 30.1 วัน จากช่วงเวลาของทั้งหมด 14 ถึง 70 วัน แผลที่ปลายเท้า แผลที่ฝ่าเท้าหายเป็นปกติในเวลาเฉลี่ย 22.6 วัน และ 26.8 วัน ซึ่งน้อยกว่าการหายของแผลที่สันเท้าคือ 51.7 วัน มีผู้ป่วยหนึ่งรายแผลไม่หายและมีการติดเชื้อจนต้องตัดขา มีผู้ป่วยสามราย ที่เป็นแผลซ้ำหลังจากแผลหายจากการใส่ฝือก

สรุป: การรักษาโดยใช้การใส่ฝือกลดการลงน้ำหนักร่วมกับการใช้การทำแผลแบบใหม่มีผลดีในการรักษาแผลเบาหวานชนิดไม่ติดเชื้อใต้ฝ่าเท้าในระยะสั้นของการติดตามผล
