Special Article

Small Bowel Tumors: Pathology and Management

James Matthew Lloyd Williamson MD*,
Robin Charles Noel Williamson MD**

** Department of Hepatopancreatobiliary Surgery, Bristol Royal Infirmary, Upper Maudlin Street, Bristol, BS2 8HW, UK*
*** Department of Hepatopancreatobiliary Surgery, Hammersmith Hospital, London, UK*

Despite comprising at least 75% of the length of the gastrointestinal tract, the small bowel only accounts for 3 to 6% of all its neoplasms. Forty different tumor subtypes arise from the small bowel; the commonest is adenoma, and malignant lesions include gastrointestinal stromal tumor, neuroendocrine tumor, lymphoma, and adenocarcinoma. Small bowel tumors typically cause either non-specific symptoms or none at all, which explains both the frequent delay in diagnosis and the wide range of potential investigations. The relative inaccessibility of the small bowel to endoscopic assessment is being challenged by the increased use of both capsule and double balloon endoscopy. Advances in endoscopic assessment are mirrored by improved sensitivity of radiological and nuclear imaging. Operative resection provides the mainstay of treatment for malignant disease (and symptomatic benign lesions), with oncological agents and somatostatin analogues providing useful adjuncts for inhibiting tumor growth and relieving symptoms. Survival reflects underlying tumor subtype, but is generally poor for malignant disease.

Keywords: *Small bowel tumors, Small bowel cancer, Small bowel lymphoma, Small bowel neuroendocrine tumors*

J Med Assoc Thai 2014; 97 (1): 126-37
Full text. e-Journal: *http://www.jmatonline.com*

The incidence of small bowel tumors is remarkably low, accounting for only 3 to 6% of all gastrointestinal (GI) neoplasms and 1 to 3% of all GI malignancies[1]. Extending from stomach to colon, each of which has a high incidence of tumors, the small bowel constitutes 75% of the length of the alimentary tract and about 90% of its mucosal surface area. It contains rapidly proliferating cells and is bathed by many potential dietary carcinogens. Thus, one would expect tumor incidence to be similar to, if not higher than, that of the neighboring organs. There must surely be protective mechanisms that account for the relative rarity of small bowel neoplasia.

Forty different histological subtypes of tumor arise from the small bowel[2]. The most frequent benign lesion is an adenoma, while malignant lesions include gastrointestinal stromal tumor, neuroendocrine tumor, lymphoma, and adenocarcinoma. The fact that small bowel tumors typically cause little in the way of symptoms explains both a delay in diagnosis of up to nine months and, in the case of cancer, an advanced stage at the time of diagnosis. Investigation of the small bowel has traditionally been limited by its relative inaccessibility, but the increased use and sensitivity of radiological and nuclear imaging coupled with the advent of both capsule and double balloon endoscopy has allowed potential visualization of the entire alimentary tract.

This article aims to highlight the ways in which small bowel tumors present and how they should be investigated and treated.

Correspondence to:
Williamson JML, Department ofHepatopancreatobiliary Surgery, Bristol Royal Infirmary, Upper Maudlin Street, Bristol, BS2 8HW, UK
E-mail: jmlw@doctors.org.uk

Incidence

The estimated incidence of small bowel tumors is 9.9 per million population. Neuroendocrine tumors (carcinoid) and adenocarcinomas are the commonest subtypes, accounting for 3.8 and 3.7 per million respectively. Sarcomas and lymphomas are the only other common types, accounting for 1.3 and 1.1 per million respectively[3]. Some 4,600 reported small bowel tumors were diagnosed in the United States of America in 1995, of which three-quarters were either adenocarcinomas or neuroendocrine tumors[4]. The incidence of small bowel malignancies has been increasing over the last 25 years, especially in black men in whom a two to four fold increase has been noted[3,4]. The reason is unknown. By contrast, the incidence among white women has remained consistent. The incidence of small bowel tumors in patients undergoing capsular endoscopy is between 2.4 and 4.3%[5,6].

Most small bowel tumors are detected in the fifth and sixth decades, although lymphomas present

a decade earlier[7]. There is a male predominance for all tumor types and a predilection for the duodenum, which accounts for a quarter of all lesions, notably adenoma and adenocarcinoma[3,8].

Presentation

Symptoms depend on the size and location of the tumor within the small intestine. Tumors less than 4 cm in diameter are generally asymptomatic and are therefore detected incidentally at operation or autopsy (especially if benign). Symptoms of a malignant tumor are typically vague and include pain, diarrhea, anorexia, and anemia[9]. Weight loss is common, being found in 30 to 50% of patients. Metastases are already present in half the lesions at the time of diagnosis[2]. Jaundice and steatorrhoea may accompany lesions that arise from the duodenal papilla. Tumors can ulcerate, bleed (Fig. 1), cause obstruction (Fig. 2) or perforate (especially lymphoma)[10]. Bleeding is usually occult. Rare patients present acutely with volvulus or intussusception. Neuroendocrine tumors may present with functional syndromes (carcinoid syndrome or somatostatinoma syndrome).

Fig. 1 Small clot sitting on a bleeding vessel on the mucosal aspect of a gastrointestinal stromal tumour (GIST) of the upper small bowel. The patient presented with a massive haemorrhage.

Fig. 2 Carcinoma of jejunum presenting with chronic small bowel obstruction. There is an obvious lymph node metastasis.

Risk Factors

The etiology of small bowel tumors is not fully appreciated, in part due to their relative rarity. Both environmental factors and predisposing conditions (whether inherited and acquired) are linked to disease development.

Genetic factors

Small bowel cancer rates are high among the Maoris of New Zealand and ethnic Hawaiians, but are low in India and Eastern Europe. This variation could indicate a potential susceptibility in some racial subgroups or perhaps specific environmental factors[8]. A slightly higher incidence of adenocarcinoma and neuroendocrine tumor has been noted in Africans and Afro-Caribbeans compared to Eurasians, but these ratios vary for other subtypes[10].

Multiple endocrine neoplasia syndrome and neurofibromatosis type 1 (von Recklinghausen disease) predispose to neuroendocrine tumor formation[11]. Patients with known cellular genetic mutations, for example to p53 and K-ras, are also likely to be at increased risk of tumor formation.

Environmental factors

Diet is the likeliest source of environmental carcinogens that affect the small bowel: sugar, fats, antioxidants, and meat (both red and processed) may promote carcinogenesis, whereas fruit, fiber, vegetables, soya, and kidney beans may be protective[12]. The risk of small bowel adenocarcinoma appears to be directly linked to intake of bread, pasta and rice[12]. The 'western diet' has been implicated as a risk factor for tumor development, although this has not been conclusively demonstrated. Obesity per se is linked to increased risk of cancer. Radiation exposure is another potential factor; the risk persists for 30 years post exposure. No clear causative mechanisms exist for alcohol or

tobacco, although these agents have been associated with stomach and colonic cancer.

Predisposing conditions

Both adenocarcinoma and lymphoma are associated with pre-existing bowel disease, including coeliac disease, Crohn's disease, immunoproliferative small intestinal disease (IPSID), Peutz-Jeghers syndrome, and familial adenomatous polyposis (FAP) (Table 1)[2]. This increased predisposition towards malignancy may be related to chronic inflammation or the presence of polypoid lesions, which can undergo malignant transformation. In addition, a slight increase in risk of tumor development is seen in immunodeficiency syndromes, nodular lymphoid hyperplasia, gastrointestinal polyposis syndromes, hereditary nonpolyposis cancer, neurofibromatosis, long-standing ileostomy, and urinary diversionary procedures[8,13]. Lymphoma is also more common in acquired immune deficiency syndrome (AIDS) and, as such, is particularly prevalent in developing countries[14].

Inflammatory conditions

In coeliac disease, gluten causes mucosal atrophy within the jejunum, which decreases in severity towards the ileum as it is digested into smaller fragments. Patients with longstanding coeliac disease have an increased risk of T-cell lymphoma and adenocarcinoma of the small bowel, which seems independent of the avoidance of dietary gluten[13,15,16]. Although Crohn's disease can affect any part of the alimentary tract, it has a predisposition for the terminal ileum. Chronic inflammation is thought to predispose to malignancy, and the relative risk of cancer formation in Crohn's disease is one hundred times greater than in the background population[3]. Associated cancer formation occurs earlier than for sporadic lesions (mean 45 years versus 65 years)[3].

Intestinal proliferation

IPSID is a malabsorptive syndrome associated with diffuse lymphoid infiltration of the small bowel and localized lymph nodes. This condition affects lower socio-economic groups (with poor hygiene and associated high incidence of bacterial and parasitic intestinal infections) in Mediterranean countries. IPSID is a B-lymphocyte disorder that results in plasma cell proliferation and predisposes to lymphoma[16].

Polyposis syndromes

Intestinal polyposis syndromes are associated with an increased risk of tumor formation in both the large and small intestine. Peutz-Jeghers syndrome is a rare autosomal dominant disorder characterized by multiple harmatomatouspolypoid lesions in the jejunum, although they can exist in the duodenum, ileum, stomach, and colon. Small bowel polyps are found in 60 to 90% of patients[2]. The Peutz-Jeghers gene encodes for serine threonine kinase STK11 (or LKB1), which is a tumor suppressor gene[17]. Peutz-Jeghers syndrome is associated with both intestinal and non-intestinal tumors and may therefore reflect an overall susceptibility to tumor formation rather than malignant transformation of a polypoid lesion[18]. Overall life-time risk of cancer formation is between 85 and 93%, most commonly in breast (54%), colon (39%) and pancreas (36%)[2]. Approximately 10% of all polypoid hamartomatous polyps are due to Peutz-Jeghers syndrome. The rate of malignant change is 6%[17,19]. Life-time risk of small bowel cancer is between 1.7 and 13%, and the duodenum is usually affected[2].

Familial adenomatous polyposis (FAP) is an autosomal dominant trait characterized by multiple adenomatous polyps throughout the gastrointestinal tract, especially in the periampullary region of the duodenum[16]. Five percent of duodenal adenomas

Table 1. Risk factors for small bowel tumours, adapted from Cheung and Choi[2]

Clinical condition	Type of small bowel tumour
Familial adenomatous polyposis	Adenocarcinoma
Hereditary non-polyposis colorectal cancer	Adenocarcinoma
Peutz-Jeghers syndrome	Adenocarcinoma
Coeliac disease	Lymphoma (and adenocarcinoma)
Crohn's disease	Adenocarcinoma
Biliary diversion	Adenocarcinoma
Skin melanoma	Melanoma

will undergo malignant transformation[3]. FAP patients with multiple large, dysplastic polyps have a 36.4% risk of duodenal caner at 10 years[2]. Duodenal polyps have a predilection for the periampullary region and are found in 70 to 90% of patients with FAP[20]. By contrast, hereditary non-polyposis colorectal cancer (HNPCC) does not cause multiple polyps, but is associated with an increased risk of tumor development within the small bowel[2]. Patients with HNPCC have a cumulative risk of small intestinal adenocarcinoma of 3 to 4% (more than 100 times greater than the background population).

Acquired conditions

Patients with ileal transpositions (in the form of ileal conduits), biliary diversion procedures, ileostomies or rectal pouches are all at a slight increased risk of small bowel carcinoma, although the mechanism is not entirely understood[2]. Alteration of chyme composition or chronic inflammation might be causative agents, coupled with loss of some of the protective mechanisms mentioned below.

Protective Features of the Small Bowel

There is a multitude of theories to explain the low incidence of small bowel tumors, although none is definitive. These theories primarily relate to the physiology of the small bowel, although other features unique to this region of the gut include the constitution of chyme, anatomical variants, and the synergistic role of bacteria.

Small bowel anatomy and physiology

The small bowel has a well-developed protective system characterized by local IgA-mediated immunity. Patients with a deficiency of this immunoglobulin are at increased risk of small bowel cancer; this mechanism may be particularly relevant for lymphomas[10]. The small bowel has fewer stem cells than the colon or stomach, and these may be the target cells for cancer formation (the stem cell theory of carcinogenesis). These stem cells lie deep within intestinal crypts and thus are shielded from potential carcinogens by a mucus layer; other mechanisms maintain their genetic integrity.

Other protective mechanisms may include: 1) The relatively high cell turnover of the small bowel epithelium (one gram of mucosal cells being replaced every 15 minutes[3,4,8]. 2) The rapid transit time of small bowel contents, which minimizes exposure to dietary carcinogens. 3) Carcinogens induce apoptosis within the small bowel, which results in defective cells being quickly removed. The bcl-2 gene, which prevents apoptosis, is abundant in the murine colonic crypt, but scarce in the small intestine[4,8]. 4) Chyme is very liquid in the small bowel, which may reduce mechanical trauma and prevent mucosal breaches. It is also very alkaline, which prevents the formation of nitrosamines that may be carcinogenic in the acidic gastric environment[21]. 5) The duodenum secretes an unidentified water-soluble tumor-inhibiting compound[4,8]. 6) The small bowel contains low levels of agents that activate precarcinogens. It also contains high concentrations of benzopyrene hydrolase, an enzyme that converts the potent carcinogen benzopryrene into a less active compound. A high concentration of the enzyme detoxifying carcinogen also exists within the small intestine[8]. 7) Bacteria are relatively scarce in the normal small bowel, thereby reducing bacterial breakdown of dietary precarcinogens into their active form[4-8]; methylazoxymethanol, which is produced by bacterial flora, induces colon cancer.

Benign Neoplasms

Benign tumors account for approximately 40% of all small bowel lesions. Adenoma is the commonest type, making up about one third, most are tubular, but villous adenomas and Brunner's gland adenomas can occur[3,7,8]. Other tumors include lipoma (15-25%) and less commonly fibroma or vascular, neurogenic and lymphatic tumors, each of which represent less than 10% of all benign lesions[10,22].

Adenomas

Most adenomas are found within the duodenum, either at or just distal to the papilla (very few are found proximally). This pattern of distribution closely mirrors mucosal exposure to bile, which could be a promoting agent[3]. Between 40 to 50% of adenomas are found in the duodenum, 35 to 40% occur in the jejunum and 20 to 25% in the ileum[10,23]. Tubular adenomas are usually polypoid in nature, as opposed to villous adenomas which are sessile; tubulovillous lesions have characteristics of both. Malignant change mimics the adenoma-carcinoma sequence in the large bowel, and is more prevalent with periampullary lesions[23]. Malignant potential is increased with large, multiple or villous lesions.

Brunner's gland adenomas are restricted to the duodenum and tend to be either pedunculated or ulcerative. They exist in one of three forms, polypoid,

isolated nodule hyperplasia, and diffuse nodulated hyperplasia. They have a very low malignant potential[3].

Other benign tumors

Lipomas are relatively common within the small bowel and can be either single or multiple[10,22]. Haemangiomas represent less than ten per cent of all small bowel neoplasms; they are universally benign and are either capillary or cavernous in nature; they typically present with bleeding[3]. Hamartomas are also benign vascular tumors with an overall low risk of malignancy; lesions within the duodenum are more prone to cancerous change. Haematomas are multiple in half of all cases; ten per cent are connected with Peutz-Jegher's syndrome. Other associated conditions include juvenile polyposis, Cowden's syndrome, and Cronkhite-Canada syndrome[10]. Lymphatic tumors (lymphangiomas) are luminal swellings consisting of multiple lymphatic channels. They are usually asymptomatic and universally benign[3].

Fibromas account for nine per cent of all benign small bowel lesions. Their incidence increases with age. They can be solitary or multiple, in which case they are usually found within the terminal ileum[3]. Although fibromas tend to be asymptomatic, they can cause bleeding, obstruction, and intussusception. Their exact etiology and pathogenesis is unknown. The development of fibromatosis can either be inherited (in an autosomal dominant manner) or sporadic (related to environmental exposure to estrogens, abdominal trauma, or operative intervention).

Neurofibromas are the commonest type of neurogenic tumor; they can be sporadic or associated with neurofibromatosis. Some 12 to 25% of patients with neurofibromatosis have small bowel lesions[3]. Tumors are found along the anti-mesenteric border of the bowel and are smooth firm nodules ranging from 1 to 20 cm in size. Most lesions are benign, but 10 to 15% show sarcomatous change.

Malignant Neoplasms

More than 60% of all small intestinal tumors are malignant; they include neuroendocrine tumor (44%), adenocarcinoma (33%), lymphoma (15%), and gastrointestinal stromal tumor (7%)[10,17,24].

Neuroendocrine tumors

By far the commonest subtype is carcinoid. Duodenal gastrinoma is very uncommon and somatostatinoma even rarer.

Carcinoid

The incidence of small bowel carcinoid is only seven per million[25], but this is the site of origin for 20 to 50% of all carcinoid tumors[3,7]. They originate from neoplastic proliferations of enterochromaffin or Kulchitsky cells, which predominate in the gastrointestinal tract[26]. Most commonly, they develop in the appendix, followed by the ileum, jejunum, rectum, and duodenum[16]. Most small-bowel carcinoids arise within one meter of the ileocaecal valve[2]. They are aggressive tumors: lesions greater than 2 cm in size are commonly (80-90%) associated with metastases and frequently give rise to carcinoid syndrome (flushing, diarrhea, bronchial obstruction, and right-sided heart failure)[25-27]. Up to one third of carcinoid patients have multiple tumors; they are also at risk of a second GI malignancy whether gastric, colorectal or pancreatic[28].

Gastrinomas

Gastrinomas typically arise from the pancreas, although up to forty per cent are found in the duodenum and they can rarely arise from the jejunum[29]. Lesions are typically small, measuring less than 2 cm in diameter, and half secrete other peptides in addition to gastrin. One third of gastrinomas are associated with multiple endocrine neoplasia syndrome type 1 (MEN-1), when they are usually multiple. Approximately half of all duodenal gastrinomas are associated with lymph node involvement and thus require pancreatoduodenectomy for cure.

Somatostatinomas

Somatostatinomas are rare neuroendocrine tumors with an incidence of 1 in 40 million that typically arise in the pancreas orperi-pancreatic duodenum[11]. They can be hormonally active (and associated with somatostatinoma syndrome) or functionally inert (and then diagnosed on immunohistochemistry)[30,31]. Most somatostatinomas are sporadic, but there are well-known associations with MEN (multiple endocrine neoplasia) type 1 and neurofibromatosis type 1 (NF1)[32]. Duodenal somatostatinomas are associated with NF1 in up to 50% of patients[33,34]. There is a well-recognized association between NF1, duodenal somatostatinomas and phaeochromocytomas, so that the presence of an adrenal lesion should be sought in this group of patients[11,35,36].

Adenocarcinoma

There is a markedly uneven distribution of adenocarcinoma throughout the small bowel, with a

relative excess proximally that diminishes towards the terminal ileum[16]. Most lesions develop within the descending duodenum; origin from the duodenal cap is exceptionally rare[23]. In all, 56% of small bowel carcinomas arise from the duodenum, 16% from the jejunum, and 13% from the ileum[2]. This distribution correlates to the proximal distribution of both adenomas and bile, suggesting a possible causative effect and a likely adenoma-adenocarcinoma sequence of progression[23]. Lesions associated with Crohn's disease occur mostly in the ileum. Multiple carcinomas affect 15 to 25% of patients, and the adjacent mucosa may show evidence of dysplasia[10,23].

Gross appearances are varied: periampullary lesions are circumscribed and polypoid. Adenocarcinomas arising from other locations are usually large, annular, constricting and centrally ulcerated, with circumferential involvement of the intestinal wall[2,16]. Microscopically they are similar to their colonic counterparts, but with a higher proportion of poorly differentiated tumors and mucin secretion[10]. Mutations in APC, K-ras and p53 have all been demonstrated in small bowel lesions, but APC mutations are uncommon (unlike colonic cancer)[37]. Patients with small bowel carcinoma are at increased risk of developing large bowel carcinoma and vice versa, possibly due to defects in DNA mismatch repair genes[2,38].

Malignant spread is common by the time the carcinoma presents, with over half of all patients having metastases. This fact accounts for the poor 5-year survival rates of 25 to 30%[28]. Regional lymph nodes are typically involved, but transcoelomicspread and hepatic metastases are seen. Elderly patients may have multiple distant sites of disease, which typically cause more symptoms than the primary[39]. Individuals seem to become more susceptible to small bowel cancer as they age, whether due to lack of gene repair mechanisms or an unstable gene (or genes)[39].

Gastrointestinal stromal tumors (GISTs)

GISTs are the commonest mesenchymal neoplasms of the gastrointestinal tract. They were formally known as leiomyomas and leiomosarcomas because lightmicroscopy suggested smooth muscle differentiation. They are found predominantly within the stomach (70%), but can occur throughout the GI tract. There are occasional reports of GISTs arising in the omentum, mesentery, and retoperitoneum[40]. Within the small bowel, there is a predilection for the jejunum.

GISTs arise from the muscularis propria and may extend intraluminally, extraluminally or both (producing a characteristic 'dumb-bell' shape)[41]. Although lesions can be benign, they are best considered malignant as even small lesions can metastasize. Predictors for malignant potential include size (lesions >5 cm diameter), mitotic count (>5 mitoses per 10 high-powered microscopy fields) and Ki-67 index[2]. Macroscopically GISTs are dome-shaped and submucosal, with or without central ulceration[2]. They may become large, fungating tumors that involve surrounding organs.

Lymphomas

The small intestine contains an abundant amount of lymphoid tissue, which may become a focus of malignant transformation. Primary gastrointestinal lymphomas are uncommon in Western countries, accounting for a mere 2 to 5% of all gastrointestinal cancers[16]. Lymphomas account for 15 to 20% of all small intestinal neoplasms and 20 to 30% of all primary GI lymphomas[2]. Ileum is the most common site (60-65%), followed by jejunum (20-25%), and duodenum (6-8%)[42].

Since the gut is the commonest site for extranodal disease, secondary lymphoma of the gastrointestinal tract is ten times more likely than primary lymphoma[16]. Within the small intestine, the ileum is the preferential site for primary lymphoma. These tumors are generally large at presentation, with lymph node involvement in about half the cases[16]. Most primary tumors arise from mucosa-associated lymphoid tissue (MALT)[43]. Lymphomas can be subdivided into: 'Western', enteropathy-associated, 'Mediterranean' and lymphomatosis polyposis. Macroscopically lesions are polypoid, ulcerative (structuring, non-stricturating or aneurysmal), multiple lymphomatous polyposis, or diffuse[2].

Western lymphomas

These tumors are mainly seen in Europe and the USA. They are discrete lesions arising in a segment of bowel that was previously free of mucosal damage[16]. Lymphomas are usually solitary, but can be multiple in up to 20% of cases[43]. The lesions are generally localized and annular, but can be diffuse and infiltrative. Most tumors are classified as B-cell lymphomas, and both high- and low-grade variants exist[2].

Enteropathy-associated T-cell lymphomas

Primary intestinal T-cell lymphomas account for 5% of all primary gastrointestinal lymphomas

and are mostly associated with coeliac disease[44]. Thirty per cent of all small bowel lymphomas arise in patients with coeliac disease, generally in patients with a long history of enteropathy. Tumors may be single or multiple, often extending into the mesentery and mesenteric lymph nodes.

Mediterranean lymphomas

These tumors commonly arise among lower socio-economic groups in the Mediterranean region and the Middle East, especially in young men aged 10 to 30 years[16]. They are associated with diffuse plasma cell infiltration of the small bowel (IPSID). The early stage of this disease process is characterized by plasma cell infiltration of the small intestine and synthesis of an abnormal α-immunoglobulin heavy chain. These heavy-chain immunoglobulins can 'spill over' into the blood, urine, and jejunal juice, and can thus be detected by techniques such as gel-electrophoresis. As the disease progresses, an immunoblastic lymphoma infiltrates the small intestine or forms discrete tumors[16].

Lymphomatous polyposis

This rare form of B-cell lymphoma particularly affects the elderly. Multiple tumor nodules develop throughout the gut between pylorus and rectum.

Secondary Malignancies

The small bowel can be affected by metastatic deposits in carcinomatosisperitonei (producing serosal deposits), and in certain primary cancers, notably lung, breast, colorectum and prostate (which are associated with deposits within the intestinal wall) (Fig. 3). Primary intestinal melanomas can occur, but metastatic lesions are much more likely[3].

Investigation

Investigation of small bowel tumors depends on the clinical symptoms and general health of the patient. Abdominal pain is usually investigated with ultrasonography and computed tomography (CT), while weight loss and diarrhea lead to endoscopic assessment. The extent of investigation in patients with bleeding depends upon their cardiovascular stability as well as local expertise.

Biochemical and hematological assessment

There are no diagnostic blood tests, yet routine full blood count, liver function tests, urea and electrolytes and clotting screen should be performed to check for any derangement in organ function. Chromogranin A and pancreatic polypeptide are elevated in 50-80% of neuroendocrine tumors[11]. Although elevated plasma somatostatin levels (SLI) are strongly indicative of somatostatinoma, they are rarely found[11].

Radiology

Plain abdominal film radiographs and ultrasonography are of limited benefit except to reveal small bowel obstruction. The sensitivity of cross-sectional imaging, with oral contrast, reflects the size of the lesion; tumors <1 cm in diameter are usually missed[14]. Dual phase CT and MRI have equivalent sensitivities for the detection of small bowel tumors; CT may be better for detecting peritoneal and mesenteric disease than MRI, which is more sensitive for detecting liver and bony metastases. Hypervascular lesions, i.e. neuroendocrine tumors, and bleeding lesions may enhance with intravenous contrast. Angiography can also be used, but small bowel series and enteroclysis provide more information about mucosal lesions within the small bowel.

Barium contrast studies have been the mainstay of imaging the small bowel. Contrast series have traditionally relied on the follow-through technique, but higher diagnostic yields are obtained following duodenal intubation and small bowel enema (enteroclysis), although this is less comfortable for the patient[15,45,46]. Contrast studies can detect ulceration, masses, and intussusception, although they cannot visualize the mucosal lining directly. Diagnostic yields of 30 to 44% have been reported with contrast studies[47], increasing to 90% with conventional enteroclysis[48].

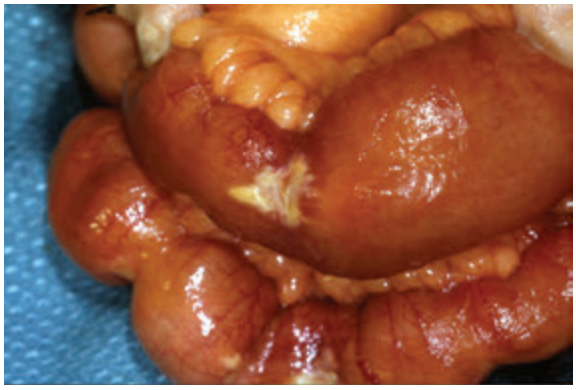

Fig. 3 Metastasis from carcinoma of breast to the wall of the mid small bowel.

Computed tomography enteroclysis (CTE) and magnetic resonance enteroclysis (MRE) are emergent techniques to assess the small bowel, both intraluminally and extraluminally. The small bowel is intubated nasally, and contrast is given to distend the bowel; both resolution and patient tolerance are superior than with standard enteroclysis[2]. Sensitivity rates of 100% for CTE and 95% for MRE have been reported for tumor detection and other small bowel pathology[49,50]. Both techniques detect mucosal changes, cavitation, or thickening of the intestinal wall, plus related changes in lymph nodes, mesentery, and its vessels and adjacent organs[2,49]. Therefore, these modalities can directly influence preoperative staging and subsequent management plan. CTE is able to detect lesions of 5 mm in diameter or greater, as opposed to 10 mm for standard CT[14].

Nuclear medicine imaging

There are several techniques for identifying and classifying neuroendocrine lesions of the small intestine. Somatostatin receptor scintigraphy (SRS) relies on the overexpression of somatostatin receptors by neuroendocrine tumors. Thus whole body scanning using radiolabelled somatostain analogues (for example, ^{111}IN-DTPA-octreotide) will detect the primary lesion and the presence of any distant metastases, with an overall sensitivity of 80 to 90%[30,32,51-53]. These scans cannot provide information on tumor size or resectability[30]. Somatostatin receptor scintigraphy combined with computed tomography (SPECT) is more sensitive than conventional imaging for detection of both primary neuroendocrine tumor and its metastases[52]. Seventy percent of primary lesions and more than ninety per cent of distant disease can be detected with SPECT[52]. Positron emission tomography (PET) scanning has greater sensitivity than either SRS or conventional cross-sectional imaging[51] and is becoming increasingly employed for the detection of all neuroendocrine tumors[30].

Endoscopy

Conventional

The small bowel is relatively inaccessible to traditional endoscopic means, though duodenoscopy can reach the distal duodenum and colonoscopy the terminal ileum. Upper GI endoscopy can be combined with endoscopic ultrasound to detect lesions as small as 0.5 cm and allow for fine needle aspirates to be taken[54]. Endoscopic retrograde cholangiopancreatography can reveal peri-ampullary lesions and allow either brush cytology or biliary stenting.

Push enteroscopy

Push enteroscopy involves the use of an overtube to splint the endoscope within the stomach to achieve insertion depths of up to 150 cm beyond the ligament of Treitz[55,56]. Although it is non-invasive, it is associated with considerable discomfort to the patient and has a relatively high risk of injury compared to standard endoscopy. Diagnostic yields can be 40-50%, but most of these lesions lie within the reach of an 'ordinary' endoscope suggesting that lesions are sometimes overlooked. Thus push enteroscopyhas generally been superseded by other investigations.

Capsule endoscopy

This technique involves swallowing a small (26 mm) capsule containing a camera, light source, and a transmitter. Two images per second are taken and are uploaded to provide visualization of the entire small bowel (in 80% of cases)[55,56]. The procedure is well tolerated, but the capsule can become stuck in areas of stenosis (which inadvertently assists in locating pathology at subsequent operation); capsule retention occurs in 1.4% of patients[57]. Diagnostic yields of up to 80% have been reported, though therapeutic interventions cannot be performed[57,58].

Double-balloon endoscopy

This technique also utilizes an overtube, but it is combined with two balloons, one attached to the endoscope, and one to the overtube. By alternate insufflation of the balloons and advancement of the endoscope, the whole intestine can be visualized following oral and anal intubation in 86% of cases[59-61]. Double-balloon endoscopy has a diagnostic rate of 75% and allows therapeutic intervention or biopsy to be taken[59-61].

Operative

Although seldom employed as a first-line investigation, operative assessment of the small bowel via laparoscopy or laparotomy can be useful, especially in unstable patients with an obscure hemorrhage[45]. Visualization and manipulation of the small intestine should reveal any abnormal pathology, with selective use of intraoperative enteroscopy if luminal assessment is required. Sometimes small bowel lesions are detected incidentally at laparoscopy or laparotomy for another intra-abdominal pathology.

Management

The exact management of small intestinal tumors depends up their size, etiology, and the extent of any metastases. Although operative intervention is recommended for most tumor types, benign lesions and lymphomas may be suitable for non-operative management.

Endoscopic

Benign lesions may be simply observed, but small polypoid lesions are amenable to endoscopic removal. This procedure is easier for duodenal polyps, but the increasing use of small bowel endoscopy means that polypectomy can potentially be performed for any intestinal lesion.

Chemotherapy

Chemotherapy is considered the best treatment regime for small bowel lymphomas, and it and can play an adjunctive role in the management of other malignant lesions. The role of chemotherapy in treating adenocarcinoma of the small bowel is unclear. Neuroendocrine tumors do not respond well to oncological agents, because they are slow-growing and thus have an inherent resistance to therapies targeted at rapidly-dividing cells. Chemotherapeutic agents include streptozotocin, doxorubicin, 5-FU, temozolomide, dacarbazine, and chlorozotocin. Of these drugs, streptozotocin is thought to be the most effective, with response rates as high as 70% at the expense of an appreciable toxicity[11].

Radiotherapy

This is not usually suitable due to the location of the primary tumor and associated lymphatic spread, but it can provide symptom relief for bony metastases.

Somatostatin analogues

Neuroendocrine tumors that are not amenable to operative resection can be treated with somatostatin analogues. Up to 90% of neuroendocrine tumors express somatostatin receptors, which makes them a therapeutic target. Agents such as octreotide, octreotate, edotreotide, and lanreotide can control symptoms by acting on somatostatin receptors to stimulate the inhibitory effects of somatostatin[11]. They also have tumoristatic effect in 40 to 80% of patients and increase progression-free survival for midgut neuroendocrine tumors[11,51].

Radiolabelled somatostatin analogues (with attached radionuclides of ^{177}lutrium, ^{90}ytrium, or ^{111}indium) can deliver localized γ-radiation or β-radiation to the neuroendocrine tumor, thus decreasing overall radiation exposure to the patient[62]. No randomized controlled studies exist, but several studies have reported favorable response rates. Of all the agents commercially available [^{177}Lu-DOTA^{0}, Tyr3]octreotate (DOTATATE) has showed a complete response rate in 2% of patients, a partial response in 32%, and stabilization of disease in 34%[63]. Overall, median survival rates with DOTATATE of more than 40 months have been reported[63].

Operative

Periampullary lesions usually require proximal pancreatoduodenectomy, whereas lesions in the distal duodenum or beyond may be amenable to a local wedge resection[64]. Benign lesions (that are unresectable endoscopically) may be amenable to enterotomy and excision. Generally, operative intervention is avoided where there is local invasion or metastatic disease, unless the pathology is a neuroendocrine tumor. Patients who present with obstruction may be suitable for endoscopic stenting (in proximal duodenum) or for a palliative by pass for symptom relief.

For neuroendocrine tumors, operative intervention is recommended in almost all patients, even those with metastatic disease. Non-curative resection of the primary tumor in the presence of hepatic metastases is associated with a 30% improvement in five-year survival[65-67]. Debulking of the primary tumor (removing at least 90% of the volume) can improve symptoms associated with tumor mass, i.e. pain and vomiting; up to half the patients report benefit for a mean duration of 39 months[65-67]. Aggressive resection of liver metastases is associated with better long-term outcomes than non-operative intervention such as hepatic artery embolization (HAE), radiofrequency ablation, or radioactive octreotide[11]. Complete resection of hepatic metastases improves survival threefold compared with incomplete resection[68]. For young, otherwise healthy patients, liver transplantation for widespread hepatic metastatic infiltration should be considered, especially if symptoms cannot be managed by other means[51].

Survival

Survival is highly dependent upon tumor type, although prognosis is generally poor due to late diagnosis. Following curative resection, 5-year survivals of 0 to 40% have been reported for adenocarcinoma and up to 60% for neuroendocrine

tumors; following chemotherapy 5-year survival rates of between 14 to 30% for lymphomas have been reported[14,23].

Surveillance

Patients with conditions that predispose to small bowel cancer might benefit from surveillance, especially those with familial and non-familial polyposis syndromes. Periampullary polyps can quite often be detected endoscopically. Their risk of malignant transformation reflects not only the underlying syndrome (e.g. FAP) but also the number, size, histology and degree of dysplasia[18,20]. Peutz-Jeghers syndrome patients should have routine endoscopic screening of the upper GI tract and colon every two-to-three years from the age of 18, primarily to prevent intussusception and the need for emergency laparotomy. No data exist for routine screening of patients with coeliac or Crohn's disease. However, investigation should be considered in those with long-standing disease or those with strictures that do not respond to medical therapy.

Potential conflicts of interest

None.

References

1. Jemal A, Thomas A, Murray T, Thun M. Cancer statistics, 2002. CA Cancer J Clin 2002; 52: 23-47.
2. Cheung DY, Choi MG. Current advance in small bowel tumors. Clin Endosc 2011; 44: 13-21.
3. Chow JS, Chen CC, Ahsan H, Neugut AI. A population-based study of the incidence of malignant small bowel tumors: SEER, 1973-1990. Int J Epidemiol 1996; 25: 722-8.
4. Severson RK, Schenk M, Gurney JG, Weiss LK, Demers RY. Increasing incidence of adenocarcinomas and carcinoid tumors of the small intestine in adults. Cancer Epidemiol Biomarkers Prev 1996; 5: 81-4.
5. Cheung DY, Lee IS, Chang DK, Kim JO, Cheon JH, Jang BI, et al. Capsule endoscopy in small bowel tumors: a multicenter Korean study. J Gastroenterol Hepatol 2010; 25: 1079-86.
6. Rondonotti E, Pennazio M, Toth E, Menchen P, Riccioni ME, De Palma GD, et al. Small-bowel neoplasms in patients undergoing video capsule endoscopy: a multicenter European study. Endoscopy 2008; 40: 488-95.
7. Hatzaras I, Palesty JA, Abir F, Sullivan P, Kozol RA, Dudrick SJ, et al. Small-bowel tumors: epidemiologic and clinical characteristics of 1260 cases from the connecticut tumor registry. Arch Surg 2007; 142: 229-35.
8. Neugut AI, Jacobson JS, Suh S, Mukherjee R, Arber N. The epidemiology of cancer of the small bowel. Cancer Epidemiol Biomarkers Prev 1998; 7: 243-51.
9. Ciresi DL, Scholten DJ. The continuing clinical dilemma of primary tumors of the small intestine. Am Surg 1995; 61: 698-702.
10. Herbsman H, Wetstein L, Rosen Y, Orces H, Alfonso AE, Iyer SK, et al. Tumors of the small intestine. Curr Probl Surg 1980; 17: 121-82.
11. Williamson JM, Thorn CC, Spalding D, Williamson RC. Pancreatic and peripancreatic somatostatinomas. Ann R Coll Surg Engl 2011; 93: 356-60.
12. Negri E, Bosetti C, La Vecchia C, Fioretti F, Conti E, Franceschi S. Risk factors for adenocarcinoma of the small intestine. Int J Cancer 1999; 82: 171-4.
13. Ryan JC. Premalignant conditions of the small intestine. Semin Gastrointest Dis 1996; 7: 88-93.
14. Anzidei M, Napoli A, Zini C, Kirchin MA, Catalano C, Passariello R. Malignant tumors of the small intestine: a review of histopathology, multidetector CT and MRI aspects. Br J Radiol 2011; 84: 677-90.
15. Kingham JG, Ramanaden D, Dawson A. Metachronous small-bowel adenocarcinoma in coeliac disease: gluten-free diet is not protective. Scand J Gastroenterol 1998; 33: 218-22.
16. Misiewicz JJ, Bartram CI, Cotton PB, Mee AS, Price AB, Thompson RPH. Diseases of the small intestine, pancreas and colon: guide to diagnosis. Gastroenterolgy, volume 2. London: Gower Medical Publishing; 1987.
17. Spigelman AD, Murday V, Phillips RK. Cancer and the Peutz-Jeghers syndrome. Gut 1989; 30: 1588-90.
18. Westerman AM, Wilson JH. Peutz-Jeghers syndrome: risks of a hereditary condition. Scand J Gastroenterol Suppl 1999; 230: 64-70.
19. Reid JD. Intestinal carcinoma in the Peutz-Jeghers syndrome. JAMA 1974; 229: 833-4.
20. Bülow S, Björk J, Christensen IJ, Fausa O, Jarvinen H, Moesgaard F, et al. Duodenal adenomatosis in familial adenomatous polyposis. Gut 2004; 53: 381-6.
21. Gao C, Wang AY. Significance of increased apoptosis and Bax expression in human small

intestinal adenocarcinoma. J Histochem Cytochem 2009; 57: 1139-48.
22. Bilimoria KY, Bentrem DJ, Wayne JD, Ko CY, Bennett CL, Talamonti MS. Small bowel cancer in the United States: changes in epidemiology, treatment, and survival over the last 20 years. Ann Surg 2009; 249: 63-71.
23. Scott-Coombes DM, Williamson RC. Surgical treatment of primary duodenal carcinoma: a personal series. Br J Surg 1994; 81: 1472-4.
24. Yang YS, Huang QY, Wang WF, Sun G, Peng LH. Primary jejunoileal neoplasmas: a review of 60 cases. World J Gastroenterol 2003; 9: 862-4.
25. Neary PC, Redmond PH, Houghton T, Watson GR, Bouchier-Hayes D. Carcinoid disease: review of the literature. Dis Colon Rectum 1997; 40: 349-62.
26. Kaltsas GA, Besser GM, Grossman AB. The diagnosis and medical management of advanced neuroendocrine tumors. Endocr Rev 2004; 25: 458-511.
27. Williamson JML, Spalding DRC. Surgical resection of hepatic and cardiac neuroendocrine metastases from a caecal primary tumor. Ann R Coll Surg Engl. In press 2013.
28. Dabaja BS, Suki D, Pro B, Bonnen M, Ajani J. Adenocarcinoma of the small bowel: presentation, prognostic factors, and outcome of 217 patients. Cancer 2004; 101: 518-26.
29. Kaplan EL, Horvath K, Udekwu A, Straus F, Schark C, Ferguson DJ, et al. Gastrinomas: a 42-year experience. World J Surg 1990; 14: 365-75.
30. Vinik AI, Woltering EA, Warner RR, Caplin M, O'Dorisio TM, Wiseman GA, et al. NANETS consensus guidelines for the diagnosis of neuroendocrine tumor. Pancreas 2010; 39: 713-34.
31. Kloppel G. Tumor biology and histopathology of neuroendocrine tumors. Best Pract Res Clin Endocrinol Metab 2007; 21: 15-31.
32. Oberg K, Eriksson B. Endocrine tumors of the pancreas. Best Pract Res Clin Gastroenterol 2005; 19: 753-81.
33. Doherty GM. Rare endocrine tumors of the GI tract. Best Pract Res Clin Gastroenterol 2005; 19: 807-17.
34. Mao C, Shah A, Hanson DJ, Howard JM. Von Recklinghausen's disease associated with duodenal somatostatinoma: contrast of duodenal versus pancreatic somatostatinomas. J Surg Oncol 1995; 59: 67-73.
35. Soga J, Yakuwa Y. Somatostatinoma/inhibitory syndrome: a statistical evaluation of 173 reported cases as compared to other pancreatic endocrinomas. J Exp Clin Cancer Res 1999; 18: 13-22.
36. Cappelli C, Agosti B, Braga M, Cumetti D, Gandossi E, Rizzoni D, et al. Von Recklinghausen's neurofibromatosis associated with duodenal somatostatinoma. A case report and review of the literature. Minerva Endocrinol 2004; 29: 19-24.
37. Arai M, Shimizu S, Imai Y, Nakatsuru Y, Oda H, Oohara T, et al. Mutations of the Ki-ras, p53 and APC genes in adenocarcinomas of the human small intestine. Int J Cancer 1997; 70: 390-5.
38. Neugut AI, Santos J. The association between cancers of the small and large bowel. Cancer Epidemiol Biomarkers Prev 1993; 2: 551-3.
39. Ripley D, Weinerman BH. Increased incidence of second malignancies associated with small bowel adenocarcinoma. Can J Gastroenterol 1997; 11: 65-8.
40. Kavaliauskiene G, Ziech ML, Nio CY, Stoker J. Small bowel MRI in adult patients: not just Crohn's disease-a tutorial. Insights Imaging 2011; 2: 501-13.
41. Lev D, Kariv Y, Issakov J, Merhav H, Berger E, Merimsky O, et al. Gastrointestinal stromal sarcomas. Br J Surg 1999; 86: 545-9.
42. Schottenfeld D, Beebe-Dimmer JL, Vigneau FD. The epidemiology and pathogenesis of neoplasia in the small intestine. Ann Epidemiol 2009; 19: 58-69.
43. Pandey M, Wadhwa MK, Patel HP, Kothari KC, Shah M, Patel DD. Malignant lymphoma of the gastrointestinal tract. Eur J Surg Oncol 1999; 25: 164-7.
44. Lavergne A, Brocheriou I, Delfau MH, Copie-Bergman C, Houdart R, Gaulard PH. Primary intestinal gamma-delta T-cell lymphoma with evidence of Epstein-Barr virus. Histopathology 1998; 32: 271-6.
45. Williamson JML, Williamson RCN. Mid-gastrointestinal bleeding: A Western Perspective. In: Nundy S, Sahni P. ECAB clinical update. Surgical gastroenterology and liver transplantation: gastrointestinal haemorrhage. New Delhi: Elsevier; 2012: 67-75.
46. Garbrecht N, Anlauf M, Schmitt A, Henopp T, Sipos B, Raffel A, et al. Somatostatin-producing neuroendocrine tumors of the duodenum and pancreas: incidence, types, biological behavior, association with inherited syndromes, and functional activity. Endocr Relat Cancer 2008; 15:

229-41.
47. Ekberg O, Ekholm S. Radiography in primary tumors of the small bowel. Acta Radiol Diagn (Stockh) 1980; 21: 79-84.
48. Bessette JR, Maglinte DD, Kelvin FM, Chernish SM. Primary malignant tumors in the small bowel: a comparison of the small-bowel enema and conventional follow-through examination. Am J Roentgenol 1989; 153: 741-4.
49. Maglinte DD, Bender GN, Heitkamp DE, Lappas JC, Kelvin FM. Multidetector-row helical CT enteroclysis. Radiol Clin North Am 2003; 41: 249-62.
50. Van Weyenberg SJ, Meijerink MR, Jacobs MA, Van der Peet DL, Van Kuijk C, Mulder CJ, et al. MR enteroclysis in the diagnosis of small-bowel neoplasms. Radiology 2010; 254: 765-73.
51. Kulke MH, Anthony LB, Bushnell DL, de Herder WW, Goldsmith SJ, Klimstra DS, et al. NANETS treatment guidelines: well-differentiated neuroendocrine tumors of the stomach and pancreas. Pancreas 2010; 39: 735-52.
52. Gibril F, Jensen RT. Diagnostic uses of radiolabelled somatostatin receptor analogues in gastroenteropancreatic endocrine tumors. Dig Liver Dis 2004; 36 (Suppl 1): S106-20.
53. Termanini B, Gibril F, Reynolds JC, Doppman JL, Chen CC, Stewart CA, et al. Value of somatostatin receptor scintigraphy: a prospective study in gastrinoma of its effect on clinical management. Gastroenterology 1997; 112: 335-47.
54. O'Grady HL, Conlon KC. Pancreatic neuro-endocrine tumors. Eur J Surg Oncol 2008; 34: 324-32.
55. Liu K, Kaffes AJ. Review article: the diagnosis and investigation of obscure gastrointestinal bleeding. Aliment Pharmacol Ther 2011; 34: 416-23.
56. Barkin JS, Chong J, Reiner DK. First-generation video enteroscope: fourth-generation push-type small bowel enteroscopy utilizing an overtube. Gastrointest Endosc 1994; 40: 743-7.
57. Heil U, Jung M. The patient with recidivent obscure gastrointestinal bleeding. Best Pract Res Clin Gastroenterol 2007; 21: 393-407.
58. Liao Z, Gao R, Xu C, Li ZS. Indications and detection, completion, and retention rates of small-bowel capsule endoscopy: a systematic review. Gastrointest Endosc 2010; 71: 280-6.
59. Yamamoto H, Kita H, Sunada K, Hayashi Y, Sato H, Yano T, et al. Clinical outcomes of double-balloon endoscopy for the diagnosis and treatment of small-intestinal diseases. Clin Gastroenterol Hepatol 2004; 2: 1010-6.
60. Manabe N, Tanaka S, Fukumoto A, Nakao M, Kamino D, Chayama K. Double-balloon enteroscopy in patients with GI bleeding of obscure origin. Gastrointest Endosc 2006; 64: 135-40.
61. Pasha SF, Leighton JA, Das A, Harrison ME, Decker GA, Fleischer DE, et al. Double-balloon enteroscopy and capsule endoscopy have comparable diagnostic yield in small-bowel disease: a meta-analysis. Clin Gastroenterol Hepatol 2008; 6: 671-6.
62. Kam BL, Teunissen JJ, Krenning EP, de Herder WW, Khan S, van Vliet EI, et al. Lutetium-labelled peptides for therapy of neuroendocrine tumors. Eur J Nucl Med Mol Imaging 2012; 39 (Suppl 1): S103-12.
63. Kwekkeboom DJ, de Herder WW, Kam BL, van Eijck CH, van Essen M, Kooij PP, et al. Treatment with the radiolabeled somatostatin analog [^{177}Lu-DOTA^{0},Tyr3]octreotate: toxicity, efficacy, and survival. J Clin Oncol 2008; 26: 2124-30.
64. Spalding DR, Isla AM, Thompson JN, Williamson RC. Pancreas-sparing distal duodenectomy for infrapapillary neoplasms. Ann R Coll Surg Engl 2007; 89: 130-5.
65. Chamberlain RS, Canes D, Brown KT, Saltz L, Jarnagin W, Fong Y, et al. Hepatic neuroendocrine metastases: does intervention alter outcomes? J Am Coll Surg 2000; 190: 432-45.
66. Norton JA. Endocrine tumors of the gastrointestinal tract. Surgical treatment of neuroendocrine metastases. Best Pract Res Clin Gastroenterol 2005; 19: 577-83.
67. Que FG, Sarmiento JM, Nagorney DM. Hepatic surgery for metastatic gastrointestinal neuroendocrine tumors. Adv Exp Med Biol 2006; 574: 43-56.
68. Chen H, Hardacre JM, Uzar A, Cameron JL, Choti MA. Isolated liver metastases from neuroendocrine tumors: does resection prolong survival? J Am Coll Surg 1998; 187: 88-93.