

## Special Article

# Surgical Treatment of Epilepsy: Principles and Presurgical Evaluation

Bunpot Sitthinamsuwan MD, MSc<sup>\*,\*\*</sup>,  
Sarun Nunta-aree MD, PhD<sup>\*,\*\*</sup>

<sup>\*</sup>Division of Neurosurgery, Department of Surgery, Faculty of Medicine Siriraj Hospital, Mahidol University, Bangkok, Thailand

<sup>\*\*</sup>Siriraj Epilepsy Surgery Program, Faculty of Medicine Siriraj Hospital, Mahidol University, Bangkok, Thailand

---

**Background:** A significant number of epileptic patients suffer from medically refractory epilepsy. Epilepsy surgery is considered an appropriate option for management in such cases.

**Objective:** The surgery endeavors to eradicate disabling seizures with preservation of important neurologic function and improve long-term quality of life.

**Material and Method:** The authors reviewed medical literatures and researches in regard to principles and presurgical evaluation of epilepsy surgery.

**Results:** The major concept in surgical therapy for epilepsy is complete resection or disconnection of the epileptogenic zone, which renders the patients seizure-free. Various diagnostic strategies can be comprehensively employed to delineate the epileptogenic zone and to identify the individual at risk for postoperative neurologic morbidity. From a surgical point of view, operative approaches for epilepsy can be categorized into resective surgery and functional surgery. Resectiver surgery aims to render the patients seizure-free, whereas functional procedure purposes to relieve frequency and severity of disabling seizures. Presurgical evaluation should be conducted by a specialized multidisciplinary team.

**Conclusion:** Several diagnostic measures and investigations involved in epilepsy surgery will be described in the article. Major steps of preoperative assessment and management algorithm for medically intractable epileptic individuals will be demonstrated as well.

**Keywords:** Epilepsy surgery, Seizure, Epileptogenic zone, Presurgical evaluation

*J Med Assoc Thai* 2013; 96 (1): 121-31

Full text. e-Journal: <http://jmat.mat.or.th>

---

Poorly controlled epilepsy carries significant risk of morbidity and mortality<sup>(1)</sup>. Early management in the course of epilepsy can prevent disastrous effects of prolonged epilepsy and ameliorate quality of life for the long-term<sup>(2)</sup>. In the course of treatment, approximately 30 to 40% of patients with epilepsy develop medically intractable epilepsy<sup>(3-5)</sup>. Among individuals harboring refractory epileptic disorders, surgical therapy should be considered.

Epilepsy surgery is an effective, safe, and successful therapeutic option for patients with medically intractable epilepsy who have impaired quality of life because of seizures or the adverse effects of antiepileptic medication<sup>(4,6-10)</sup>. Patients who suffer from remediable epileptic syndrome are surgical candidates for epilepsy surgery. The syndrome

includes mesial temporal lobe epilepsy (MTLE), localization-related epilepsy associated with well-defined lesions, indolent neoplasms, malformation of cortical development (MCD), post-traumatic or post-hemorrhagic scar and infantile or childhood hemispheric disorders<sup>(1,11)</sup>. Resectiver surgery in such cases usually results in favorable outcome.

Surgical therapy of epilepsy has been gradually developed for several years in Thailand; however, a considerable number of patients with medically intractable epilepsy have been inappropriately evaluated. If they are correctly treated, some of them can be seizure-free after the surgery. The authors reviewed relevant medical literatures concerning principles and presurgical evaluation of epilepsy surgery.

## Principles

The major operative strategy for treating refractory epilepsy includes complete resection or disconnection of the epileptogenic zone to accomplish seizure-free and preservation of the significant brain

---

### Correspondence to:

Sitthinamsuwan B, Division of Neurosurgery, Department of Surgery, Faculty of Medicine Siriraj Hospital, Mahidol University, Bangkok 10700, Thailand.

Phone: 0-2419-8003, 0-2419-8072, Fax: 0-2411-3006

E-mail: [bunpotsi@yahoo.com](mailto:bunpotsi@yahoo.com)

function to evade from operative morbidity<sup>(4,6,8,12,13)</sup>. The outcome following epilepsy surgery depends mainly on how perfectly the epileptogenic zone can be excised without disturbance of the eloquent brain<sup>(13)</sup>.

### Cortical zones<sup>(14-18)</sup>

The symptomatogenic zone is the cortical area that, when stimulated by epileptiform discharges, elicits the patient's habitual ictal manifestation.

The irritative zone is characterized by the cortical region generating interictal epileptiform activities on electroencephalography (EEG).

The ictal onset zone is the cortical zone from which ictal epileptiform discharges are arising. It is usually smaller than the epileptogenic zone. Thus, complete removal of the epileptogenic zone must include this ictal generating zone to achieve seizure-free condition<sup>(15)</sup>.

The epileptogenic lesion is the visible structural lesion on diagnostic neuroimaging accountable for the occurrence of seizures. Nevertheless, a visualized lesion on neuroimaging sometimes is not necessarily epileptogenic, so that confirmation of epileptogenic property of the lesion by using surface EEG is always mandatory<sup>(15)</sup>.

The functional deficit zone is the portion of the brain showing abnormal function during the interictal stage.

The epileptogenic zone is a designated theoretical zone generating seizures. It is minimum amount of cerebral cortex that has to be completely sectioned, deactivated, or disconnected to allow the patient free of seizure<sup>(14,17)</sup>. This imaginary zone cannot be directly visualized or identified by any diagnostic methods, but it can be localized by a combination of the aforementioned cortical regions.

Importantly, the epileptogenic zone may sometimes be adjacent to or overlap with the eloquent cortex (the area of cortex that, if removed, will result in a neurologic deficit or disability)<sup>(18)</sup>. The common eloquent areas include primary motor and somatosensory cortices, expressive and receptive language cortices (Broca's and Wernicke's areas, respectively), and primary visual cortex. An involvement of the eloquent brain must be clearly defined before the resective surgery by using various preoperative measures.

The cortical zones, corresponding descriptions and strategies for identifying them are summarized in Table 1.

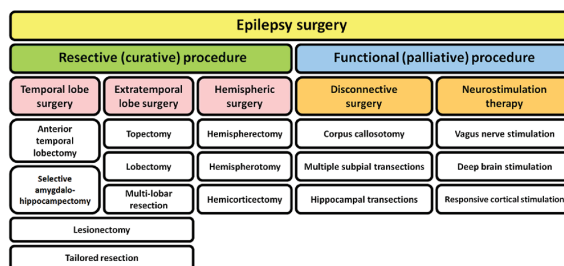


Fig. 1 Classification of surgical procedure in epilepsy surgery.

### Classification of operative procedure in epilepsy surgery

Surgical procedure involving in epilepsy surgery can be fundamentally categorized into two distinctive types: resective (curative) and functional (palliative) procedures<sup>(4,11,19,20)</sup> (Fig. 1). Resective surgery is the major operative method for treating patients with intractable focal epilepsy. It endeavors to entirely remove area of the brain containing the epileptogenic zone with preservation of the eloquent cortex<sup>(8)</sup>. This type of surgery is generally indicated in individuals agonizing from drug-resistant epilepsy caused by a focal or regional epileptogenic zone situated in the non-eloquent cerebral cortex<sup>(16,19)</sup>. Complete excision of the focal epileptogenic area always yields the best results for epilepsy surgery<sup>(21)</sup>. Among various resective procedures, surgical treatment of MTLE caused by hippocampal sclerosis is the most commonly used procedure and considered to be the operation rendering the best seizure outcome. In the surgical therapy for extratemporal epilepsy, diverse operative techniques can be opted for by relying on extent of the epileptogenic area or lesion that will be removed. Regarding to catastrophic epilepsy in hemiplegic children, ablative surgery in the pathologic cerebral hemisphere is helpful in eradication or diminishment of disabling seizures, and often results in improvement of neurodevelopmental status and quality of life.

Functional epilepsy surgery intends to modify the brain function for improving the control of epilepsy<sup>(20)</sup>. Palliative reduction of seizure frequency and severity is the major objective<sup>(11,22)</sup>. It is indicated in patients who are not realistic candidates for resective surgery<sup>(21,23)</sup>, for instance, individuals harboring multifocal or diffuse epileptogenicity<sup>(24)</sup> or who have unresectable epileptogenic brain owing to great risk of postoperative handicaps. The functional procedure can be divided into disconnective technique

**Table 1.** The cortical zones in epilepsy<sup>(14-18)</sup>

Cortical zone	Definition	Diagnostic tools
Symptomatogenic zone	The cortical region which generates the patient's habitual ictal symptoms when activated by the epileptiform discharges	Clinical history Video-EEG
Irritative zone	The cortical region which is capable of generating interictal epileptiform discharges on EEG	Interictal EEG (scalp or invasive) ECoG MEG
Ictal onset zone	The cortical region from which ictal epileptiform discharges originating	Ictal EEG (scalp or invasive) Ictal SPECT
Epileptogenic lesion	A structural neuroimaging abnormality responsible for the generation of seizures	CT MRI
Functional deficit zone	The cortical region that displays aberrant function in the interictal period	Neurological examination Neuropsychological test Wada test Interictal SPECT Interictal PET MRS
Epileptogenic zone	The theoretical zone of cerebral cortex that is able to generate seizures. Complete removal or disconnection of this zone renders the patient seizure free	Cannot be visualized directly Defined by a combination of all of above cortical zones
Eloquent cortex	The area of cerebral cortex that, if removed, will bring about a neurologic deficit	Neuropsychological test Functional MRI Wada test Invasive EEG with extraoperative or intraoperative functional brain mapping

CT = computerized tomography; ECoG = electrocorticography; EEG = electroencephalography; MEG = magnetoencephalography; MRI = magnetic resonance imaging; MRS = magnetic resonance spectroscopy; PET = positron emission computerized tomography; SPECT = single-photon emission computerized tomography

and neurostimulation therapy. The former contains the operation for disconnecting both cerebral hemispheres separately (corpus callosotomy) and isolating the epileptogenic cortex from the surrounding brain (multiple subpial transections and hippocampal transections). The major goal of disconnective surgery is to prevent spread of epileptiform activities from epileptogenic focus to the others<sup>(19)</sup>. Corpus callosotomy disrupts ictal impulse from one side of the brain to the other and vice versa. It is mainly indicated in patients with bilateral synchronous spikes on EEG study<sup>(20)</sup>, particularly in individuals with Lennox-Gastaut syndrome who suffer from atonic seizure causing frequent falls with injury<sup>(22)</sup>. Multiple subpial transections is appropriate for treating patients harboring epileptogenic brain localized in the eloquent area and who are Landau-Kleffner syndrome (acquired epileptiform aphasia)<sup>(20,22)</sup>. The neurostimulation therapy is chronic electrical stimulation of specific neural elements purposing to palliate the seizures.

Vagus nerve stimulation is a popularly used neurostimulation. A great number of patients achieve satisfactory seizure reduction following the surgery<sup>(22)</sup>. Deep brain stimulation of various targets in the brain, for example, anterior or centromedian nucleus of the thalamus, and responsive cortical stimulation are alternatives for treating patients with medically intractable epilepsy<sup>(25)</sup>.

#### Presurgical evaluation

Specialized multidisciplinary team is necessary in comprehensive epilepsy program and presurgical evaluation<sup>(16,26)</sup>. The involved specialists include epileptologists, pediatric epileptologists, neurophysiologists, neurosurgeons, neuroradiologists, psychiatrists, neuropsychologists, specialized nurses, and social workers<sup>(23)</sup>. Good selection of realistic candidates for epilepsy surgery and preoperative assessment are essential to accomplish favorable surgical outcomes<sup>(11)</sup>.

Presurgical evaluation for epilepsy surgery primarily aims to delineate the epileptogenic zone precisely and to determine the association between this zone and the adjacent or involved eloquent cerebral cortex<sup>(12,18,27,28)</sup>. Various entities of diagnostic tools are incorporated in the standard protocol of the preoperative assessment. They include detailed clinical history, physical examination, seizure semiology, interictal EEG, ictal video-EEG monitoring, neuroimaging (CT, MRI), functional neuroimaging (SPECT, PET, functional MRI), neuropsychological test, neuro-psychiatric assessment and the Wada test<sup>(22,29,30)</sup>. Identification of epilepsy patients considered the surgical candidate can be mostly based on non-invasive measures<sup>(31)</sup>. When non-invasive evaluations reveal a concordant result of the resectable epileptogenic focus, resective surgery is highly recommended and often brings about favorable outcome<sup>(28)</sup>. In contrast, individuals harboring discordant or inconclusive results require invasive studies<sup>(26)</sup>, particularly intracranial EEG monitoring. Patients who are not suitable for resective surgery will be excluded from the surgery or the functional procedures may be considered only in selected cases.

Three major steps for preoperative assessment in epilepsy surgery are comprised of the following<sup>(1)</sup>.

Step I is the non-invasive studies, including analysis of clinical data, video-EEG monitoring, high resolution MRI, functional neuroimaging (SPECT, PET, functional MRI), MEG, neuropsychological and neuropsychiatric tests and the Wada test. When non-invasive investigations reveal congruent results, the appropriate operation (step III) will be suggested. On the other hand, if results of the studies are discrepant or when further data regarding the epileptogenic zone is required, step II investigation is essential.

Step II consists of intracranial EEG recordings with or without cortical stimulation for identifying the eloquent cortex.

Step III is the selection of the most suitable definite surgical treatment for the individual patient taking into consideration the entire presurgical information.

The management algorithm in epilepsy surgery is displayed in Fig. 2.

The preoperative strategies for delineating the epileptogenic focus will be concisely described as the following.

### 1. Seizure semiology

Precise semiologic history, epileptic aura and the first ictal symptom often indicate corresponding

symptomatogenic zones. They are worthwhile in lateralizing and localizing the epileptogenic area<sup>(18,20,26,29,32,33)</sup>. Typical epileptic signs and symptoms with lateralizing or localizing values are presented in Table 2.

### 2. Surface electroencephalography (EEG)

Electroencephalographic study has a major role in defining the area of epileptogenicity<sup>(15,26)</sup>. Persistent interictal epileptiform activities (spikes, sharp waves, and spike-and-wave complexes) or rhythmic epileptic discharges demonstrated by EEG are supportive of the diagnosis of epilepsy and helpful in localization of the irritative zone<sup>(15)</sup>. Visible slow waves may imply a dysfunctional region of the brain from which seizures originate; however, their lateralizing or localizing value is less specific<sup>(24)</sup>. Long-term video-EEG recording is highly beneficial in studying seizure semiology and lateralizing or localizing the ictal onset zone<sup>(16,21)</sup> (Fig. 3). The ictal EEG onset preceding the seizure symptom indicates that the ictal onset zone can be reliably localized before the epileptiform discharges spread to the symptomatogenic zone. On the contrary, when the visible ictal semiology can be observed before the electroencephalographic onset, the ictal onset zone may be situated in the region where it cannot be identified by employing surface EEG recording, such as interhemispheric fissure or orbitofrontal cortex<sup>(15,24)</sup>. Supplementary semi-invasive electrodes, such as sphenoidal and foramen ovale electrodes, can be situated in vicinity to the mesial temporal structures. They increase opportunities in detection of interictal discharges and are often valuable for discriminating

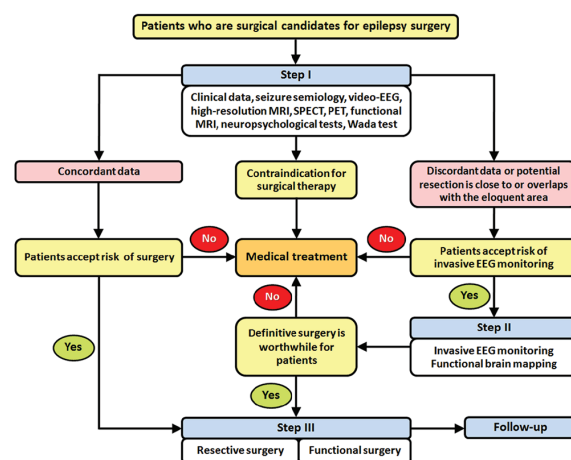


Fig. 2 The management algorithm in epilepsy surgery.

**Table 2.** Common semiologic features with lateralizing and localizing values<sup>(18,20,26,29,32,33)</sup>

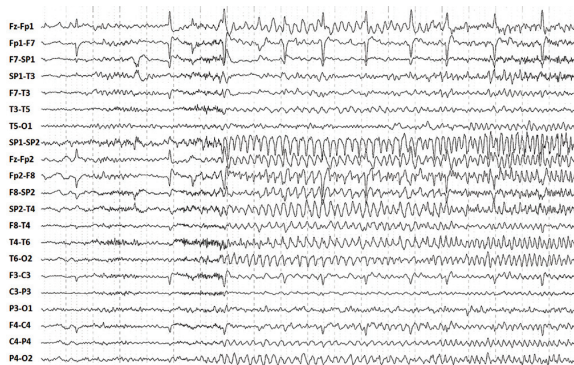
Semiologic characteristics	Lateralizing value	Localizing value
<b>Aura</b>		
Abdominal	-	Anterior insular cortex, hippocampus
Olfactory	-	Amygdala, insula, olfactory bulb
Gustatory	-	Parietal operculum, anteromedial basal temporal cortex
Auditory	Contralateral	Auditory cortex
Visual	Contralateral	Visual cortex
Somatosensory (well-defined area)	Contralateral	Primary somatosensory cortex
Somatosensory (bilateral distribution or ill-defined area)	-	Secondary somatosensory cortex, insula
Vertiginous	Frequently right	Temporoparietal junction
<b>Motor</b>		
Focal motor seizure	Contralateral	Primary motor cortex, perirolandic region, supplementary motor area
Early non-forced head turn	Ipsilateral	-
Late forced head turn	Contralateral	-
Versive eyes and head	Contralateral	Primary motor cortex, frontal eye field
Fencing posture	Contralateral	Supplementary motor area
Dystonic upper extremity	Contralateral	Basal ganglia
Postictal paresis	Contralateral	Exhaustion of primary motor cortex
<b>Automatism</b>		
Oral	Non-dominant	Temporal lobe, typically hippocampus
Unilateral limb	Ipsilateral	-
Bipedal	-	Frontal lobe
Unilateral eye blinking	Ipsilateral	Temporal lobe
Ictal salivation or drinking	Right	Temporal lobe
Ictal laughing (gelastic seizure)	-	Hypothalamus, mesial temporal lobe, anterior cingulum
Postictal nose wiping	Ipsilateral	Temporal lobe
Postictal cough	-	Temporal lobe
<b>Language</b>		
Ictal speech arrest	Dominant	Temporal lobe
Ictal speech preservation	Non-dominant	Temporal lobe
Ictal verbalization	Non-dominant	Temporal lobe
Postictal dysphasia	Dominant	-
<b>Psychic</b>		
Fear	-	Amygdala, anterior hippocampus, mesial frontal lobe
Deja vu, Jamais vu	-	Mesial and lateral temporal lobe
Complex memory	-	Mesial and lateral temporal lobe
<b>Autonomic</b>		
Ictal urinary incontinence	Right	Temporal lobe
Ictal vomiting	Non-dominant	Temporal lobe
Piloerection	Left	Temporal lobe

seizures emerging mesially from the lateral temporal neocortex<sup>(18,20)</sup> (Fig. 4).

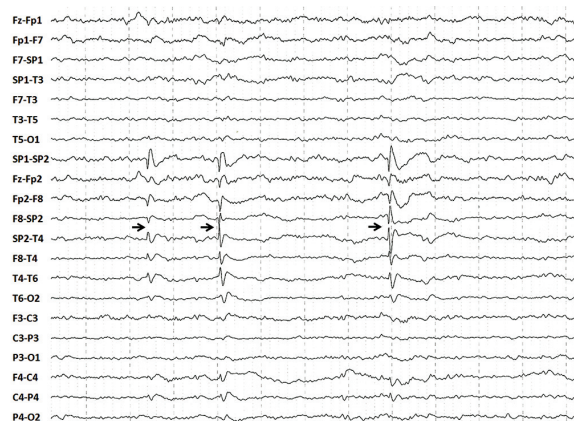
### 3. Magnetoencephalography (MEG)

MEG is analysis of the magnetic fields generated by neuronal electrical activity in the brain<sup>(16)</sup>. It has a major role not only in delineation of the epileptogenic area<sup>(22,34,35)</sup>, but also in presurgical functional localization of the eloquent cortex,

particularly the somatomotor cortex and the language relevant cortical region<sup>(34,36,37)</sup>. Localization of the epileptic cortex can be accomplished by cluster analysis of magnetic dipoles of interictal epileptiform discharges<sup>(22,38,39)</sup>. An important advantage of MEG over EEG is the absence of the smearing effect. Magnetic fields in MEG are significantly less affected by electrical conductivity of the brain surrounding tissue than electrical fields



**Fig. 3** Ictal EEG in bipolar montages demonstrates the ictal epileptiform discharges arising from the right-sided brain (even numbers of the electrodes), especially from the right anterior temporal region (F8, SP2, T4) where it is considered to be the ictal onset zone.

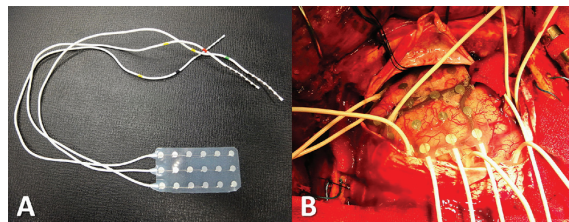


**Fig. 4** Application of sphenoidal electrode which is placed in vicinity of the mesial temporal structure more than to surface electrode. SP1 and SP2 are left and right sphenoidal electrodes, respectively. Interictal EEG in bipolar montages reveals the interictal spikes emerging from the the right anterior temporal region with maximal phase reversal on the SP2 (arrows). The maximal negativity on the SP2 indicates that the epileptic focus should be generated from the right mesial temporal area rather than the lateral temporal cortex.

in EEG<sup>(40)</sup>, MEG coregistered with MRI can facilitate the relationship between functional and structural domains<sup>(41)</sup>.

#### 4. Intracranial electroencephalography

In circumstances exhibiting discrepant results of the non-invasive investigations, absent structural



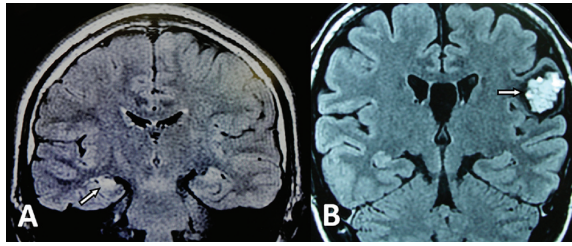
**Fig. 5** Subdural electrodes. (A) 3 x 6 contacts subdural array. (B) Direct placement of subdural electrodes on the cortical surface of the brain.

lesion on cranial MRI, seizures originating from some specific areas where ordinary surface EEG cannot detect or required functional study of the eloquent brain, intracranial electrode implantation is essentially indicated<sup>(8,16,20,42,43)</sup>. Subdural electrodes are implanted to cover the cortical surface of the brain (Fig. 5). They can be employed for electrical cortical stimulation extraoperatively or intraoperatively<sup>(20)</sup>. Multi-contact depth electrodes are stereotactically placed to record epileptiform activities arising from the deep cortex, for instance, the mesial temporal structures (the hippocampus, parahippocampus, amygdala) and insular cortex<sup>(16,20,26)</sup>. The pitfalls of intracranial recording include the limited amount of cortical surface covered by the electrodes, inappropriate spatial sampling because of the electrodes not covering the adequate areas and bilateral or diffuse spreads of interictal epileptiform discharges despite the ictal onset zone being focal<sup>(27,44,45)</sup>. Other critical morbidities are a risk of infection and intracranial hemorrhage which both correlate increasingly with the greater size and number of the craniotomies and electrodes, respectively<sup>(46,47)</sup>. In addition, postsurgical memory impairment may occur following implantation of depth electrodes into the bilateral hippocampi<sup>(48)</sup>.

Among the patients who have epileptogenic focus proximate to, or in overlay with the eloquent area, functional mapping of the associated eloquent cortex by using invasive electrodes with electrocortical stimulation is very helpful in surgical planning<sup>(49,50)</sup>. This strategy can delineate the limits of brain resection when the epileptogenic cortex is located in vicinity to the eloquent areas<sup>(16,51)</sup>.

#### 5. Magnetic resonance imaging (MRI)

High-resolution cranial MRI is the gold standard in detection of epileptogenic brain lesions with high sensitivity and specificity<sup>(20,52)</sup>. It is useful in identification of common epilepsy-related structural



**Fig. 6** Cranial MRI in detection of the epileptogenic lesion. (A) FLAIR image shows hypersignal intensity on the right hippocampus (arrow) consistent with hippocampal sclerosis. (B) A multilobulated lesion (“popcorn ball” or “raspberry” appearance) with bright signal intensity surrounded by black hemosiderin ring (arrow), in FLAIR image, is situated in the left inferior frontal gyrus. It is compatible with cerebral cavernous malformation.

cerebral lesions (Fig. 6) and it renders crucial information for surgical planning<sup>(16,28,53)</sup>. The standard MRI protocol for epilepsy includes T1-weighted imaging, T2-weighted imaging, fluid attenuation inversion recovery (FLAIR) imaging, as well as three dimensional volumetric acquisition sequences<sup>(29,52)</sup>. The latter provide quantitative assessment of the hippocampal volume.

Functional MRI is considered to be a commonly used non-invasive presurgical study alternative to a more invasive investigation, the Wada test, in terms of lateralization of language and memory function<sup>(18,22,26,52,54-58)</sup>. It is also beneficial for localizing the motor and sensory cortices<sup>(12,22,59-62)</sup>. Other special MRI techniques, such as EEG-functional MRI, T2 relaxometry, MRS, diffusion-weighted imaging, MR tractography with diffusion tensor imaging, quantitative analysis, and reconstruction technique, can be employed in presurgical evaluation of epilepsy surgery<sup>(22,52,63)</sup>.

### 6. Single photon emission computerized tomography (SPECT)

SPECT carries an important role in patients still harboring inconclusive results from the preliminary studies<sup>(22)</sup>. The functional deficit zone is displayed as an area of decreased cerebral perfusion by interictal SPECT. However, the interictal study has limited value in lateralization and localization of the seizure-generating focus<sup>(29)</sup>. Ictal SPECT is more reliable than the interictal study in localization-related epilepsy and demonstrated a region of increased cerebral blood flow<sup>(18,28,64-67)</sup>. Subtraction ictal SPECT coregistered with MRI (SISCOM) demonstrates a correlation

between a particular area of increasing cerebral perfusion on ictal SPECT and anatomical structures on high-resolution MRI. SISCOM is superior to direct visualization of ictal and interictal SPECT, useful in delineation of the seizure originating focus, particularly in epilepsy patients with normal MRI or extratemporal origin, and can be utilized for determining a target on which intracranial electrode will be implanted<sup>(68-70)</sup>.

### 7. Positron emission tomography (PET)

FDG-PET is a functional study of cerebral glucose metabolism to determine the functional deficit zone of the brain. The dysfunctional area is demonstrated as a hypometabolic area<sup>(12,18)</sup>. Hypometabolism on PET indicates significant neuronal loss in the aberrant area where it may be associated with the epileptogenicity<sup>(12)</sup>. However, the hypometabolic change can be encountered in the area without structural lesions on MRI and/or histopathological findings in sectioned brain tissue<sup>(71)</sup>. The abnormal findings on PET study are valuable in lateralizing and localizing of the epileptogenic focus, especially in non-lesional TLE and guide in placement of intracranial electrodes<sup>(20,22,29)</sup>.

### 8. Neuropsychological test

Neuropsychological evaluation intends to identify individuals at risk for memory dysfunction that may occur following epilepsy surgery<sup>(29,72)</sup>. The basic examination includes assessment of verbal and non-verbal memory and intelligence<sup>(20)</sup>. In addition, the test, by revealing impaired specific domains, can assist in lateralization and localization of the functional deficit area, which probably refers to the seizure generating focus<sup>(18,29)</sup>.

### 9. The wada test

The intracarotid amytal test or Wada test primarily aims to lateralize the dominant cerebral hemisphere corresponding for language function and to assess integrity of memory function on the individual side<sup>(20,26,72,73)</sup>. It also provides information in lateralization and localization of functional deficit area, especially in association with hippocampal sclerosis<sup>(72,73)</sup>. The disadvantages include complication risk in invasive cerebral angiographic procedure, unreliability, and invalidity of the test<sup>(74)</sup>. Despite the fact that the test seems to be invasive, it is considered to be the gold standard for preoperative lateralization of language dominant hemisphere and evaluation of memory function and is still beneficial in selected individuals.

## Conclusion

Epilepsy surgery is an optimal alternative for individuals agonizing from drug resistant epileptic disorders. In the majority of surgical cases, resective procedure can accomplish the favorable outcome. Among the epilepsy patients who are not appropriate for resective operation, functional surgery would be a valuable option. Careful selection of surgical candidate, good presurgical evaluation, and multidisciplinary management are the substantial prerequisites for achieving seizure control and ameliorating quality of life of the epileptic patients.

## Potential conflicts of interest

None.

## References

1. Wiebe S. Early epilepsy surgery. *Curr Neurol Neurosci Rep* 2004; 4: 315-20.
2. Gilliam F. The impact of epilepsy on subjective health status. *Curr Neurol Neurosci Rep* 2003; 3: 357-62.
3. Kwan P, Brodie MJ. Early identification of refractory epilepsy. *N Engl J Med* 2000; 342: 314-9.
4. Wiebe S, Blume WT, Girvin JP, Eliasziw M. A randomized, controlled trial of surgery for temporal-lobe epilepsy. *N Engl J Med* 2001; 345: 311-8.
5. Engel J Jr. Finally, a randomized, controlled trial of epilepsy surgery. *N Engl J Med* 2001; 345: 365-7.
6. Sperling MR, O'Connor MJ, Saykin AJ, Plummer C. Temporal lobectomy for refractory epilepsy. *JAMA* 1996; 276: 470-5.
7. Radhakrishnan K, So EL, Silbert PL, Jack CR Jr, Cascino GD, Sharbrough FW, et al. Predictors of outcome of anterior temporal lobectomy for intractable epilepsy: a multivariate study. *Neurology* 1998; 51: 465-71.
8. Rosenow F, Lüders H. Presurgical evaluation of epilepsy. *Brain* 2001; 124: 1683-700.
9. Elwes RD. Surgery for temporal lobe epilepsy. *BMJ* 2002; 324: 496-7.
10. Engel J Jr, Wiebe S, French J, Sperling M, Williamson P, Spencer D, et al. Practice parameter: temporal lobe and localized neocortical resections for epilepsy: report of the Quality Standards Subcommittee of the American Academy of Neurology, in association with the American Epilepsy Society and the American Association of Neurological Surgeons. *Neurology* 2003; 60: 538-47.
11. Devaux BC. Neurosurgical management of epilepsy in adults. In: Sindou M, editor. *Practical handbook of neurosurgery*. New York: Springer-Verlag; 2009: 420-39.
12. Akanuma N, Koutroumanidis M, Adachi N, Alarcon G, Binnie CD. Presurgical assessment of memory-related brain structures: the Wada test and functional neuroimaging. *Seizure* 2003; 12: 346-58.
13. Awad IA, Rosenfeld J, Ahl J, Hahn JF, Lüders H. Intractable epilepsy and structural lesions of the brain: mapping, resection strategies, and seizure outcome. *Epilepsia* 1991; 32: 179-86.
14. Lüders HO, Najm I, Nair D, Widdess-Walsh P, Bingman W. The epileptogenic zone: general principles. *Epileptic Disord* 2006; 8 (Suppl 2): S1-9.
15. Sarco DP, Burke JF, Madsen JR. Electroencephalography in epilepsy surgery planning. *Childs Nerv Syst* 2006; 22: 760-5.
16. Vellutini E, Garzon E, Inuzuka KM, Brock RS, Dal 'Col Lucio JE. Epilepsy surgery. In: Ramina R, Aguiar PH, Tatagiba M, editors. *Samii's essentials in neurosurgery*. Berlin Heidelberg: Springer-Verlag; 2008: 315-27.
17. Lüders HO, Carreño M. General principles of presurgical evaluation. In: Lüders HO, editor. *Textbook of epilepsy surgery*. London: Informa Healthcare; 2008: 409-22.
18. Unnwongse K, Wehner T, Foldvary-Schaefer N. Selecting patients for epilepsy surgery. *Curr Neurol Neurosci Rep* 2010; 10: 299-307.
19. Wieser HG. Epilepsy surgery: past, present and future. *Seizure* 1998; 7: 173-84.
20. Chandler C, Polkey C. Epilepsy surgery. In: Moore AJ, Newell DW, editors. *Neurosurgery: principles and practice*. London: Springer-Verlag; 2005: 591-606.
21. Davis KG, Ahn E. Epilepsy: surgery perspective. In: Chin LS, Regine WF, editors. *Principles and practice of stereotactic radiosurgery*. New York: Springer-Verlag; 2008: 583-91.
22. Duncan JS. Selecting patients for epilepsy surgery: synthesis of data. *Epilepsy Behav* 2011; 20: 230-2.
23. Schuele SU, Lüders HO. Intractable epilepsy: management and therapeutic alternatives. *Lancet Neurol* 2008; 7: 514-24.
24. Dworetzky BA, Reinsberger C. The role of the interictal EEG in selecting candidates for resective



- epilepsy surgery. *Epilepsy Behav* 2011; 20: 167-71.
25. McKhann GM. Novel surgical therapies for epilepsy. *Clin Neurosurg* 2006; 53: 179-84.
  26. Noachtar S, Borggraefe I. Epilepsy surgery: a critical review. *Epilepsy Behav* 2009; 15: 66-72.
  27. Carreño M, Lüders HO. General principles of presurgical evaluation. In: Lüders HO, Comair YG, editors. *Epilepsy surgery*. 2<sup>nd</sup> ed. Philadelphia: Lippincott, Williams & Wilkins; 2001: 185-200.
  28. Cascino GD. Surgical treatment for epilepsy. *Epilepsy Res* 2004; 60: 179-86.
  29. Kilpatrick C, O'Brien T, Matkovic Z, Cook M, Kaye A. Preoperative evaluation for temporal lobe surgery. *J Clin Neurosci* 2003; 10: 535-9.
  30. Gorji A, Straub H, Speckmann EJ. Epilepsy surgery: perioperative investigations of intractable epilepsy. *Anat Embryol (Berl)* 2005; 210: 525-37.
  31. Sperling MR, O'Connor MJ, Saykin AJ, Phillips CA, Morrell MJ, Bridgman PA, et al. A noninvasive protocol for anterior temporal lobectomy. *Neurology* 1992; 42: 416-22.
  32. Jan MM, Girvin JP. Seizure semiology: value in identifying seizure origin. *Can J Neurol Sci* 2008; 35: 22-30.
  33. Tiamkao S, Pratipanawatr T, Jitpimolmard S. Abdominal epilepsy: an uncommon of non-convulsive status epilepticus. *J Med Assoc Thai* 2011; 94: 998-1001.
  34. Shibasaki H, Ikeda A, Nagamine T. Use of magnetoencephalography in the presurgical evaluation of epilepsy patients. *Clin Neurophysiol* 2007; 118: 1438-48.
  35. Knowlton RC, Shih J. Magnetoencephalography in epilepsy. *Epilepsia* 2004; 45 (Suppl 4): 61-71.
  36. Rezaei AR, Hund M, Kronberg E, Zonenshayn M, Cappell J, Ribary U, et al. The interactive use of magnetoencephalography in stereotactic image-guided neurosurgery. *Neurosurgery* 1996; 39: 92-102.
  37. Orrison WW Jr. Magnetic source imaging in stereotactic and functional neurosurgery. *Stereotact Funct Neurosurg* 1999; 72: 89-94.
  38. Baumgartner C, Patariaia E, Lindinger G, Deecke L. Magnetoencephalography in focal epilepsy. *Epilepsia* 2000; 41 (Suppl 3): S39-47.
  39. Stefan H, Hummel C, Hopfengartner R, Pauli E, Tilz C, Ganslandt O, et al. Magnetoencephalography in extratemporal epilepsy. *J Clin Neurophysiol* 2000; 17: 190-200.
  40. Lopes da Silva F. Functional localization of brain sources using EEG and/or MEG data: volume conductor and source models. *Magn Reson Imaging* 2004; 22: 1533-8.
  41. Adjajian P, Barnes GR, Hillebrand A, Holliday IE, Singh KD, Furlong PL, et al. Co-registration of magnetoencephalography with magnetic resonance imaging using bite-bar-based fiducials and surface-matching. *Clin Neurophysiol* 2004; 115: 691-8.
  42. Lüders H, Awad I, Burgess R, Wyllie E, Van Ness P. Subdural electrodes in the presurgical evaluation for surgery of epilepsy. *Epilepsy Res Suppl* 1992; 5: 147-56.
  43. Srikiyvilakul T, Locharernkul C, Deesudchit T, Tuchinda L, Lerdlum S, Tepmongkol S, et al. The first invasive EEG monitoring for surgical treatment of epilepsy in Thailand. *J Med Assoc Thai* 2006; 89: 527-32.
  44. Jayakar P, Duchowny M, Resnick TJ, Alvarez LA. Localization of seizure foci: pitfalls and caveats. *J Clin Neurophysiol* 1991; 8: 414-31.
  45. Hirsch LJ, Spencer SS, Williamson PD, Spencer DD, Mattson RH. Comparison of bitemporal and unitemporal epilepsy defined by depth electroencephalography. *Ann Neurol* 1991; 30: 340-6.
  46. Pilcher WH. Epilepsy surgery: outcome and complications. In: Winn HR, editor. *Youmans neurological surgery*. 5<sup>th</sup> ed. Philadelphia: Saunders; 2003: 2565-85.
  47. Van Gompel JJ, Worrell GA, Bell ML, Patrick TA, Cascino GD, Raffel C, et al. Intracranial electroencephalography with subdural grid electrodes: techniques, complications, and outcomes. *Neurosurgery* 2008; 63: 498-505.
  48. Pilcher WH, Ojemann GA. Presurgical evaluation and epilepsy surgery. In: Apuzzo MLJ, editor. *Brain surgery: complications, avoidance and management*. New York: Churchill Livingstone; 1993: 1525-55.
  49. Wyllie E, Lüders H, Morris HH 3rd, Lesser RP, Dinner DS, Rothner AD, et al. Subdural electrodes in the evaluation for epilepsy surgery in children and adults. *Neuropediatrics* 1988; 19: 80-6.
  50. Comair YG, Van Ness PC, Chamoun RB, Bouclaus CH. Neocortical resections. In: Engel J Jr, Pedley TA, editors. *Epilepsy: a comprehensive textbook*. 2<sup>nd</sup> ed. Philadelphia: Lippincott, Williams & Wilkins; 2008: 1869-78.
  51. Lüders H, Lesser RP, Dinner DS, Morris HH, Wyllie E, Godoy J. Localization of cortical function: new information from extraoperative

- monitoring of patients with epilepsy. *Epilepsia* 1988; 29 (Suppl 2): S56-65.
52. Jackson GD, Badawy RA. Selecting patients for epilepsy surgery: identifying a structural lesion. *Epilepsy Behav* 2011; 20: 182-9.
  53. Von Oertzen J, Urbach H, Jungbluth S, Kurthen M, Reuber M, Fernandez G, et al. Standard magnetic resonance imaging is inadequate for patients with refractory focal epilepsy. *J Neurol Neurosurg Psychiatry* 2002; 73: 643-7.
  54. Szaflarski JP, Holland SK, Jacola LM, Lindsell C, Privitera MD, Szaflarski M. Comprehensive presurgical functional MRI language evaluation in adult patients with epilepsy. *Epilepsy Behav* 2008; 12: 74-83.
  55. Desmond JE, Sum JM, Wagner AD, Demb JB, Shear PK, Glover GH, et al. Functional MRI measurement of language lateralization in Wada-tested patients. *Brain* 1995; 118 (Pt 6): 1411-9.
  56. Worthington C, Vincent DJ, Bryant AE, Roberts DR, Vera CL, Ross DA, et al. Comparison of functional magnetic resonance imaging for language localization and intracarotid speech amytal testing in presurgical evaluation for intractable epilepsy. Preliminary results. *Stereotact Funct Neurosurg* 1997; 69: 197-201.
  57. Hertz-Pannier L, Gaillard WD, Mott SH, Cuenod CA, Bookheimer SY, Weinstein S, et al. Noninvasive assessment of language dominance in children and adolescents with functional MRI: a preliminary study. *Neurology* 1997; 48: 1003-12.
  58. Benson RR, FitzGerald DB, LeSueur LL, Kennedy DN, Kwong KK, Buchbinder BR, et al. Language dominance determined by whole brain functional MRI in patients with brain lesions. *Neurology* 1999; 52: 798-809.
  59. Stippich C, Freitag P, Kassubek J, Soros P, Kamada K, Kober H, et al. Motor, somatosensory and auditory cortex localization by fMRI and MEG. *Neuroreport* 1998; 9: 1953-7.
  60. Zang Y, Jia F, Weng X, Li E, Cui S, Wang Y, et al. Functional organization of the primary motor cortex characterized by event-related fMRI during movement preparation and execution. *Neurosci Lett* 2003; 337: 69-72.
  61. Newton JM, Sunderland A, Gowland PA. fMRI signal decreases in ipsilateral primary motor cortex during unilateral hand movements are related to duration and side of movement. *Neuroimage* 2005; 24: 1080-7.
  62. Araujo D, de Araujo DB, Pontes-Neto OM, Escorsi-Rosset S, Simao GN, Wichert-Ana L, et al. Language and motor fMRI activation in polymicrogyric cortex. *Epilepsia* 2006; 47: 589-92.
  63. Connelly A. MR diffusion and perfusion in epilepsy. In: Kuzniecky RI, Jackson GD, editors. *Magnetic resonance in epilepsy: neuroimaging techniques*. 2<sup>nd</sup> ed. London: Elsevier; 2005: 315-32.
  64. Marks DA, Katz A, Hoffer P, Spencer SS. Localization of extratemporal epileptic foci during ictal single photon emission computed tomography. *Ann Neurol* 1992; 31: 250-5.
  65. Ho SS, Berkovic SF, Berlangieri SU, Newton MR, Egan GF, Tochon-Danguy HJ, et al. Comparison of ictal SPECT and interictal PET in the presurgical evaluation of temporal lobe epilepsy. *Ann Neurol* 1995; 37: 738-45.
  66. Duncan JS. Imaging and epilepsy. *Brain* 1997; 120 (Pt 2): 339-77.
  67. Duncan R. SPECT in focal epilepsies. *Behav Neurol* 2000; 12: 69-75.
  68. O'Brien TJ, So EL, Mullan BP, Hauser MF, Brinkmann BH, Bohnen NI, et al. Subtraction ictal SPECT co-registered to MRI improves clinical usefulness of SPECT in localizing the surgical seizure focus. *Neurology* 1998; 50: 445-54.
  69. O'Brien TJ, So EL, Mullan BP, Cascino GD, Hauser MF, Brinkmann BH, et al. Subtraction peri-ictal SPECT is predictive of extratemporal epilepsy surgery outcome. *Neurology* 2000; 55: 1668-77.
  70. So EL. Integration of EEG, MRI, and SPECT in localizing the seizure focus for epilepsy surgery. *Epilepsia* 2000; 41 (Suppl 3): S48-54.
  71. O'Brien TJ, Newton MR, Cook MJ, Berlangieri SU, Kilpatrick C, Morris K, et al. Hippocampal atrophy is not a major determinant of regional hypometabolism in temporal lobe epilepsy. *Epilepsia* 1997; 38: 74-80.
  72. Loring DW, Meador KJ. Pre-surgical evaluation for epilepsy surgery. *Saudi Med J* 2000; 21: 609-16.
  73. Davies KG, Bell BD, Dohan FC, Schweitzer JB, Hermann BP. Prediction of presence of hippocampal sclerosis from intracarotid amobarbital procedure memory asymmetry scores and epilepsy on set age. *Epilepsy Res* 1999; 33: 117-23.
  74. Simkins-Bullock J. Beyond speech lateralization: a review of the variability, reliability, and validity of the intracarotid amobarbital procedure and its nonlanguage uses in epilepsy surgery candidates. *Neuropsychol Rev* 2000; 10: 41-74.

---

## การผ่าตัดรักษาโรคลมชัก: หลักการสำคัญและการประเมินก่อนผ่าตัด

บรรพต สิทธินามสุวรรณ, ศรัณย์ นันทอารี

**ภูมิหลัง:** ผู้ป่วยโรคลมชักจำนวนหนึ่งได้รับความทุกข์ทรมานจากภาวะติดต่อยากันชัก การผ่าตัดรักษาโรคลมชักเป็นทางเลือกที่เหมาะสมในการรักษาผู้ป่วยที่มีภาวะดังกล่าว

**วัตถุประสงค์:** การผ่าตัดโรคลมชักมีวัตถุประสงค์เพื่อกำจัดอาการชักที่ทำให้เดือนร้อนโดยเก็บรักษาการทำงานที่สำคัญของระบบประสาทไว้และเพื่อทำให้คุณภาพชีวิตของผู้ป่วยในระยะยาวดีขึ้น

**วัสดุและวิธีการ:** คณะผู้นิพนธ์ทบทวนบทความและงานวิจัยทางการแพทย์ซึ่งเกี่ยวกับหลักการสำคัญของการผ่าตัดโรคลมชักและการประเมินก่อนผ่าตัด

**ผลการศึกษา:** หลักการสำคัญในการผ่าตัดโรคลมชักคือการตัดสมองส่วนที่เป็นจุดกำเนิดชักหรือตัดทางติดต่อระหว่างสมองส่วนที่เป็นจุดกำเนิดชักออกจากสมองส่วนอื่นซึ่งจะมีผลให้ผู้ป่วยหายจากอาการชักได้ การตรวจวินิจฉัยหลายชนิดช่วยในการกำหนดขอบเขตของสมองส่วนที่เป็นจุดกำเนิดชักรวมทั้งช่วยพยากรณ์ว่าผู้ป่วยรายใดเสี่ยงต่อการเกิดความคิดปกติของระบบประสาทหลังผ่าตัด การผ่าตัดโรคลมชักแบ่งออกเป็นการตัดสมองส่วนที่เป็นจุดกำเนิดชักและการผ่าตัดเพื่อเปลี่ยนการทำงานของระบบประสาท การตัดสมองส่วนที่เป็นจุดกำเนิดชักมีวัตถุประสงค์เพื่อให้หายจากอาการชักในขณะที่การผ่าตัดเพื่อเปลี่ยนการทำงานของระบบประสาทมมีวัตถุประสงค์เพื่อลดความถี่และบรรเทาความรุนแรงของอาการชัก การประเมินก่อนผ่าตัดควรกระทำโดยกลุ่มสหสาขาวิชาชีพที่เชี่ยวชาญเรื่องโรคลมชัก

**สรุป:** ในบทความกล่าวถึงการตรวจวินิจฉัยและการสืบค้นเพิ่มเติมที่เกี่ยวข้องกับการผ่าตัดโรคลมชัก รวมทั้งกล่าวถึงขั้นตอนที่สำคัญในการประเมินก่อนผ่าตัดและแนวทางการดูแลรักษาผู้ป่วยโรคลมชักที่ติดต่อยากันชัก

---