

Case Report

Isolated Ocular Relapse in Childhood Acute Lymphoblastic Leukemia during Second Interim Maintenance Phase of Chemotherapy: Case Report

Chalinee Monsereenusorn MD*, Piya Rujkijyanont MD*,
Worapot Srimanan MD**, Chanchai Traivaree MD, MSc*

* Division of Pediatric Hematology/Oncology, Department of Pediatrics,
Phramongkutklao Hospital and College of Medicine, Bangkok, Thailand

** Division of Pediatric Ophthalmology and Strabismus/Neuro-Ophthalmology, Department of Ophthalmology,
Phramongkutklao Hospital and College of Medicine, Bangkok, Thailand

More than 80% of acute lymphoblastic leukemia (ALL) in pediatric population is curable by using combinations of chemotherapy. However, 20% of the cases still suffer from disease relapse. The most common site of relapse is bone marrow. Relapse of childhood ALL involving the eyeball is rare. However, it occurs in 2.2% of relapsing children. The authors described a 10-year-old Thai boy with underlying ALL on therapy, presented with a one-month history of progressive visual loss of his right eye. The clinical and imaging studies strongly suggested the diagnosis of isolated ocular relapse. In this report, the authors presented the findings from successfully specific treatment consisting of systemic chemotherapy and radiation therapy on the affected eye. From other studies, the outcome was more favorable in cases of ocular relapse off therapy. In our study, one case of isolated ocular relapse ALL was reported.

Keywords: Acute lymphoblastic leukemia, Isolated ocular relapse, Children

J Med Assoc Thai 2015; 98 (11): 1150-3

Full text. e-Journal: <http://www.jmatonline.com>

More than 80% of acute lymphoblastic leukemia (ALL) in pediatric population is curable by using combinations of chemotherapy. However, 20 to 30% of the cases still suffer from disease relapse. The most common site of relapse is bone marrow, although relapses at extramedullary sites such as the central nervous system (CNS) and testes also occur. Intraocular relapse of ALL is rare, and it can be found either alone or in combination with relapse at other sites⁽¹⁾. The authors reported a case of isolated ocular relapsed ALL in our institute.

Case Report

A 10-year-old Thai boy with underlying ALL on therapy, presented with a one-month history of progressive visual loss of his right eye. He was known for high-risk ALL and had been treated with Thai Pediatrics Oncology Group (TPOG) protocol for high-risk ALL. His initial presentation included bone pain, the initial complete blood count (CBC) revealed

hematocrit of 25 volume %, hemoglobin of 8.5 g/dl, white blood cell (WBC) count of 58,800 cell/mm³ (PMN 7%, Lymphocyte 80%, Monocyte 13%), and platelets count of 141,000 cell/mm³. He archived complete remission post induction chemotherapy and had remained in remission for 10 months, until the ninth week of second interim maintenance when he came for a scheduled chemotherapy visit and reported losing visual perception of the right eye over a month. On physical examination, his visual acuity showed only light perception of the right eye. Anterior segment examination was unremarkable. Fundoscopic examination showed subretinal whitish infiltrative lesion with intraretinal and subretinal hemorrhage (Fig. 1). No lymphadenopathy or hepatosplenomegaly were found and neurological examination was within normal limit. Laboratory tests including CBC were sent and were unremarkable with no suspicious blast cells. Bone marrow examination was morphologically normal with negative minimal residual disease by flow cytometry. Bone marrow cytogenetic revealed 46 XY with normal male karyotype. Cerebrospinal fluid was negative for malignant cells. Liver, renal function tests, and tumor lysis laboratory profiles were within normal range.

Correspondence to:

Traivaree C, Division of Hematology/Oncology, Department of Pediatrics, Phramongkutklao Hospital and College of Medicine, Bangkok 10400, Thailand.

Phone & Fax: +66-2-6444130

E-mail: ctrivaree@yahoo.com

Magnetic resonance imaging (MRI) of the brain showed orbits with gadolinium (GAD) in coronal section, abnormal hypo/hyper signal, ill-defined mass 1.2x1 cm in diameter at right posterior orbit, no optic nerve, or other brain parenchymal (Fig. 2).

After the diagnosis of isolated ocular relapse was confirmed, the patient was then treated with local photon beam radiation at the dose of 30 Gy divided into 15 fractions, and subsequently started on systemic chemotherapy for relapse acute lymphoblastic leukemia as per Total Therapy XIII B for high-risk ALL from St. Jude Children's Research Hospital⁽²⁾. The remission induction phase included:

- Prednisolone 40 mg/m²/day orally for 28 days
- Vincristine 1.5 gm/m² (max 2 mg) intravenous weekly at day 1, 8, 15, and 22
- Doxorubicin 25 mg/m² intravenous every other weeks at day 1 and 15
- L-asparaginase 10,000 unit/m² intramuscular at day 2, 4, and 6
- Cytarabine 300 mg/m² intravenous at day 22, 25, and 29
- Etoposide 300 mg/m² intravenous at day 22, 25, and 29
- Triple intrathecal MHA (Methotrexate 15 mg, Hydrocortisone 15 mg, and Cytarabine 30 mg) weekly at day 1, 8, 15, and 22

Consolidation phase consisted of:

- High dose methotrexate 2 gm/m² intravenous drip in 24 hours, at day 43 and 50 plus leucovorin 15 mg/m² every six hours for 12 doses in each cycle of methotrexate
- Mercaptopurine 75 mg/m² orally at day 43 to 57
- Triple intrathecal MHA (Methotrexate 15 mg, Hydrocortisone 15 mg, and Cytarabine 30 mg) at day 43 and 50

Continuation phase for 53 weeks as a basis of high-risk drug pair in weekly rotation consisted of:

- Etoposide 300 mg/m² with cyclophosphamide 300 mg/m² intravenous
- Methotrexate 40 mg/m² intravenous with mercaptopurine 75 mg/m² orally
- Methotrexate 40 mg/m² intravenous with cytarabine 300 mg/m² intravenous
- Vincristine 1.5 mg/m² intravenous with dexamethasone 8 mg/m²/day orally
- Etoposide 300 mg/m² with cyclophosphamide 300 mg/m² intravenous
- Methotrexate 2 gm/m² intravenous drip in 24 hours with mercaptopurine 75 mg/m² orally
- Etoposide 300 mg/m² with cytarabine 300 mg/m² intravenous
- Vincristine 1.5 mg/m² intravenous with dexamethasone 8 mg/m²/day orally
- Triple intrathecal MHA (Methotrexate 15 mg, Hydrocortisone 15 mg and Cytarabine 30 mg) every four weeks
- Re-induction at week 16 to 21

At present, patient remained in second remission for three years after completed the therapy. He had been followed-up by pediatric oncologists and pediatric ophthalmologist as regular basis. The fundoscopic examination after completing remission

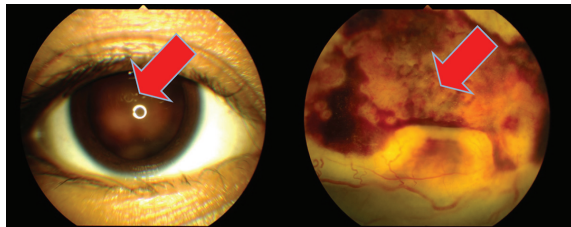


Fig. 1 Left: Subretinal infiltrative mass with shallow exudative retinal detachment of right eye was demonstrated through dilated pupil. Right; Subretinal whitish infiltrative lesion admixed with intraretinal and subretinal hemorrhage with exudative retinal detachment and optic nerve head involvement of the right eye, suspicious for leukemic infiltrative lesion.

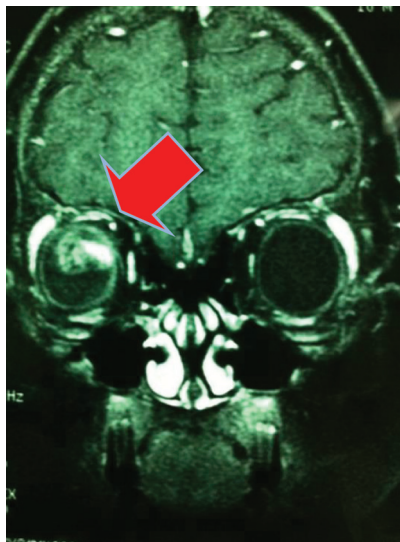


Fig. 2 MRI brain with orbit demonstrated ill-defined mass at right posterior globe size 1.2x 1 cm in diameter.

induction of chemotherapy revealed decreased infiltrative lesion but still having some degree of retinal detachment. However, his visual acuity of the right eye had been limited to hand movement. In addition, repeated MRI of the orbit after completing 6-week of remission induction chemotherapy revealed decreased in size of the infiltrative mass from size 1.2x1 cm to 0.5x0.5 cm in diameter at right posterior chamber and subsequently showed complete resolution of the mass on the most recent MRI.

Discussion

Relapse of childhood ALL involving the eyeball is rare, accounting for 2.2% of relapsing cases⁽¹⁾. Direct invasion of leukemic cells, in less frequent circumstance, may lead to direct ocular infiltration, which carries a poor prognosis and associates with CNS relapse⁽³⁾.

Ocular relapse can occur during the course of leukemia treatment or at the end of therapy^(4,5). Time period of ocular relapse represents a prognosis. If the relapse occurs within the first few months after the end of therapy, this is considered as high-risk feature with more inferior outcomes and worse prognosis⁽⁶⁾.

A recent study revealed that 96% of children with ALL died within 28 months of onset of ocular signs. Of those ALL patients with ocular manifestations, 82% had CNS leukemia⁽⁷⁾. Eyes may remain a sanctuary site for leukemic cells during therapy, as they are usually shielded during central nervous system irradiation and chemotherapy agents do not penetrate the eye wall⁽⁸⁾. It has been shown that intrathecal methotrexate does not reach the eyes, and its effect on tumor cells in the optic nerve is demonstrable only as far as the termination of the subdural space posterior to the orbit⁽⁹⁾.

The five-year survival rate of patients with ophthalmic manifestations was reported to be 21.4%. This survival rate (45.7%, $p < 0.05$) was significantly lower than those who lacked ophthalmic manifestations. All of the patients with ophthalmic manifestations had either bone marrow relapse or central nervous system leukemia. In most cases, the prognosis was related to risk factors such as central nervous system leukemia or bone marrow relapse⁽⁷⁾.

A multicenter study reported by Lo et al suggested that those leukemic patients with ocular involvement, in the first complete remission, might be cured with chemotherapy and high dose radiation therapy to the affected eye⁽¹⁰⁾. Isolated ocular relapse can be successfully treated, especially if it occurred

after the completion of therapy; second ocular infiltration was seen only in anterior chamber involvement after low doses of local radiation therapy. While the need for high doses of chemotherapy is not evident, high-dose ocular radiation therapy (>20 Gy) seems to be mandatory to cure this leukemic relapse. The outcome is more favorable in cases of ocular relapse off therapy rather than on therapy, as is observed in all relapses. Treatment of the reported cases consisted of systemic chemotherapy and, in most cases, radiation therapy on the affected eye. Long-term disease-free survival (DFS) after eye relapse was observed only in patients treated with chemotherapy and local radiation therapy (RT), and second eye relapse occurred only in few patients treated with low doses of RT⁽¹¹⁾. Awareness of the high-risk period of ocular relapse ALL should lead to early detection, diagnosis, and treatment. It should give these children benefit of early treatment in this traditionally poor prognostic category⁽⁵⁾.

Although disease-free survival was favorable, the vision of the affected eye might be compromised depending on location and extension of retinal involvement. For our case, the patient remains in second remission for three years after completing the therapy. However, his visual acuity of the right eye had been limited to only hand movement due to permanent damage from retinal detachment.

Conclusion

The authors reported the case of a 10-year-old boy with underlying ALL on therapy, presented with a one-month history of progressive visual loss of his right eye. The authors considered that specific treatment consisted of systemic chemotherapy and radiation therapy on the affected eye should be the best management in this situation. However, larger studies with long-term follow-up will be required to evaluate the connection between these two aspects.

What is already known on this topic?

Intraocular relapse of ALL is rare, and it can be found either alone or in combination with relapse at other sites. There are limitation of management and follow-up of these patients.

What this study adds?

The present study showed that specific treatment consisted of systemic chemotherapy with adapted protocol plus local radiation therapy on the affected eye is the best management in this situation.

The outcome was more favorable in cases of ocular relapse after completion of the therapy.

Potential conflicts of interest

None.

References

1. Somerville TC, Hann IM, Harrison G, Eden TO, Gibson BE, Hill FG, et al. Intraocular relapse of childhood acute lymphoblastic leukaemia. *Br J Haematol* 2003; 121: 280-8.
2. Pui CH, Sandlund JT, Pei D, Campana D, Rivera GK, Ribeiro RC, et al. Improved outcome for children with acute lymphoblastic leukemia: results of Total Therapy Study XIII B at St Jude Children's Research Hospital. *Blood* 2004; 104: 2690-6.
3. Rosenthal AR. Ocular manifestations of leukemia. A review. *Ophthalmology* 1983; 90: 899-905.
4. Bunin N, Rivera G, Goode F, Hustu HO. Ocular relapse in the anterior chamber in childhood acute lymphoblastic leukemia. *J Clin Oncol* 1987; 5: 299-303.
5. MacLean H, Clarke MP, Strong NP, Kernahan J, Ashraf S. Primary ocular relapse in acute lymphoblastic leukemia. *Eye (Lond)* 1996; 10 (Pt 6): 719-22.
6. Novakovic P, Kellie SJ, Taylor D. Childhood leukaemia: relapse in the anterior segment of the eye. *Br J Ophthalmol* 1989; 73: 354-9.
7. Ohkoshi K, Tsiaras WG. Prognostic importance of ophthalmic manifestations in childhood leukaemia. *Br J Ophthalmol* 1992; 76: 651-5.
8. Ninane J, Taylor D, Day S. The eye as a sanctuary in acute lymphoblastic leukaemia. *Lancet* 1980; 1: 452-3.
9. Ellis W, Little HL. Leukemic infiltration of the optic nerve head. *Am J Ophthalmol* 1973; 75: 867-71.
10. Lo CM, D'Angelo P, Lumia F, Provenzano G, Zingone A, Bachelot C, et al. Leukemic ophthalmopathy: a report of 21 pediatric cases. *Med Pediatr Oncol* 1994; 23: 8-13.
11. Curto ML, D'Angelo P, Jankovic M, Fugardi MG, Ziino O, Casale F. Isolated ocular relapse in childhood acute lymphoblastic leukemia during continuing complete remission. *Haematologica* 1996; 81: 47-50.

การกลับมาเป็นซ้ำของโรคมะเร็งเม็ดเลือดขาวในเด็ก เฉพาะที่ตา ระหว่างการให้ยาเคมีบำบัดในช่วง *interim maintenance*: รายงานผู้ป่วย

ชาลินี มนต์เสรีสุธรรม, ปิยะ รุจกิจยานนท์, วรพจน์ ศรีมานันท์, ชาลุชัย ไตรวารีย์

ในปัจจุบันมากกว่า 80% ของมะเร็งเม็ดเลือดขาวในเด็กสามารถรักษาให้หายขาดโดยกลุ่มยาเคมีบำบัดหลายตัว อย่างไรก็ตาม 20% ของผู้ป่วยเหล่านี้ยังมีการกลับมาของโรคซ้ำได้ โดยตำแหน่งที่กลับมาเป็นซ้ำบ่อยที่สุดคือไขกระดูก ทั้งนี้ตำแหน่งที่กลับมาเป็นซ้ำเฉพาะที่ในตานั้นพบได้น้อยมาก หรือ พบเพียง 2.2% เท่านั้น ผู้นิพนธ์ได้รายงานผู้ป่วยเด็กชายไทยอายุ 10 ปี ที่มีพื้นฐานเป็นโรคมะเร็งเม็ดเลือดขาวที่กำลังรักษาด้วยยาเคมีบำบัดในช่วง *interim maintenance* และผู้ป่วยมาพบแพทย์ด้วยอาการตามัว ประมาณ 1 เดือน โดยอาการทางคลินิก และผลรังสีวินิจฉัยยืนยันการวินิจฉัยว่ามีการกลับมาของโรคจริง โดยรายงานนี้ผู้นิพนธ์ได้กล่าวถึงการให้ยาเคมีบำบัดร่วมกับการฉายแสงบริเวณดวงตาของผู้ป่วย โดยผลของการรักษาเป็นที่น่าพอใจและไม่มีภาวะแทรกซ้อน