

Normogram of Fetal Middle Cerebral Artery Peak Systolic Velocity at 20-37 Weeks of Gestation at Srinagarind Hospital

Piyamas Saksiriwuttho MD*, Chatuporn Duangkum MD*,
Thawalwong Ratanasiri MD*, Ratana Komwilaisak MD*

* Division of Maternal-Fetal Medicine, Department of Obstetrics and Gynaecology, Faculty of Medicine,
Khon Kaen University, Khon Kaen, Thailand

Objective: To establish normal references of fetal middle cerebral artery peak systolic velocity (MCA PSV) at 20 to 37 weeks of gestation at Srinagarind Hospital.

Material and Method: A descriptive cross-sectional study was performed. Normal fetuses at 20 to 37 weeks of gestation were studied by gray scale ultrasonography initially and then Doppler of MCA PSV.

Results: At least 18 pregnant women of each gestational age with an uncomplicated singleton were enrolled. The MCA PSV was increased as gestational age advanced from 24.34 cm/sec (SD 3.91) at 20 weeks to 59.04 cm/sec (SD 10.80) at 37 weeks.

Conclusion: A normogram of fetal MCA PSV at 20 to 37 weeks of gestation at Srinagarind hospital was generated.

Keywords: Peak systolic velocity, Middle cerebral artery, Fetal anemia, Doppler ultrasound

J Med Assoc Thai 2012; 95 (9): 1122-5

Full text. e-Journal: <http://jmat.mat.or.th>

Fetal anemia is defined as hemoglobin less than 18 gram/deciliter⁽¹⁾. Fetal anemia can be caused by Hb Bart's hydrops fetalis, red blood cell alloimmunization, parvovirus B19 infection, fetomaternal hemorrhage, intrauterine growth restriction, and twin to twin transfusion syndrome⁽²⁾.

The invasive procedure for prediction and diagnosis of fetal anemia are amniocentesis and cordocentesis⁽³⁻⁵⁾. In 1961, Liley^(3,4) described the use of amniotic fluid bilirubin level assessment to predict the severity of hemolytic disease but this procedure did not directly diagnosed fetal anemia. Cordocentesis for fetal hemoglobin is the most accurate procedure for diagnosis fetal anemia but risk of these procedures are rupture of membrane, preterm delivery, infection, hemorrhage, fetal death and increased the antibody levels by causing fetomaternal hemorrhage. Fetal loss rate are 1-3% per procedure^(3,4). Feto-maternal hemorrhage can occurred 2.3-17% of procedure⁽⁴⁾. Moreover, in case of intrauterine blood transfusion is performed, serially cordocentesis to follow-up fetal hemoglobin concentration is needed. Therefore, more

chance of complications can be occurred. According to these disadvantages of the procedure, many investigators develop an option, noninvasive test, to predict fetal anemia. Doppler measurement of the fetal middle cerebral artery peak systolic velocity (MCA PSV) has then been shown to correlate with the gestational age, as well as with fetal hemoglobin⁽⁶⁻⁸⁾.

In 1995, Mari et al⁽⁶⁻⁸⁾ observed that Doppler ultrasound measurements of fetal MCA PSV could be used to predict fetal moderate to severe anemia. It was believed that decreased red cell mass, which associated decreased blood viscosity and increased cardiac output, resulted in an increased MCA PSV of fetal arterial blood flow. Because of a noninvasive and safe procedure for the fetuses, this procedure is more practical and valuable in those cases that need follow-up after intrauterine blood transfusion. Current reference range, however, has been derived from foreign countries. Different race, region, and weight of fetuses may affect fetal MCA PSV. The aim of the present study was to establish normal references of fetal MCA PSV for North-eastern pregnant women at 20 to 37 weeks of gestation at Srinagarind Hospital.

Correspondence to:

Saksiriwuttho P, Department of Obstetrics and Gynaecology, Faculty of Medicine, Khon Kaen University, Khon Kaen 40002, Thailand.

Phone: 043-363-030

E-mail: Piyamassaksiriwuttho@yahoo.com

Material and Method

The present study was performed as a prospective descriptive cross-sectional study between

June 1, 2011 and November 30, 2011. Doppler ultrasound measurements from 20 to 37 weeks of gestation of at least 18 pregnant women for each gestational age calculated by the formula $N = Z_{\alpha}^2 (SD)^2 / d^2$ ($d = 5$) with the total of low risk singleton pregnancies were recruited into the antenatal care clinic at Srinagarind Hospital, Khon Kaen University. The research protocol was approved by Khon Kaen University Ethics Committee, No. HE 541061. All participants were given the information sheets and individual informed consent was obtained. Certain gestational age between 20 and 37 weeks was calculated from the first day of the last normal menstrual period without hormonal contraception. In case of taking hormonal contraception, gestational age was confirmed by ultrasonographic measurement in the first twelve weeks of gestation. Fetal anomaly, abnormal fetal karyotype, or maternal conditions that might affect fetal anemia or fetal IUGR were excluded from the present study.

Prior to perform Doppler ultrasound assessment, all pregnant women were performed ultrasonography to evaluate fetal biometry including biparietal diameter (BPD), head circumference (HC), abdominal circumference (AC), and femur length (FL).

Estimated fetal weight was calculated according to KKU formulas. Amniotic fluid volume and placental grading were evaluated. Doppler ultrasound measurement was performed by one ultrasonographer using 5 MHz transducers (GE Voluson E8).

Doppler images were recorded when fetal body or fetal respiratory did not move. The vascular circle of Willis was identified by color Doppler in an axial view of the fetal cranium. The MCA was identified at its bifurcation from the internal carotid artery and the PSV was measured close to its origin in the internal carotid artery with an angle of insonation as close to 0 degrees as possible. Doppler blood flow velocity waveforms were obtained across 6 to 8 cardiac cycles at least three measurements, and were measured by the investigator and averaged. Mean and 2SD of the fetal MCA PSV was calculated for gestational age 20 to 37 weeks, respectively. A normal value for each gestational age was then constructed using mean \pm 2SD.

Results

Three hundred fifty three of low risk pregnant women were enrolled for the present study. The mean age of the pregnant women was 26.7 years. The

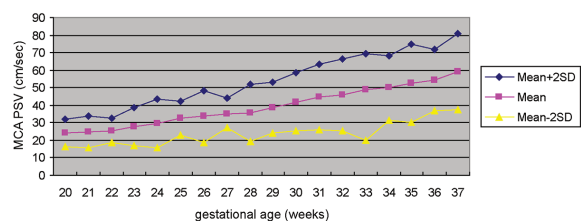


Fig. 1 Normogram (mean \pm 2SD) of fetal MCA PSV with gestation

MCA PSV = middle cerebral artery peak systolic velocity, X = mean of middle cerebral artery peak systolic velocity index, SD = standard deviation of middle cerebral artery peak systolic velocity index

MCA PSV was successfully measured in all subjects from 20 to 37 weeks of gestation. The MCA PSV was increased as gestational age advanced from 24.34 cm/sec (SD 3.91) at 20 weeks to 59.04 cm/sec (SD 10.80) at 37 weeks as shown in Fig. 1.

Table 1 demonstrates number of subjects for each gestation, mean, standard deviation, range and mean \pm 2SD for MCA PSV.

Discussion

MCA PSV of fetal arterial blood flow is a non-invasive and safe procedure to predict fetal anemia. In Thailand, Thongsong et al⁽⁹⁾ and Rujiwetpongstorn et al⁽¹⁰⁾ reported MCA PSV velocity of healthy fetuses in the first half of pregnancy of Thai people to predict fetal anemia especially in cases that may be Hb Bart's hydrops fetalis. However, normogram of fetal MCA PSV in the latter half of pregnancy has not been established.

The present study demonstrated that the MCA PSV was continuous increased during the second half of gestation, which was similar to that reported by Tarzamni et al⁽¹¹⁾ and Bahlmann et al⁽¹²⁾. Patterns were also the same but values in the present study were slightly higher. Explanations for these dissimilarities were the use of different statistical methods, curve analysis model, and different sample sizes.

The strengths of the present study were first, an adequate sample size. Second, all gestational age from 20 to 37 weeks were measured. Third, only one ultrasonologist performed MCA PSV to avoid inter-observer variation. Lastly, only one ultrasonographic machine and one transabdominal transducer were used to avoid equipment's variation.

The limitations of the present study were first, cross-sectional rather than longitudinal measurement. Second, all neonates were not proved to have normal

Table 1. Number of subjects, mean, standard deviation, ranges and mean \pm 2SD of the MCA PSV

Gestational age (weeks)	Number of subjects	Middle cerebral artery peak systolic velocity (MCA PSV)			
		Mean (cm/sec)	Standard deviation (SD)	Range	Mean \pm 2SD
20	22	24.34	3.91	18.81-31.82	24.34 \pm 7.82
21	20	24.52	4.52	19.34-36.94	24.52 \pm 9.04
22	19	25.56	3.45	19.06-34.55	25.56 \pm 6.90
23	18	27.97	5.40	17.90-41.62	27.97 \pm 10.80
24	21	29.46	6.96	18.66-46.86	29.46 \pm 13.92
25	18	32.62	4.81	26.97-48.26	32.60 \pm 9.62
26	19	33.77	7.38	22.30-51.30	33.77 \pm 14.76
27	18	35.30	4.16	27.54-45.30	35.30 \pm 8.32
28	20	35.74	8.06	25.59-43.54	35.74 \pm 16.12
29	19	38.71	7.16	27.80-52.61	38.71 \pm 14.32
30	22	41.93	8.30	25.13-57.32	41.93 \pm 16.60
31	18	44.58	9.33	30.57-55.24	44.58 \pm 18.66
32	20	45.97	10.30	36.74-55.82	45.97 \pm 20.60
33	19	49.17	10.04	35.76-71.30	49.17 \pm 20.08
34	19	49.92	9.11	30.84-66.76	49.92 \pm 18.22
35	20	52.50	11.29	38.45-87.25	52.50 \pm 22.58
36	20	54.29	8.68	42.53-78.30	54.29 \pm 17.36
37	21	59.04	10.80	42.48-86.91	59.04 \pm 21.60

hematocrit and hemoglobin after birth. Longitudinal study and blood sampling after birth should be considered to complete the further study.

The reference values of the MCA PSV from the present study can be used to predict fetal anemia at Srinagarind hospital, Faculty of Medicine, Khon Kaen University, Khon Kaen, Thailand.

Conclusion

A normogram of fetal MCA PSV at 20 to 37 weeks of gestation at Srinagarind hospital was generated. The MCA PSV was increased as gestational age advanced from 24.34 cm/sec (SD 3.91) at 20 weeks to 59.04 cm/sec (SD 10.80) at 37 weeks.

Potential conflicts of interest

None.

References

1. Weiner CP, Williamson RA, Wenstrom KD, Sipes SL, Widness JA, Grant SS, et al. Management of fetal hemolytic disease by cordocentesis. II. Outcome of treatment. *Am J Obstet Gynecol* 1991; 165: 1302-7.
2. Moise KJ Jr. The usefulness of middle cerebral artery Doppler assessment in the treatment of the fetus at risk for anemia. *Am J Obstet Gynecol* 2008; 198: 161-4.
3. Oepkes D. Invasive versus non-invasive testing in red-cell alloimmunized pregnancies. *Eur J Obstet Gynecol Reprod Biol* 2000; 92: 83-9.
4. Oepkes D, Seaward PG, Vandenbussche FP, Windrim R, Kingdom J, Beyene J, et al. Doppler ultrasonography versus amniocentesis to predict fetal anemia. *N Engl J Med* 2006; 355: 156-64.
5. Zimmerman R, Carpenter RJ Jr, Durig P, Mari G. Longitudinal measurement of peak systolic velocity in the fetal middle cerebral artery for monitoring pregnancies complicated by red cell alloimmunisation: a prospective multicentre trial with intention-to-treat. *BJOG* 2002; 109: 746-52.
6. Mari G, Deter RL, Carpenter RL, Rahman F, Zimmerman R, Moise KJ Jr, et al. Noninvasive diagnosis by Doppler ultrasonography of fetal anemia due to maternal red-cell alloimmunization. Collaborative Group for Doppler Assessment of the Blood Velocity in Anemic Fetuses. *N Engl J Med* 2000; 342: 9-14.
7. Mari G. Middle cerebral artery peak systolic velocity for the diagnosis of fetal anemia: the

- untold story. *Ultrasound Obstet Gynecol* 2005; 25: 323-30.
8. Mari G, Adrignolo A, Abuhamad AZ, Pirhonen J, Jones DC, Ludomirsky A, et al. Diagnosis of fetal anemia with Doppler ultrasound in the pregnancy complicated by maternal blood group immunization. *Ultrasound Obstet Gynecol* 1995; 5: 400-5.
 9. Tongsong T, Wanapirak C, Sirichotiyakul S, Tongprasert F, Srisupundit K. Middle cerebral artery peak systolic velocity of healthy fetuses in the first half of pregnancy. *J Ultrasound Med* 2007; 26: 1013-7.
 10. Rujiwetpongstorn J, Phupong V. Doppler waveform indices of the Middle Cerebral Artery of normal fetuses in the first half of pregnancy in the Thai population. *Arch Gynecol Obstet* 2007; 276: 351-4.
 11. Tarzamni MK, Nezami N, Sobhani N, Eshraghi N, Tarzamni M, Talebi Y. Nomograms of Iranian fetal middle cerebral artery Doppler waveforms and uniformity of their pattern with other populations' nomograms. *BMC Pregnancy Childbirth* 2008; 8: 50.
 12. Bahlmann F, Reinhard I, Krummenauer F, Neubert S, Macchiella D, Wellek S. Blood flow velocity waveforms of the fetal middle cerebral artery in a normal population: reference values from 18 weeks to 42 weeks of gestation. *J Perinat Med* 2002; 30: 490-501.

ค่า *peak systolic velocity* ของหลอดเลือด *middle cerebral artery* ในกลุ่มทารกปกติอายุครรภ์ 20 ถึง 37 สัปดาห์ที่โรงพยาบาลศรีนครินทร์

ปิยะมาส ศักดิ์ศิริวัฒนไธ, จตุพร ดวงกำ, ถวัลย์วงศ์ รัตนสิริ, รัตนา คำวิสัยศักดิ์

วัตถุประสงค์: เพื่อศึกษาค่า *peak systolic velocity* ของหลอดเลือด *middle cerebral artery* ในกลุ่มทารกปกติอายุครรภ์ 20 ถึง 37 สัปดาห์ในโรงพยาบาลศรีนครินทร์

วัสดุและวิธีการ: การวิจัยเชิงพรรณนา (*prospective descriptive cross-sectional study*) นำสตรีตั้งครรภ์เดี่ยว สุขภาพแข็งแรง อายุครรภ์ตั้งแต่ 20 ถึง 37 สัปดาห์ ที่ตรวจไม่พบความผิดปกติของทารกในครรภ์ อย่างน้อย 18 คนต่ออายุครรภ์ เข้ารับการตรวจคลื่นเสียงความถี่สูงชนิดดอปเปลอร์เพื่อหาค่า *peak systolic velocity* ของหลอดเลือดแดง *middle cerebral artery* ของทารกปกติในครรภ์

ผลการศึกษา: ค่า *peak systolic velocity* ของหลอดเลือด *middle cerebral artery* ในกลุ่มทารกปกติอายุครรภ์ 20 ถึง 37 สัปดาห์ ในโรงพยาบาลศรีนครินทร์ มีค่าเพิ่มขึ้นตามอายุครรภ์จาก 24.34 เซนติเมตร/วินาที (*SD* 3.91) ที่อายุครรภ์ 20 สัปดาห์ ถึง 59.04 เซนติเมตร/วินาที (*SD* 10.80) ที่อายุครรภ์ 37 สัปดาห์

สรุป: ได้ตารางและกราฟที่แสดงค่า *peak systolic velocity* ของหลอดเลือด *middle cerebral artery* ในกลุ่มทารกปกติอายุครรภ์ 20 ถึง 37 สัปดาห์ สำหรับใช้อ้างอิง ณ ห้องตรวจครรภ์ แผนกผู้ป่วยนอก คณะแพทยศาสตร์ โรงพยาบาลศรีนครินทร์ มหาวิทยาลัยขอนแก่น