

Case Report

Negative Pressure Wound Therapy for Traumatic Foot and Ankle Wound: Two Cases Report and Review Literature

Tanawat Vaseenon MD*,
Wipoo Somsuk MD*

* Department of Orthopaedics, Faculty of Medicine, Chiang Mai University, Chiang Mai, Thailand

This report describes treatment of patients who presented with open soft tissue injuries and Achilles tendon tears at the posterior ankle and heel from accidents. After appropriate debridement and/or Achilles tendon repair, a large wound defect remained as well as a bare Achilles tendon. Negative pressure wound therapy was applied to the Achilles tendon to promote wound healing and healthy granulation. The size of wound decreased and the Achilles tendon was completely covered with granulation within two weeks. The remaining granulation tissue without tendon exposure was completely healed with secondary wound healing and/or skin grafting during the following two weeks after which motion of the ankle was satisfactory. Negative pressure wound therapy is an optional treatment for the complicated wounds where reconstructive surgery with a skin flap cannot be performed.

Keywords: Negative pressure wound therapy, Foot ankle, Trauma, Wound, Vacuum dressing

J Med Assoc Thai 2015; 98 (1): 111-6

Full text. e-Journal: <http://www.jmatonline.com>

Foot and ankle injuries are the most frequency-injured parts of the body in polytrauma patients involved in traffic accidents or falls⁽¹⁾. These patients also show several injury mechanisms that produce both bone and soft-tissue disruption requiring selection of treatment from a wide array of options. Management of a complicated wound defect is one of the most challenging surgical procedures, especially with when the wound extends deep into musculoskeletal structures such as bones and tendons. Tendon exposure is a major problem and can cause the patient to suffer from disability following prolonged treatment and an inability to heal due to an inappropriate environment, tendon necrosis and infection⁽²⁾.

The appropriate treatment for a complicated wound defect with a bare tendon is reconstructive surgery with a skin flap that can preserve tendon motion when the wound defect is over a joint or other mobile part of body. Negative pressure wound therapy (NPWT) is one of the options recommended for virtually all kinds of acute and chronic wounds to accelerate healing including pressure wounds, diabetic leg ulcers, lower leg wounds, surgical incision, traumatic wounds, burns and wounds after skin grafting⁽³⁾. In cases of traumatic foot and ankle injuries

when there are bone and soft tissue injury, NPWT may help promote wound healing, shorten the duration of wound treatment and decrease the role of skin flap reconstructive surgery.

The objective of the present study is to report results of treatment using NPWT in complicated foot and ankle injuries including a wound defect over the posterior ankle joint in combination with an Achilles tendon rupture and a chronically infected wound with a posterior heel defect and bone exposure.

Case Report

Case 1

A 40-year-old man was admitted to Chiang Mai University Hospital with multiple lacerations and with bone exposure on the dorsal and medial aspects of the foot from a motorcycle accident. The posterior ankle wound was 10 cm in length and 6 cm in width. The Achilles tendon was completely avulsed from the calcaneal attachment with two centimeters of bone-tendon gap. The anterior wound of the foot had a fracture of the tars metatarsal joint. Radiographic studies showed a fracture dislocation of the Lisfranc joint and a small avulsion fracture of the Achilles tendon. The diagnoses given were an open ruptured Achilles tendon and an open fracture dislocation of the Lisfranc joint with multiple lacerations.

Surgical debridement and temporary pin fixation were immediately performed across the

Correspondence to:

Vaseenon T, Department of Orthopaedics, Faculty of Medicine, Chiang Mai University, Chiang Mai 50200, Thailand.

Phone: 053-945-544, Fax: 053-946-442

E-mail: tvaseenon@yahoo.com

mid-foot to stabilize the Lisfranc joint. The Achilles tendon was reattached with anchor sutures. Wounds received a primary closure; however, the posterior wound defect was sutured, but still left 5x5 cm gap with exposure of the Achilles tendon (Fig. 1). Post-operatively, wet dressings were applied for three days to the wound defect to ensure that the wound had no active infection. Then, negative pressure wound therapy was applied to stimulate the growth of granulation tissue over the wound defect.

RENASYS@GO (Smith&Nephew Co. Ltd.) which is a mobile system for generating negative pressure for wound therapy was used. The negative pressure was set at -80 mm with intermittent mode (5 minutes “on”; 2 minutes “off” regime)⁽⁴⁻⁷⁾. Wound dressing and vacuum changes were performed every three days. Multiple vertical cuts were performed over the paratenon of the Achilles tendon to stimulate the blood supply and growth of granulation tissue^(8,9). Intrasite Gel (Smith&Nephew Co. Ltd.) was applied each time the vacuum dressing was changed to promote granulation of the tissue on the Achilles tendon⁽¹⁰⁾. The patient was restricted to non-weight bearing ambulation using crutches during the application of negative pressure wound therapy, but active ankle motion was permitted. After the Achilles tendon was completely covered with granulated tissue, the negative pressure wound therapy was discontinued. Wound dressing was performed using the gel and hydrocellular foam until secondary wound healing was complete (Fig. 2).

The wound defect that exposed the Achilles tendon was covered with granulated tissue using the mobile negative wound pressure therapy within two weeks. Initially, the wound defect measured 5x5 cm gap. Following two weeks of negative pressure wound therapy, the wound size decreased to 3.5 cm in length and 3 cm in width and demonstrated complete granulated tissue covering of the Achilles tendon. Two weeks after the operation, the patient was discharged from the hospital and started exercising: ambulation with crutches and continued active motion of the ankle. Four weeks after the operation, the wound was completely covered by secondary healing. Wound dressings with the gel and hydrocellular foam systems were performed. Six weeks after the operation, the pins were removed and a gentle active assistive range of motion exercise of the ankle was started. There were no signs of chronic wound infection or osteomyelitis. Ten weeks after surgery, the Achilles tendon function was within normal limits. The range of motion for the ankle was 60 degrees in plantar flexion and 15 degrees

in dorsiflexion. The patient achieved a normal gait without assistive devices one year after surgery (Fig. 3, 4). The patient could wear regular shoes without pain and return to normal daily activities.

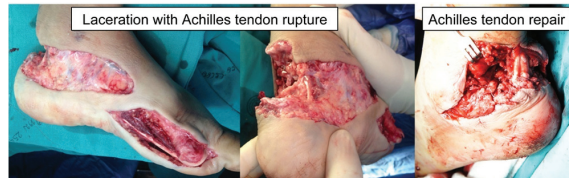

Fig. 1 Large avulsion wound at posterior ankle with Achilles tendon rupture and open Lisfranc joint fracture dislocation. The Achilles tendon was reattached with anchor suturing technique.

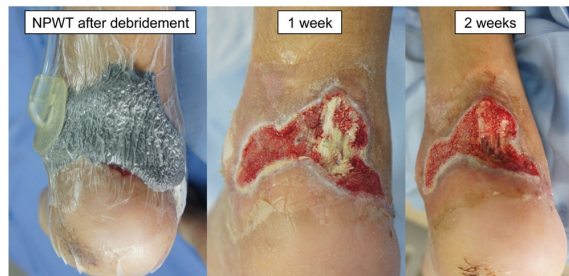

Fig. 2 Open Achilles tendon wound with vacuum dressing, after one week of NPWT and after two weeks of NPWT.

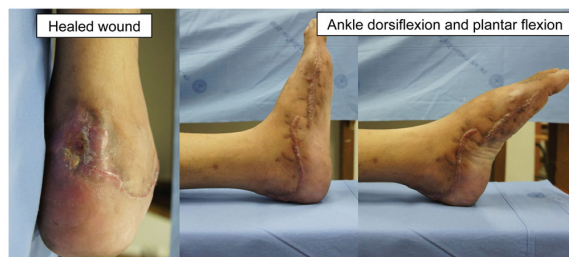

Fig. 3 Complete healing of posterior wound. Five degrees of ankle dorsiflexion and forty-five degrees of ankle plantar flexion were achieved.

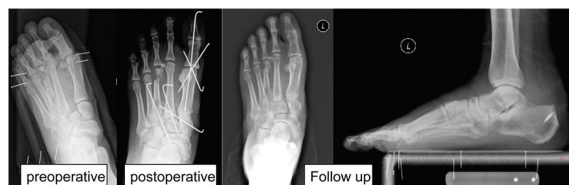

Fig. 4 Radiographs showing initial and postoperative treatment of Lisfranc joint fracture and dislocation and avulsion fracture of Achilles tendon insertion.

Case 2

A 35-year-old woman presented with a chronic wound at the posterior heel area including exposure of the calcaneus and Achilles tendon. She had a motorcycle accident 3 months previously, falling onto the road causing soft tissue loss at the heel. She was treated twice with surgical debridement but both attempts at split thickness skin grafts in a small district hospital failed. The wound was infected and showed necrotic tissue over the periosteum of the calcaneus and Achilles tendon (Fig. 5). Radiographic studies showed no fracture but there was an osteolytic lesion at the calcaneus. There was also no periosteal reaction on the bone. Laboratory investigation discovered inflammation, high ESR and low CRP levels. After surgical debridement, 2 cm by 1.5 cm of distal Achilles tendon and calcaneus were exposed. The wound could not be closed with primary sutures due to infection and tension effects (Fig. 6).

The wound was dressed by using nanocrystalline silver (Acticoat) as an antimicrobial agent for chemical debridement for three days. The NPWT (RENASYS@GO, Smith&Nephew Co. Ltd.) was applied on the surgically debrided wound with the bone and tendon exposed. The Acticoat was inserted deep into the wound bed to ensure all the infected wound was coated. Single polyurethane foam was then applied over the Acticoat and the negative pressure set was connected. Pressure was set at 80 mmHg with intermittent mode. Bedside wound dressing and vacuum changes were completed every 3 days. Seven days after the initial treatment, the exposed bone and Achilles tendon were completely covered with granulation tissue. The NPWT was used continuously for another 7 days to promote granulation tissue for further skin coverage (Fig. 7). The patient was encouraged to walk during the initial 7 days, carry out an active range of ankle motion exercises and was then treated as an outpatient case.

Two weeks following discharge, the wound was treated to encourage the growth of additional granulation tissue by using Intrasite Gel and hydrocellular foam. Eight weeks after surgical debridement, the wound was completely filled with granulation tissue and had decreased in size. At that time, split thickness skin grafting was carried out (Fig. 8). Four months after surgery, the patient could walk without any complications such as chronic wound infection or osteomyelitis and Achilles tendon function was within normal limited. The patient could also wear normal shoes without pain and return to normal daily activities.

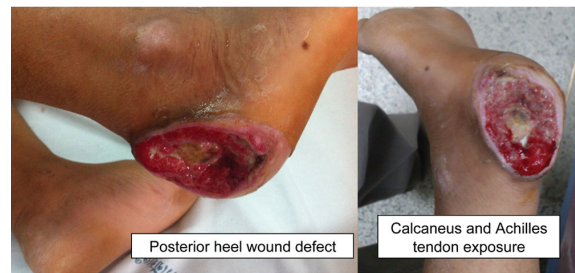


Fig. 5 A large posterior heel wound defect with bone and Achilles tendon exposure.

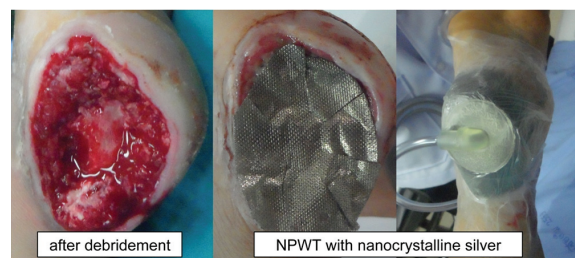


Fig. 6 Post-operative surgical wound exposed calcaneus and Achilles tendon. The negative pressure wound therapy (NPWT) with nanocrystalline silver foam was applied.

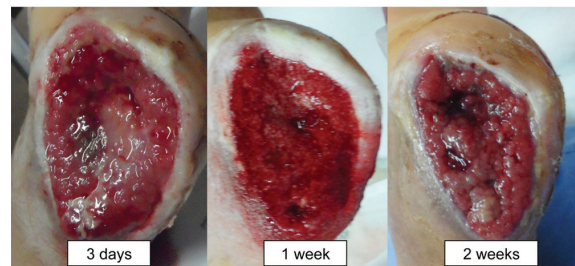


Fig. 7 The wound after NPWT and silver dressing.

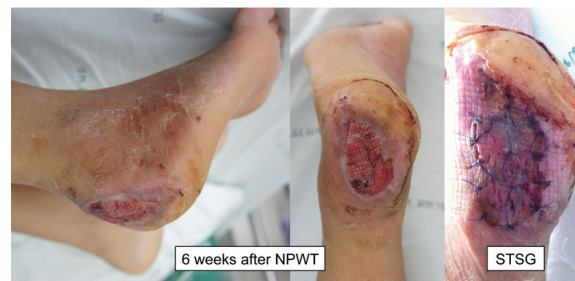

Fig. 8 Eight weeks after treatment (two weeks of NPWT plus silver dressing following by six weeks of combination of hydrogel and hydrocellular dressing), the wound was covered with split thickness skin graft (STSG).

Discussion

Open wounds with bone or tendon exposure are often found associated with foot and ankle injuries. The appropriate management is reconstructive surgery with a skin flap that can preserve tendon motion when the wound defect is over a joint or other mobile part of body. Negative pressure wound therapy is a good adjunct treatment that can decrease the duration of wound treatment and decrease the extent of skin flap reconstructive surgery in complicated wound defects.

Negative pressure wound therapy is also indicated in chronic wounds, traumatic wounds and orthopedic salvage, infected sternal wounds, management of the open abdomen, enterocutaneous fistulae, burn wounds, skin grafts and dermal substitutes, as well as systemic disease conditions such as myoglobinuria^(11,12). Wounds associated with malignancy, untreated osteomyelitis, non-enteric or unexplored fistulas, necrotic tissue with eschar present, placement over exposed blood vessels or organs are contraindications for this treatment^(13,14). Controlled negative pressure therapy can assist wound healing by providing a moist and protected environment thus reducing peripheral edema around the wound, stimulating circulation to the wound bed, decreasing bacterial colonization and increasing the rate of granulation tissue formation and epithelialization⁽¹⁴⁾.

In case of trauma, NPWT has many roles in different stages of treatment including soft tissue traumatic wounds and open fracture wounds. NPWT may also be used for temporary wound coverage following debridement and before definitive closure and may additionally be used to down scale the complexity of closure procedure. In cases involving grafting procedures, consideration of NPWT is recommended in the treatment of wounds, in patients with a high risk of graft loss and to improve the rate of graft success⁽¹⁵⁾. There are many benefits to using NPWT including significantly faster rates of granulation tissue generation compared to conventional therapy, lower incidence of complications in wound treatment, shorter hospitalization time and less procedure-related morbidity⁽¹⁶⁻¹⁹⁾. Also, patients report that the treatment with NPWT is more comfortable than conventional therapies⁽²⁰⁾.

In case of tendon exposure, NPWT dramatically accelerates the preparation of exposed tendons helping ensure acceptance of skin grafts. Heugel et al reported that the use of NPWT resulted in the achievement of 99% acceptance of skin grafts in cases of non-viable paratenon of exposed Achilles tendon wound defects

within two weeks⁽¹⁹⁾. Repta et al described the use of NPWT and skin grafting as an important contribution to the management of soft tissue defects over the Achilles tendon⁽²¹⁾.

Infection is one of the main problems that can impede any process of wound healing, so an important first step should be the eradication of the infection first by adequate surgical debridement. One study found that following open lower limb trauma, soft tissue coverage occurs within 3 days of injury. Additionally, soft tissue growth begins immediately following fracture fixation with exposed metal ware, minimizing pre-flap wound infection and optimizing surgical outcomes. NPWT provides effective temporary wound coverage, but does not allow a delay in definitive free-flap reconstruction⁽²²⁾.

In the present study, secondary healing was used because it avoids the need for the sacrifice of a donor site required for split-thickness skin grafts. Two weeks of NPWT was sufficient to achieve full skin coverage; no infection was detected. Dressings were changed every three days. Non-weight bearing ambulation with crutches was allowed during the wound dressing period. Circulation from ambulation might also be one of the important factors promoting faster tissue healing⁽¹⁴⁾. In these cases, hydrocellular foam and gel were used to help to promote wound healing through granulation of tissue and, in some instances, secondary healing.

Regarding to data from literature reviews, using NPWT could cost less when compared with number of daily wound dressing changes and treatment visits⁽²³⁾. It is also included the effectiveness of NPWT in comparison to other treatments⁽²⁴⁾. The advantages of NPWT for traumatic wound are faster healing times, lower rate of hospitalization, wound problems⁽²⁵⁾. It is also included cost benefit that is lower nursing expenses⁽²⁶⁾. However, the disadvantage is higher material expense. The most serious adverse events of NPWT are infection and blood loss. They can be prevented by patient and wound selection such as no bleeding risk or coagulation abnormalities or no active wound infection⁽²⁷⁾. In the present cases, the advantages of NPWT were to provide temporary wound cover, to reduce complexity of flap reconstruction, to manage wound fluid and edema and to allow patient mobility.

In summary, treatment of a wound defect close to the joint is critical to achieving the important treatment goal of complete wound coverage with joint motion preservation. Previously, after deep structures

were covered with granulation tissue, a skin flap to achieve that goal followed the treatment. Unfortunately, in some cases the skin flap treatment cannot be performed because of the ankle joint motion desired such as in the case of Achilles tendon rupture treatment. Treatment with the NPWT on an open wound defect with Achilles tendon ruptures has showed acceptable results in terms of wound coverage and ankle motion. NPWT can also be used in cases of wound defects with bone exposure to increase the rate of granular tissue generation and to decrease wound defect closure time as in the case of chronic wound defects of the heel with bone and tendon exposure.

Acknowledgement

The authors wish to thank G Lamar Robert, Sirichai Luevitoonvechkij, Areerak phanphaisarn, Thippakorn Kanthawong and the residents for their help in the present study.

What is already known on this topic?

Using negative pressure wound therapy in traumatic wounds is very useful in reducing the wound size, promoting granulation and control moisture balance. It is also used for temporary wound care in complex wounds that have bone or tendon exposure. However, there were not many reports showing the foot and ankle wound with Achilles tendon exposure having been treated with negative pressure wound therapy along with its results.

What this study adds?

Negative pressure wound therapy can be used in wounds at the foot and ankle area that have Achilles tendon exposure. The present study showed good results with long-term outcome. The complexity of soft tissue procedure as skin flap can be avoided due to rapid granulation growth and wound improvement.

Potential conflicts of interest

None.

References

1. Probst C, Richter M, Lefering R, Frink M, Gaulke R, Krettek C, et al. Incidence and significance of injuries to the foot and ankle in polytrauma patients-an analysis of the Trauma Registry of DGU. *Injury* 2010; 41: 210-5.
2. Saxena A, Maffulli N, Nguyen A, Li A. Wound complications from surgeries pertaining to the Achilles tendon: an analysis of 219 surgeries. *J Am Podiatr Med Assoc* 2008; 98: 95-101.
3. Vikatmaa P, Juutilainen V, Kuukasjarvi P, Malmivaara A. Negative pressure wound therapy: a systematic review on effectiveness and safety. *Eur J Vasc Endovasc Surg* 2008; 36: 438-48.
4. Borgquist O, Ingemansson R, Malmsjo M. Wound edge microvascular blood flow during negative-pressure wound therapy: examining the effects of pressures from -10 to -175 mmHg. *Plast Reconstr Surg* 2010; 125: 502-9.
5. Borgquist O, Ingemansson R, Malmsjo M. The influence of low and high pressure levels during negative-pressure wound therapy on wound contraction and fluid evacuation. *Plast Reconstr Surg* 2011; 127: 551-9.
6. Morykwas MJ, Argenta LC, Shelton-Brown EI, McGuirt W. Vacuum-assisted closure: a new method for wound control and treatment: animal studies and basic foundation. *Ann Plast Surg* 1997; 38: 553-62.
7. Lindstedt S, Malmsjo M, Gesslein B, Ingemansson R. Evaluation of continuous and intermittent myocardial topical negative pressure. *J Cardiovasc Med (Hagerstown)* 2008; 9: 813-9.
8. Maffulli N, Testa V, Capasso G, Bifulco G, Binfield PM. Results of percutaneous longitudinal tenotomy for Achilles tendinopathy in middle- and long-distance runners. *Am J Sports Med* 1997; 25: 835-40.
9. Testa V, Capasso G, Benazzo F, Maffulli N. Management of Achilles tendinopathy by ultrasound-guided percutaneous tenotomy. *Med Sci Sports Exerc* 2002; 34: 573-80.
10. Kaya AZ, Turani N, Akyuz M. The effectiveness of a hydrogel dressing compared with standard management of pressure ulcers. *J Wound Care* 2005; 14: 42-4.
11. Argenta LC, Morykwas MJ, Marks MW, DeFranzo AJ, Molnar JA, David LR. Vacuum-assisted closure: state of clinic art. *Plast Reconstr Surg* 2006; 117: 127S-42S.
12. Plikaitis CM, Molnar JA. Subatmospheric pressure wound therapy and the vacuum-assisted closure device: basic science and current clinical successes. *Expert Rev Med Devices* 2006; 3: 175-84.
13. Mendez-Eastman S. Guidelines for using negative pressure wound therapy. *Adv Skin Wound Care* 2001; 14: 314-22.
14. Gupta S, Baharestani M, Baranoski S, de Leon J, Engel SJ, Mendez-Eastman S, et al. Guidelines for managing pressure ulcers with negative

- pressure wound therapy. *Adv Skin Wound Care* 2004; 17 (Suppl 2): 1-16.
15. Krug E, Berg L, Lee C, Hudson D, Birke-Sorensen H, Depoorter M, et al. Evidence-based recommendations for the use of Negative Pressure Wound Therapy in traumatic wounds and reconstructive surgery: steps towards an international consensus. *Injury* 2011; 42 (Suppl 1): S1-12.
 16. Gregor S, Maegele M, Sauerland S, Krahn JF, Peinemann F, Lange S. Negative pressure wound therapy: a vacuum of evidence? *Arch Surg* 2008; 143: 189-96.
 17. Armstrong DG, Lavery LA. Negative pressure wound therapy after partial diabetic foot amputation: a multicentre, randomised controlled trial. *Lancet* 2005; 366: 1704-10.
 18. Page JC, Newswander B, Schwenke DC, Hansen M, Ferguson J. Retrospective analysis of negative pressure wound therapy in open foot wounds with significant soft tissue defects. *Adv Skin Wound Care* 2004; 17: 354-64.
 19. Heugel JR, Parks KS, Christie SS, Pulito JF, Zegzula DH, Kemalyan NA. Treatment of the exposed Achilles tendon using negative pressure wound therapy: a case report. *J Burn Care Rehabil* 2002; 23: 167-71.
 20. Braakenburg A, Obdeijn MC, Feitz R, van Rooij IA, van Griethuysen AJ, Klinkenbijn JH. The clinical efficacy and cost effectiveness of the vacuum-assisted closure technique in the management of acute and chronic wounds: a randomized controlled trial. *Plast Reconstr Surg* 2006; 118: 390-7.
 21. Repta R, Ford R, Hoberman L, Rechner B. The use of negative-pressure therapy and skin grafting in the treatment of soft-tissue defects over the Achilles tendon. *Ann Plast Surg* 2005; 55: 367-70.
 22. Liu DS, Sofiadellis F, Ashton M, MacGill K, Webb A. Early soft tissue coverage and negative pressure wound therapy optimises patient outcomes in lower limb trauma. *Injury* 2012; 43: 772-8.
 23. Soares MO, Bojke L, Dumville J, Iglesias C, Cullum N, Claxton K. Methods to elicit experts' beliefs over uncertain quantities: application to a cost effectiveness transition model of negative pressure wound therapy for severe pressure ulceration. *Stat Med* 2011; 30: 2363-80.
 24. Soares MO, Dumville JC, Ashby RL, Iglesias CP, Bojke L, Adderley U, et al. Methods to assess cost-effectiveness and value of further research when data are sparse: negative-pressure wound therapy for severe pressure ulcers. *Med Decis Making* 2013; 33: 415-36.
 25. Schwien T, Gilbert J, Lang C. Pressure ulcer prevalence and the role of negative pressure wound therapy in home health quality outcomes. *Ostomy Wound Manage* 2005; 51: 47-60.
 26. Moues CM, van den Bemd GJ, Meerding WJ, Hovius SE. An economic evaluation of the use of TNP on full-thickness wounds. *J Wound Care* 2005; 14: 224-7.
 27. Mirsaidi N. Negative pressure wound therapy: use with care. *Nursing* 2010; 40: 64, 66.

การรักษาแผลบริเวณเท้าและข้อเท้าที่เกิดจากอุบัติเหตุโดยใช้แรงดันสูญญากาศ การรายงานผู้ป่วยและการทบทวนวรรณกรรม

ธนวัฒน์ วะสินนท์, วิภู สมสุข

เป็นการรายงานและการทบทวนวรรณกรรม กรณีผู้ป่วยสองรายที่มีแผลเปิด เนื้อเยื่อบาดเจ็บ เอ็นร้อยหวายขาดที่ด้านหลังของข้อเท้าและเท้า จากอุบัติเหตุหลังทำการล้างแผลและหรือการซ่อมเอ็นร้อยหวาย ยังมีบางส่วนของเอ็นร้อยหวายปรากฏอยู่ในแผลขนาดใหญ่ การรักษาโดยแรงดันสูญญากาศได้นำมาใช้วางที่แผลเพื่อกระตุ้นการหายของแผลและการสร้างเนื้อเยื่อ ขนาดของแผลมีขนาดเล็กถึง เอ็นร้อยหวายมีเนื้อเยื่อมาคลุมในสองสัปดาห์ เนื้อเยื่อที่ไม่มีเอ็นร้อยหวายหายโดยการปล่อยให้แผลปิดเองและหรือการย้ายหนังมาปิดในสองสัปดาห์ สุดท้ายข้อเท้าสามารถขยับได้ดี การรักษาโดยใช้แรงดันสูญญากาศเป็นวิธีการรักษาที่วิธีหนึ่ง ในกรณีแผลที่ซับซ้อนและไม่ต้องการผ่าตัดย้ายหนังและหลอดเลือดในการรักษา