

# Cosmetic Outcome of Wound Closure between Steri-Strips (3M™ Steri-Strip) and Simple Interrupted Nylon 6-0 Sutures in Out-Patient Cervical Lymph Node Excision: A Randomized Controlled Trial

Wilaporn Phakdeedindan MD<sup>1</sup>, Chayapak Kamma MD<sup>1</sup>

<sup>1</sup> Thammasat Chalerm Prakiat Hospital, Thammasat University, Pathum Thani, Thailand

**Objective:** To compare the aesthetic outcome of cervical lymph node excision skin closure between Steri-Strips closure and simple interrupted sutures using Nylon 6-0.

**Materials and Methods:** The present study was a single-blinded randomized controlled trial of forty patients with cervical lymph node excision. They were randomized into two groups of twenty. The first group was allocated to close the skin by simple interrupted sutures with Nylon 6-0, the other group received the Steri-Strips for skin closure. Complications were observed at the first and second week. The aesthetic outcomes for skin closure were evaluated at 12 weeks postoperatively using the predetermined Sakka's cosmetic assessment criteria and scoring system.

**Results:** There was no statistically significant difference between the two groups in terms of gender, age, length of surgical wound, and pathology. The Steri-Strips group showed significantly lower Sakka's aesthetic score compared to the 6-0 Nylon sutures group ( $6.25 \pm 0.85$  and  $7.75 \pm 1.33$ ,  $p < 0.001$ ). There was no significant difference in aesthetic outcomes between genders. Moreover, the operative time of the Steri-Strips group was significantly less than that of the 6-0 Nylon sutures group ( $2.2 \pm 0.41$  and  $4.75 \pm 0.44$  minutes,  $p < 0.001$ ).

**Conclusion:** Skin closure with Steri-Strips gave better aesthetic outcomes compared to the 6-0 Nylon sutures ( $p < 0.001$ ). However, the aesthetic outcomes were assessed by physicians, so the patients' satisfaction could not be assessed.

**Keywords:** Lymph node biopsy; Hypertrophic scar; Keloid; Cosmetic outcome; Steri-strip

Received 9 March 2021 | Revised 14 May 2021 | Accepted 14 May 2021

**J Med Assoc Thai 2021;104(7):1088-94**

**Website:** <http://www.jmatonline.com>

Cervical lymph node excision is a necessary choice in diagnostic work-up and confirmation. Traditional incision design most often follows Langer's lines, which produces less tension on surgical wounds and may prevent hypertrophic scar formation<sup>(1)</sup>. The surgical wounds are often traditionally closed in two layers. The first layer is subcutaneous tissue. Skin is the second layer. It is composed of the epidermis and the dermis. After the skin and deeper tissues have healed, the scar

develops through four different stages of healing<sup>(2)</sup>. The scars have psychological, aesthetic, and physical implications for affected patients, regardless of their origin. Improper incision designs are the primary reason for hypertrophic scar response observed in a remodeling wound<sup>(3)</sup>. The primary goals of treating wounds in general and skin incisions in particular are rapid closure and creating the least visible scar<sup>(4)</sup>. Suture material and closure technique can affect cosmetic outcomes<sup>(5,6)</sup>. Although there are many kinds of wound closure such as synthetic sutures, staples, adhesive glue, and adhesive tapes, the most commonly used are synthetic sutures<sup>(4)</sup>. Synthetic non-absorbable monofilament sutures including nylon, polypropylene, and polybutester are commonly used in cutaneous procedures<sup>(5)</sup>. Many surgeons prefer non-absorbable monofilament sutures for their easy gliding through tissue, easy handling, minimal inflammatory response, and unlikeliness to break prematurely<sup>(7)</sup>. Gilman was the first in modern literature to evaluate sutureless skin closure. Healing of incisions closed with sutures was compared to closed with plastic

## Correspondence to:

Kamma C.

Thammasat Chalerm Prakiat Hospital, Thammasat University, Pathum Thani 12120, Thailand.

**Phone:** +66-85-3137315

**Email:** [nongnoo.paepe@gmail.com](mailto:nongnoo.paepe@gmail.com)

## How to cite this article:

Phakdeedindan W, Kamma C. Cosmetic Outcome of Wound Closure between Steri-Strips (3M™ Steri-Strip) and Simple Interrupted Nylon 6-0 Sutures in Out-Patient Cervical Lymph Node Excision: A Randomized Controlled Trial. *J Med Assoc Thai* 2021;104:1088-94.

[doi.org/10.35755/jmedassocthai.2021.07.12306](https://doi.org/10.35755/jmedassocthai.2021.07.12306)

adhesive tape<sup>(8)</sup>. Surgical adhesive tapes usually contain adhesive backing consisting of iso-octyl-acrylate and n-vinyl-pyrrolidone<sup>(9)</sup>. The advantages of adhesive tape are that it is non-allergenic, non-irritating, water resistant, vapor permeable, decreases the overall cost, and reduces operative time. Furthermore, this technique allows for faster restoration of tensile strength equal or superior at 10 days to the strength of sutured wounds<sup>(10,11)</sup>. Sakka et al used subcuticular suturing using absorbable material (Dexon 3/0) with sterile strips in one group of patients and percutaneous transdermal continuous running suture using non-absorbable material (silk 3-0) in another group undergoing total hip replacement. The cosmetic outcome in the subcuticular suturing using absorbable material (Dexon 3/0) and sterile strips was better than transdermal continuous running suture using non-absorbable material (silk 3-0)<sup>(12)</sup>. Esmailian et al compared the scar formation of traumatic facial wounds between the two groups, one used wound tape and the other used interrupted transdermal non-absorbable suturing. The scar formation in wounds shorter than 20 mm was significantly less in the wound tape group. There was no infection in either of the studied populations<sup>(13)</sup>. Felix et al treated 15 patients with surgical incisions using adhesive film (Clozex) on the first half of each wound and simple running suture with prolene 4-0 on the rest. The cosmetic outcome of wound closure utilizing adhesive film seemed to be as good as simple running suture, but running suture was much more time-consuming to apply than adhesive film<sup>(14)</sup>. Javadi et al compared methods for skin closure after appendectomy in uncomplicated appendicitis patients. Subcuticular suturing with absorbable 4-0 monofilament monocril suture supported by three Steri-Strips™ was used on one group of patients, while three interrupted mattress sutures with non-absorbable 4/0 nylon sutures was used on the control group (n=35). The patients using absorbable subcuticular suturing and Steri-Strips™ were more satisfied than the control group in terms of appearance and width of surgical site scar. None of the wounds developed any infection<sup>(15)</sup>.

Although sutures and sterile strips are frequently used for skin closure, there is no literature comparing cosmetic outcomes of these skin closure methods in cervical lymph node excision.

The Thammasat Chalerm Prakiat Hospital based price of Steri-Strips (6×100 mm 3M™ Steri-Strip™, Minnesota, U.S.) is 23.54 Baht, while the cost of non-absorbable sutures (Nylon 6-0 12 mm, ETHILON™, New Jersey, U.S.) is 75 baht. The purpose of the

present study was to compare aesthetic outcomes of skin closure using simple interrupted non-absorbable sutures versus sterile strips in cervical lymph node excision.

## Materials and Methods

### Patients and ethics

The present study was approved by the Thammasat University Ethics Committee (MTU-EC-OL-0-123/61). Patients were recruited from Otolaryngology Out-patient Unit, Thammasat Chalerm Prakiat Hospital, Thammasat University. The period of study was between February 1, 2018 and January 1, 2019. All patients scheduled for an elective cervical lymph node excision for various indications agreed to participate in the present study were included and provided signed informed consents.

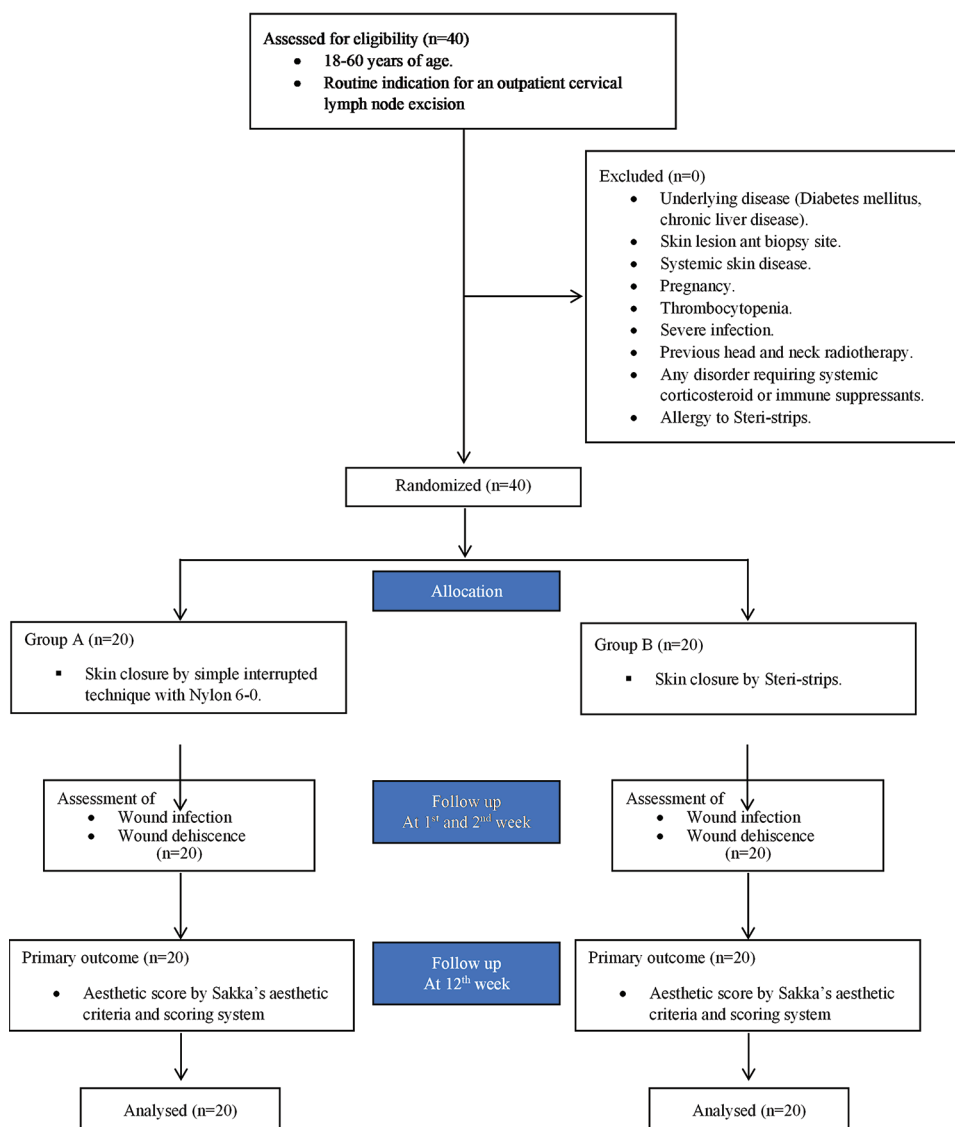
### Inclusion and exclusion criteria

Inclusion criteria were adult patients aged 18 to 60 years with a routine indication for an outpatient cervical lymph node excision. Exclusion criteria were patients with underlying disease such as diabetes mellitus (DM) or chronic liver disease, skin lesion, skin disease, pregnancy, thrombocytopenia, severe infection, previous head and neck radiotherapy, allergy to Steri-Strips, or any disorder requiring steroid or immune suppressants (Figure 1).

### Sample size determination

The sample size of the present study was, to determine the strength of 80% statistical power to detect a mean difference of one unit on the rating scale. A type I error rate of 5% and type II error rate of 20% were assumed<sup>(16)</sup>. From a previous study, the mean score and standard deviation for simple interrupted non-absorbable sutures was 8.68±0.84, while that of Steri-Strips was 9.6±1.25(16). After applying these values to equation 1, the sample size per group required for near accuracy of the standard deviation determination, and hence, the adequacy of the present study sample, was found to be greater than or equal to 20.

All participating patients were randomized by computer into two groups by blocks of four. Allocation concealment was assigned by sequentially sealed opaque envelopes. A nurse with no involvement in the present trial prepared and opened the envelopes when the subcutaneous tissue was closed. The subcutaneous tissue was sutured by subcuticular technique with Vicryl4-0 in both groups. In the first group (A) of twenty patients, the skin was closed



**Figure 1.** Participant Flow Chart.

by simple interrupted technique with Nylon 6-0. In the other group (B) of twenty patients, the skin was closed with Steri-Strips. The Steri-Strips were laid over the surgical wounds in the group B patients. All application of sutures and Steri-Strips were performed by the same staff general ENT surgeon. The independent assessors were two specialist plastic surgeons blinded to the randomized intervention performed all patient assessment. The patients and surgeons were not blinded to the type of skin closure technique.

The wound closure time was defined as the time from when the ENT surgeons began to close the skin until finished. Following the cervical lymph

node excision, all lymph nodes were investigated for pathologic diagnosis by specialist doctors in the Pathology Department at Thammasat Chalerm Prakit Hospital, Thammasat University. All patients continued to take two grams per day of Cloxacillin for seven days. Complications such as wound infection and wound dehiscence were assessed on the first and second week postoperatively by same staff general ENT surgeon. At the twelfth postoperative week, the scars were evaluated by two specialist plastic surgeons using the Sakka's aesthetic criteria and scoring system, the score range was between 4 (high aesthetic) and 22 (low aesthetic)<sup>(12)</sup>. The assessment included width of the scar, stretch marks, redness,

**Table 1.** Baseline characteristics between studied groups

|                                      | Nylon group | Adhesive dressing group (Steri-Strips) | p-value |
|--------------------------------------|-------------|--|---------|
| Sex (person); n (%)                  |             |  | 0.082   |
| Female                               | 17 (85)     | 11 (55)                                |         |
| Male                                 | 3 (15)      | 9 (45)                                 |         |
| Age (year); mean±SD                  | 44.9±13.06  | 37.05±17.09                            | 0.111   |
| Length of wounds (cm); mean±SD       | 2.07±0.37   | 2.13±0.43                              | 0.695   |
| Skin closure time (minutes); mean±SD | 4.75±0.44   | 2.2±0.41                               | <0.001  |
| Wound complications (person)         |             |  |         |
| Wound dehiscence                     | 0           | 0                                      |         |
| Wound infection                      | 0           | 0                                      |         |

SD=standard deviation

**Table 2.** Comparison of Sakka's aesthetic score between simple interrupted non-absorbable suture (Nylon) 6-0 group and Steri-Strips (3M™ Steri-Strip) group

|   | Nylon group (n=20) |                | Adhesive dressing group (Steri-Strips) (n=20) |                | p-value |
|---|--------------------|----------------|---|----------------|---------|
|   | Score              | 95% CI         | Score   | 95% CI         |         |
| Aesthetic score at 12 <sup>th</sup> week postoperatively; mean±SD | 7.75±1.33          | 7.126 to 8.374 | 6.25±0.85                                     | 5.852 to 6.648 | <0.001  |

SD=standard deviation; CI=confidence interval

thickness, pigmentation, and puckering.

### Statistical analysis

The data were analyzed using the SPSS Statistics software, version 15.0 (SPSS Inc., Chicago, IL, USA) software. The differences in outcome were compared between the two groups using Fisher's exact test and independent sample t-test.

### Results

Forty patients, comprising of 28 females (70%) and 12 males (30%), were included in this study. The baseline characteristics are shown in Table 1. There was no significant difference between the two groups. Wound complications did not occur in any of the studied patients. The wound closure time in the Steri-Strips group was significantly shorter than in the simple interrupted non-absorbable suture group (2.2±0.41 and 4.75±0.44, respectively,  $p<0.01$ ) (Table 1).

The Sakka's aesthetic score in the simple interrupted non-absorbable suture group was significantly higher than the score in the Steri-Strips group (7.75±1.33 and 6.25±0.85, respectively,  $p<0.01$ ). Therefore, the Steri-Strips group had a better aesthetic outcome than the simple interrupted non-absorbable suture group (Table 2).

The Sakka's score at the twelfth week post-

operatively, judged by two plastic surgeons, was compared in terms of gender differences. There were no significant differences between the two genders in either the simple interrupted non-absorbable suture group or the Steri-Strips group ( $p=0.571$  and  $0.369$ , respectively) as shown in Table 3.

The pathologic diagnoses of all lymph nodes are shown in Table 4. The most common pathology test result of the simple interrupted non-absorbable suture group was tuberculosis (30%,  $n=6$ ), and of the Steri-Strips group was benign lymph node lesion (45%,  $n=9$ ).

### Discussion

Cervical lymph node excision is frequently a necessary component in diagnostic work-up and confirmation. In addition to the surgery for the lymph node excision, a cost-effective, time-efficient and easy to perform wound closure method for an optimal cosmetic result is desired.

Cosmetic results are naturally important to most patients, and all patients should be counseled on this aspect of wound healing<sup>(17)</sup>. Sutures and Steri-Strips are frequently used for skin closure in cervical lymph node excision at the Otolaryngology Department at Thammasat Chalerm Prakiat Hospital.

In the present study, the Steri-Strips group had a better aesthetic outcome than those simple interrupted

**Table 3.** Comparison of Sakka's aesthetic score in gender differences of simple interrupted non- absorbable suture (Nylon) 6-0 group and Steri-Strips (3M™ Steri-Strip) group

| Postoperative Aesthetic score at 12 <sup>th</sup> week      | Female; mean±SD |                | Male; mean±SD |                | p-value |
|---|-----------------|----------------|---------------|----------------|---------|
|   | Score           | 95% CI         | Score         | 95% CI         |         |
| Simple interrupted non- absorbable suture (Nylon) 6-0 group | (n=17)          |                | (n=3)         |                |         |
|   | 7.82±1.42       | 7.091 to 8.556 | 7.33±0.58     | 5.899 to 8.768 | 0.571   |
| Steri-Strips group  | (n=11)          |                | (n=9)         |                |         |
|   | 6.09±0.83       | 5.532 to 6.649 | 6.44±0.88     | 5.766 to 7.122 | 0.369   |

SD=standard deviation; CI=confidence interval

**Table 4.** Comparison of the lymph node pathology between simple interrupted non-absorbable suture (Nylon) 6-0 group and Steri-Strips (3M™ Steri-Strip) group

| The lymph node pathology (person) | Nylon group (n=20); n (%) | Steri-strips group (n=20); n (%) | p-value |
|-----------------------------------|---------------------------|----------------------------------|---------|
| Granulomatous disease             | 5 (25)                    | 2 (15)                           |         |
| Tuberculosis                      | 6 (30)                    | 2 (10)                           |         |
| Benign lymph node lesion          | 4 (20)                    | 9 (45)                           |         |
| Lymphoma                          | 5 (25)                    | 4 (20)                           |         |
| Metastasis carcinoma              | 0 (0)                     | 2 (10)                           |         |
| Total                             | 20 (100)                  | 20 (100)                         | 0.176   |

non-absorbable sutures (Nylon) 6-0 ( $p<0.001$ ). The findings of the present study were similar to previous studies<sup>(14,18,19)</sup>.

Some studies reported results that showed the delayed scar widening was not significantly different between sutured wounds and adhesive tapes<sup>(20-23)</sup>. The insignificant difference between the two techniques may relate to the wound locations in high movement areas such as arms and legs and long wound lengths<sup>(7,13)</sup>.

The wound closure times for the Steri-Strips group were statistically significant shorter than the simple interrupted non-absorbable suture group ( $p<0.01$ ). The closure times for small wounds were not clinically significantly shorter, but the authors expect that if a wound was large, the Steri-Strips would be both clinically and statistically significant faster than the simple interrupted non-absorbable suture. This is because the application of Steri-Strips to skin is a less complicated procedure than skin suture, consistent with other studies<sup>(18,24-27)</sup>.

Another measure of the effectiveness of a wound closure method is prevention of dehiscence. In theory, skin closure by Steri-Strips allows the skin tension to be equal throughout the length of the incision, making the closure gentler on the tissues and preventing local skin tension and necrosis. Moreover, skin closure by non-absorbable sutures can create greater tension upon the wound edges, due to either poor technique or

subsequent tissue swelling after skin closure, resulting in localized ischemia<sup>(10,28)</sup>. In the present study, there were no cases of wound dehiscence in either the Steri-Strips or the simple interrupted non-absorbable suture groups, because absorbable sutures were placed into subcutaneous tissue to eliminate dead space and lower skin tension<sup>(4,5)</sup>.

The only cause of higher incidence of wound infection in conventional skin suturing when compared to skin closure by a sutureless technique is the suture needle passing through the intact skin on either side of the wound, carrying both epidermis and organisms along its track and into the depths of the wound<sup>(10,28)</sup>. No wound infections occurred in the present study in either the Steri-Strips group or the simple interrupted non-absorbable suture (Nylon) 6-0 group, because sterile techniques were used in the operating room and all patients continued to take oral antibiotics after surgery for seven days. These findings were consistent with the previous literature<sup>(13,14,25-27)</sup>.

In conclusion, the Steri-Strips (3M™ Steri-Strip) group had better aesthetic outcomes in wounds smaller than 3 cm than the simple interrupted non-absorbable suture (Nylon) 6-0 group ( $p<0.001$ ). The authors conclude that adhesive wound closure strips are effective alternative to sutures in the closure of cervical lymph node biopsy wounds.

## What is already known on this topic?

The cosmetic outcome of skin closure utilizing Steri-Strips seemed to be as good as suture. There is no literature that compares cosmetic outcome of skin closure methods in cervical lymph node excision.

## What this study adds?

The skin closure with Steri-Strips gave better aesthetic outcomes compared to the 6-0 Nylon sutures in wounds smaller than 3 cm.

In the future, the patients may be able to remove Steri-Strips by themselves and Steri-Strips utilizing may represent cost and time saving to the health care system and patients.

## Acknowledgement

The authors thank Dr. Ruthairat Suphareok-thaweechai and Dr. Praopilas Phakdeedindan for their valuable statistical advice, and Mr. Michael Jan Everts for manuscript editing.

## Conflicts of interest

All authors report no conflicts of interest relevant to this article.

## References

1. Son D, Harijan A. Overview of surgical scar prevention and management. *J Korean Med Sci* 2014;29:751-7.
2. Jefferson GD. Chapter 6: Dynamic wound healing. In: Johnson JT, Rosen CA, editors. *Bailey's head & neck surgery otolaryngology*. Philadelphia: Williams & Wilkins / Wolters Kluwer Business; 2014. p. 75-85.
3. Alam M, Posten W, Martini MC, Wrone DA, Rademaker AW. Aesthetic and functional efficacy of subcuticular running epidermal closures of the trunk and extremity: a rater-blinded randomized control trial. *Arch Dermatol* 2006;142:1272-8.
4. Singer AJ, Hollander JE, Quinn JV. Evaluation and management of traumatic lacerations. *N Engl J Med* 1997;337:1142-8.
5. Al-Mubarak L, Al-Haddab M. Cutaneous wound closure materials: an overview and update. *J Cutan Aesthet Surg* 2013;6:178-88.
6. Krishnamoorthy B, Najam O, Khan UA, Waterworth P, Fildes JE, Yonan N. Randomized prospective study comparing conventional subcuticular skin closure with Dermabond skin glue after saphenous vein harvesting. *Ann Thorac Surg* 2009;88:1445-9.
7. Parell GJ, Becker GD. Comparison of absorbable with nonabsorbable sutures in closure of facial skin wounds. *Arch Facial Plast Surg* 2003;5:488-90.
8. Gillman T. Healing of cutaneous abrasions and of incisions. *Med Pract* 1956;4:751-65.
9. Katz KH, Desciak EB, Maloney ME. The optimal application of surgical adhesive tape strips. *Dermatol Surg* 1999;25:686-8.
10. Kolt JD. Use of adhesive surgical tape with the absorbable continuous subcuticular suture. *ANZ J Surg* 2003;73:626-9.
11. Forrester JC, Zederfeldt BH, Hayes TL, Hunt TK. Tape-closed and sutured wounds: a comparison by tensiometry and scanning electron microscopy. *Br J Surg* 1970;57:729-37.
12. Sakka SA, Graham K, Abdulah A. Skin closure in hip surgery: subcuticular versus transdermal. A prospective randomized study. *Acta Orthop Belg* 1995;61:331-6.
13. Esmailian M, Azizkhani R, Jangjoo A, Nasr M, Nemati S. Comparison of wound tape and suture wounds on traumatic wounds' scar. *Adv Biomed Res* 2018;7:49.
14. Kuo F, Lee D, Rogers GS. Prospective, randomized, blinded study of a new wound closure film versus cutaneous suture for surgical wound closure. *Dermatol Surg* 2006;32:676-81.
15. Javadi SMR, Kasraianfard A, Ghaderzadeh P, Khorshidi HR, Moein A, Makarchian HR, et al. Comparison of subcuticular and interrupted suturing methods for skin closure after appendectomy: A randomized controlled trial *Iran Red Crescent Med J* 2018;20:4.
16. Rosner B. Chapter 8: Hypothesis testing: two-sample inference. In: Rosner B, editor. *Fundamentals of biostatistics*. 8th ed. Boston, MA: Cengage Learning; 2016. p. 308-37.
17. Quinn JV, Polevoi SK, Kohn MA. Traumatic lacerations: what are the risks for infection and has the "golden period" of laceration care disappeared? *Emerg Med J* 2014;31:96-100.
18. Lazar HL, McCann J, Fitzgerald CA, Cabral HJ. Adhesive strips versus subcuticular suture for mediansternotomy wound closure. *J Card Surg* 2011;26:344-7.
19. Gkegkes ID, Mavros MN, Alexiou VG, Peppas G, Athanasiou S, Falagas ME. Adhesive strips for the closure of surgical incisional sites: a systematic review and meta-analysis. *Surg Innov* 2012;19:145-55.
20. Toriumi DM, O'Grady K, Desai D, Bagal A. Use of octyl-2-cyanoacrylate for skin closure in facial plastic surgery. *Plast Reconstr Surg* 1998;102:2209-19.
21. Rothnie NG, Taylor GW. Sutureless skin closure. A clinical trial. *Br Med J* 1963;2:1027-30.
22. Kochar MP, Singh SP. Incised surgical wound closure with sutures and staples: a controlled experimental study. *Int Surg J* 2016;2:369-72.
23. Abdus-Salam RA, Bello FA, Olayemi O. A randomized study comparing Skin staples with subcuticular sutures for wound closure at caesarean section in black-skinned women. *Int Sch Res Notices* 2014;2014:807937.
24. Lazar HL, McCann J, Fitzgerald CA, Thompson J, Bao Y, Cabral HJ. Novel adhesive skin closures improve wound healing following saphenous vein harvesting. *J Card Surg* 2008;23:152-5.
25. Harold KL, Goldstein SL, Nelms CD, Matthews BD,

- Sing RF, Kercher KW, et al. Optimal closure method of five-millimeter trocar sites. *Am J Surg* 2004;187:24-7.
26. Kerrigan CL, Homa K. Evaluation of a new wound closure device for linear surgical incisions: 3M Steri-Strip S Surgical Skin Closure versus subcuticular closure. *Plast Reconstr Surg* 2010;125:186-94.
27. Zempsky WT, Zehrer CL, Lyle CT, Hedbloom EC. Economic comparison of methods of wound closure: wound closure strips vs. sutures and wound adhesives. *Int Wound J* 2005;2:272-81.
28. Eaton AC. A controlled trial to evaluate and compare a sutureless skin closure technique (Op-Site skin closure) with conventional skin suturing and clipping in abdominal surgery. *Br J Surg* 1980;67:857-60.