

Ultrasound in Pediatric Patients with Clinically First Joint Pain

Jaovisidha S, MD¹, Chunharas R, MD¹, Woratanarat P, MD, PhD², Vilaiyuk S, MD³, Chitrapazt N, MD¹

¹ Division of Diagnostic Radiology, Department of Diagnostic and Therapeutic Radiology, Faculty of Medicine Ramathibodi Hospital, Mahidol University, Bangkok, Thailand

² Division of Pediatric Orthopedic, Department of Orthopedics, Faculty of Medicine Ramathibodi Hospital, Mahidol University, Bangkok, Thailand

³ Division of Rheumatology, Department of Pediatrics, Faculty of Medicine Ramathibodi Hospital, Mahidol University, Bangkok, Thailand

Background: Joint pain in children is a presentation of important differential diagnoses including juvenile idiopathic arthritis (JIA) and septic arthritis, which can cause permanent joint destruction. In children, un-cooperativeness and thick subcutaneous fat may limit evaluation of joint inflammation.

Objective: To evaluate association of physical examination and ultrasound findings in pediatric patients with clinically first joint pain and association of ultrasound findings and final diagnosis.

Materials and Methods: Children (16 years old or younger) with clinically first joint pain but equivocal clinical diagnosis were eligible if they were sent for ultrasound of the joint. Images were reviewed by two investigators using consensus agreement. The ultrasound findings were assessed for joint effusion, synovial thickening, synovial hyperemia, peri-articular soft tissue swelling, and bone erosion. Clinical examination and final diagnosis were reviewed from medical record. Patients with incomplete clinical data and those with underlying disease of hemophilia were excluded.

Results: The retrospective study consisted of 50 patients (87 joints). Most common ultrasound abnormality was joint effusion in 19 of 87 (21.8%) joints. There was significant association between ultrasound findings and physical examination ($p < 0.001$). Ultrasound detected abnormal findings in two of 30 joints, which were not detected on physical examination. Provisional diagnoses were septic arthritis (44%) and acute inflammatory arthritis (26%). Only eight patients (16%) were sent under clinical suspicion of JIA. Thirty-three patients had diagnoses changed after ultrasound. At the final diagnosis, only one patient (2%) was diagnosed as septic arthritis and 17 patients (34%) as JIA. Most common diagnosis associated with synovial thickening and synovial hyperemia was JIA [in 10 of 15 (66.7%) and six of eight (75%) of cases, respectively]. Negative ultrasound finding was found in cases clinically suspected of neoplasm.

Conclusion: Ultrasound in pediatric patients with clinically first joint pain showed significant correlation with physical examination. In some cases, ultrasound can contribute positive findings even when physical sign is not present. Synovial thickening, synovial hyperemia, peri-articular soft tissue swelling, and negative finding by ultrasound showed significant correlation with final diagnoses. The findings of synovial thickening and synovial hyperemia frequently associated with JIA.

Keywords: Pediatric, Joint pain, Ultrasound, Juvenile idiopathic arthritis

J Med Assoc Thai 2019;102(10):1046-52

Website: <http://www.jmatonline.com>

Received 25 Apr 2018 | Revised 2 Jan 2019 | Accepted 3 Jan 2019

Joint pain in children is a presentation of many diseases. Important differential diagnoses include juvenile idiopathic arthritis (JIA) and septic arthritis,

which can cause disability from permanent joint destruction⁽¹⁻³⁾.

Juvenile idiopathic arthritis (JIA) is the most common rheumatic disease in children^(1,4,5). The prevalence in developed countries is 16 to 150 per 100,000⁽¹⁾. The term JIA encompasses all forms of arthritis that presents before 16 years of age, persists for at least six weeks, and excludes other causes (e.g., septic arthritis, inflammatory bowel disease, systemic lupus erythematosus, transient synovitis, or traumatic

Correspondence to:

Jaovisidha S.

Department of Diagnostic and Therapeutic Radiology, Ramathibodi Hospital, Mahidol University, Rama VI Road, Bangkok 10400, Thailand.

Phone: +66-2-2011212

Email: rasjv@yahoo.com

How to cite this article: Jaovisidha S, Chunharas R, Woratanarat P, Vilaiyuk S, Chitrapazt N. Ultrasound in Pediatric Patients with Clinically First Joint Pain. J Med Assoc Thai 2019;102:1046-52.

injury)⁽¹⁾. Typical signs and symptoms include joint tenderness and warmth, limited range of motion, and joint swelling. Joint swelling is gold standard to detect joint inflammation⁽⁶⁾. However, in children, uncooperativeness and thick subcutaneous fat may limit evaluation of joint swelling by physical examination.

In JIA and other inflammatory arthritis, synovial edema, folding, and villous formation results in increased synovial tissue mass⁽⁷⁾. The ultrasound can detect various degree of synovitis, which is not determined by clinical examination⁽⁸⁻¹⁰⁾. According to Vilaiyuk et al, systemic JIA (SJIA) in Ramathibodi Hospital had highest remission rate owing to early diagnosis and prompt treatment compared to other categories⁽¹¹⁾. Plain radiographic findings such as narrowed joint space, bone erosion, and growth disturbance are irreversible in late of the disease⁽¹²⁾.

Role of ultrasound is to detect reversible process of disease such as synovitis, and to estimate severity of joint disease. Grey-scale ultrasound can assess joint fluid and synovial thickness. Doppler ultrasound can assess synovial hyperemia to determine disease activity⁽⁶⁾. Both ultrasound and magnetic resonance imaging (MRI) can be used to evaluate inflammatory and destructive changes⁽¹²⁾. However, ultrasound has more benefit as a quick and inexpensive tool with no need for sedation, and no risk of complication and radiation⁽¹³⁾. Some investigator proposed that ultrasound may be more accurate than clinical examination to detect synovitis⁽⁸⁻¹⁰⁾.

The present study was conducted to evaluate association of ultrasound findings and physical examination in pediatric patients with the first joint pain, and to evaluate association of ultrasound findings and the final diagnosis.

Materials and Methods

Study design and population

The present study was a retrospective study and was approved by the Institutional Review Board (IRB). The investigators reviewed ultrasound studies of the joint from the Picture Archive and Communication System (PACS) performed in patient 16 years old or younger in the Department of Radiology, Ramathibodi Hospital to include eligible patients for analyses.

The inclusion criteria consisted of the patients with a) clinically first joint pain, b) normal or equivocal physical examination and laboratory investigation, and c) that underwent first ultrasound of the joint between January 2010 and May 2016. If the patient had more than one examination during this period, the analysis was done for the first examination

of each joint.

If the medical records for follow-up visit after ultrasound were not available for review, the investigator would contact the patients by telephone.

The exclusion criteria were the patients with a) underlying disease of hemophilia, and b) medical records for follow-up visit after ultrasound were not available for review, and whom the investigator could not contact by telephone.

Data collection

Baseline demographic data including age, sex, underlying disease, presenting symptoms, and joints involved were retrieved from medical records. Clinical diagnoses were categorized into 1) septic arthritis, 2) JIA, 3) acute inflammatory arthritis including reactive arthritis, transient synovitis of the hip, and unspecified arthritis resolving within four weeks, 4) non-inflammatory musculoskeletal diseases including patellofemoral (PF) joint syndrome and avascular necrosis (AVN), 5) peri-articular infection, 6) neoplastic diseases, 7) other systemic diseases with articular manifestation such as acute rheumatic fever, hyper-IgD syndrome, and Behçet disease, and 8) acute disseminated encephalomyelitis (ADEM).

Management by physician classified as operative management (arthrotomy and surgical debridement) and non-operative management (DMARDs, NSAIDs, prednisolone, antibiotics, chemotherapy, analgesics, or immobilization) was also reviewed in the next follow-up visits.

Final diagnoses were recorded based on clinical data, laboratory findings, or pathologic findings if available.

Radiologic assessment

Either radiology staff or radiology residents (under supervision) performed the ultrasound. The model of ultrasound machines used was Philips iU22 scanner (Philips, Amsterdam, The Netherlands). The transducers used were high-frequency (9-3 or 12-5 MHz) linear array or low-frequency (5-3 or 8-5 MHz) curvilinear array transducers.

Ultrasound results were collected from the official reports and the images were reviewed by two investigators with three and 15 years' experience, blinded to the clinical information, and using consensus agreement. Data were analyzed separately for each joint in the same patient. The ultrasound findings assessed were joint effusion, synovial thickening, synovial hyperemia, bone erosion, and soft tissue swelling.

Table 1. Patients' characteristics

Patient's characteristics	Summary (n=50) n (%)
Sex: male	36 (72)
Age (years), Mean±SD	6.40±4.65
Underlying disease	
Allergic diseases	9 (18)
Hematologic disease	4 (8)
Systemic disease	3 (6)
Solid Neoplasm	1 (2)
Physical examination	
Limited range of motion	31 (62)
Joint swelling	19 (38)
Joint redness	12 (24)
Acute fever	10 (20)
Prolonged fever	7 (14)
Number of joint involvement	
Monoarthritis (1 joint)	29 (58)
Oligoarthritis (2 to 4 joints)	16 (32)
Polyarthritis ≥5 joints	5 (10)
Pain duration (day), Median (IQR)	21.5 (35)
Provisional diagnosis	
Septic arthritis	22 (44)
Acute inflammatory arthritis [†]	13 (26)
JIA	8 (16)
Non-inflammatory musculoskeletal diseases [‡]	7 (14)
Prior treatment	
NSAIDs	23 (46)
None	16 (32)
Antibiotics	15 (30)
DMARDs [‡]	1 (2)
Immobilization ^b	1 (2)

SD=standard deviation; IQR=interquartile range; JIA=juvenile idiopathic arthritis; NSAIDs=non-steroidal anti-inflammatory drugs; DMARDs=disease-modifying antirheumatic drugs

[†] Including reactive arthritis, transient synovitis of hip and unspecified arthritis resolving within 4 weeks

[‡] Including patellofemoral (PF) joint syndrome, avascular necrosis, muscle strain, and hypermobility syndrome

^a Suspected Behçet disease, ^b Suspected reactive arthritis

Statistical analysis

The data were analyzed by descriptive study for the patient's characteristics such as sex, age, pain duration (day), number of tender joint, joint

Table 2. Ultrasound features

Ultrasound features	Total joint assessed (n=87) n (%)
Location	
Hip	33 (37.9)
Knee	32 (36.8)
Ankle	12 (13.8)
Wrist	4 (4.6)
Elbow	4 (4.6)
Shoulder	2 (2.3)
Ultrasound findings	
Negative	55 (63.2)
Joint effusion	19 (21.8)
Synovial thickening	17 (19.5)
Soft tissue swelling	9 (10.3)
Hyperemia	8 (9.2)
Bone erosion	2 (2.3)

location, clinical presentation, clinical examination, and laboratory findings, and Fisher's exact test for the association between physical examination and ultrasound findings and between ultrasound findings and final diagnosis, with a p-value of less than 0.05 being considered statistically significant.

The authors used Stata v.14 statistical software (Stata Corporation, College Station, TX) and SPSS® 23.0.0.0 (IBM Corporation, New York, NY) for statistical analysis.

Results

Fifty-four patients were included according to the inclusion criteria. Subsequently four patients were excluded due to incomplete data, thus resulting in 50 patients (87 joints) for evaluation. The patients' characteristics are shown in Table 1. The mean age was 6.4 years old. The most common presenting symptom was limited range of motion (31 out of 50 cases, 62%), monoarthritis in 29 of 50 cases (58%), and polyarthritis in five out of 50 cases (10%). The onset of symptoms varied from one day to the maximum of 1,095 days to the first ultrasound study.

Provisional diagnoses before ultrasound study mostly were septic arthritis (44%), followed by acute inflammatory arthritis (20%). Only eight patients (16%) were sent to ultrasound with clinical suspicion of JIA. Treatment before ultrasound is shown in Table 1 (some patients had systemic diseases treated for a long time but recently developed the

Table 3. Comparison of provisional and final diagnosis

	n=50 n (%)
Provisional diagnosis	
Septic arthritis	22 (44)
Acute inflammatory arthritis [†]	13 (26)
JIA	8 (16)
Non-inflammatory musculoskeletal diseases ^Δ	7 (14)
Diagnosis change	
Yes	33 (66)
No	17 (34)
Final clinical diagnosis	
JIA	17 (34)
Acute inflammatory arthritis [†]	10 (20)
Peri-articular infection	8 (16)
Non-inflammatory musculoskeletal diseases ^Δ	7 (14)
Systemic disease with articular manifestation [‡]	4 (8)
Neoplastic disease	2 (4)
Septic arthritis	1 (2)
Other (ADEM)	1 (2)

JIA=juvenile idiopathic arthritis; ADEM=acute disseminated encephalomyelitis

[†] Including reactive arthritis, transient synovitis of hip and unspecified arthritis resolving within 4 weeks

^Δ Including patellofemoral (PF) joint syndrome, avascular necrosis, muscle strain, and hypermobility syndrome

[‡] Including acute rheumatic fever, hyper-IgD syndrome, and Behçet disease

Table 4. Association between ultrasound findings and physical examination*

	Physical examination		Total
	Negative	Positive [†]	
Negative US	28	27	55
Positive US	2	30	32
Total	30	57	87

US=ultrasound

* Fisher's exact test, p<0.001

[†] Including joint swelling, joint redness and limited range of motion

first episode of joint pain). The hip and the knee were the most common joints involved (33 and 32 joints, respectively). Ultrasound findings are shown in Table 2. After ultrasound, 33 patients (66%) had

the diagnoses changed. At the final diagnosis, only one patient (2% of cases) was diagnosed as septic arthritis and 17 patients (34% of case) were diagnosed as JIA (Table 3). There was significant association between ultrasound findings and physical examination (p<0.001) (Table 4). When comparing ultrasound findings with final diagnoses (Table 5), the one patient finally diagnosed as septic arthritis (Figure 1) showed multiple ultrasound findings suggestive of articular inflammation such as joint effusion, synovial thickening, synovial hyperemia, and peri-articular soft tissue swelling, which was later confirmed by MRI to have septic arthritis with osteomyelitis of the right hip. The most common finding in JIA was synovial thickening (in 10 of 17 cases, 58.8%) (Figure 2). On the other hand, the most common diagnosis associated with synovial thickening and synovial hyperemia was JIA (in 10 of 15 and six out of eight cases, respectively), while seven out of nine cases with ultrasound findings of peri-articular soft tissue swelling were due to peri-articular infection.

Discussion

In pediatric patients with inflammatory joint disease, assessing physical signs is often difficult. Some authors proposed that ultrasound can detect various degree of synovitis, which is not defined by clinical examination⁽⁸⁻¹⁰⁾. In the present study, there was statistically significant association between physical examination and ultrasound finding. However, two out of 30 joints (6.7%) without swelling, erythema, or limited range of motion had joint effusion. This may reflect the advantage of ultrasound in detecting joint effusion in spite of negative physical examination or reflecting the clinician's good performance in maintaining clinical suspicion despite the absence of positive physical sign. Ultrasound can support the clinicians even when physical sign is not present. Ultrasound can be an adjunctive tool to confirm the physical assessment and aids the clinician to make decision before considering invasive procedure such as arthrocentesis.

In the present study, presence of synovial thickening showed significant association with final diagnoses (p=0.025), and JIA had the highest frequency. The differential diagnosis of synovial thickening should include JIA, acute inflammatory arthritis, and septic arthritis. Synovial hyperemia also shows significant association with final diagnosis (p=0.036) mostly appeared in JIA along with septic arthritis. These two entities, therefore, should be included in the possible causes of symptoms. Soft

Table 5. Association between ultrasound findings and final diagnosis

Ultrasound findings	Final diagnosis, n (%)								p-value [#]
	JIA (n=17)	Acute inflammatory arthritis [†] (n=10)	Peri-articular infection (n=8)	Non-inflammatory disease [‡] (n=7)	Systemic disease [‡] (n=4)	Neoplasm (n=2)	Septic arthritis (n=1)	ADEM (n=1)	
Effusion	9 (52.9)	3 (30.0)	1 (12.5)	1 (14.3)	2 (50.0)	0 (0.0)	1 (100)	1 (100)	0.142
Synovial thickening	10 (58.8)	2 (20.0)	1 (12.5)	0 (0.0)	1 (25.0)	0 (0.0)	1 (100)	0 (0.0)	0.025*
Synovial hyperemia	6 (35.3)	0 (0.0)	0 (0.0)	0 (0.0)	1 (25.0)	0 (0.0)	1 (100)	0 (0.0)	0.036*
Bone erosion	0 (0.0)	0 (0.0)	0 (0.0)	1 (14.3)	0 (0.0)	0 (0.0)	0 (0.0)	0 (0.0)	0.300
Peri-articular soft tissue swelling	1 (5.9)	0 (0.0)	7 (87.5)	0 (0.0)	0 (0.0)	0 (0.0)	1 (100)	0 (0.0)	<0.001*
Negative finding	5 (29.4)	7 (70.0)	1 (12.5)	5 (71.4)	2 (50.0)	2 (100)	0 (0.0)	0 (0.0)	0.032*

JIA=juvenile idiopathic arthritis; ADEM=acute disseminated encephalomyelitis

[†] Including reactive arthritis, transient synovitis of hip and unspecified arthritis resolving within 4 weeks

[‡] Including patellofemoral (PF) joint syndrome, avascular necrosis, muscle strain, and hypermobility syndrome

[#] Including acute rheumatic fever, hyper-IgD syndrome, and Behçet disease

[#] p-value from Fisher's exact test, * Significant p<0.05

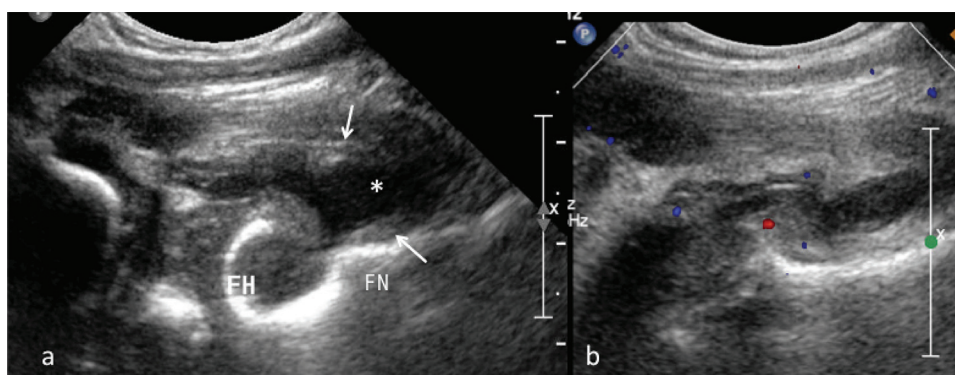


Figure 1. Septic arthritis in a 7-month-old boy with a 1-month history of limit range of motion of the right hip and fever. (a) Longitudinal US scan using curvilinear transducer over the anterior aspect of the right hip shows thickening of the hyperechoic synovial tissue (arrow) and joint effusion (*) anterior to the right femoral head (FH) and neck (FN). (b) Color doppler image shows mild-degree synovial hyperemia. The diagnosis was confirmed by arthroscopy.

tissue swelling shows significant association with final diagnosis ($p<0.001$) with peri-articular soft tissue infection posed the highest frequency, followed by JIA and septic arthritis. This helps addressing peri-articular soft tissue infection as the first consideration when peri-articular soft tissue swelling detected in ultrasound. Negative ultrasound finding also showed significant association with multiple final diagnoses ($p=0.032$) and was able to exclude septic arthritis and ADEM. However, only one patient had such entities. Noteworthy, five out of 17 cases of JIA (29.4%) showed negative ultrasound finding in spite of clinically suspicious.

Two out of 50 patients in the present study were finally diagnosed as neoplastic diseases (one was neuroblastoma with bone metastasis, and another was neurogenic tumor). Both patients showed negative ultrasound finding and no sign of joint inflammation despite significant joint pain. In acute inflammatory arthritis group, seven out of 10 cases (70%) showed negative ultrasound finding. One reason may be because four of seven received NSAIDs as empirical treatment before ultrasound was performed.

Thirty-three of 50 cases (66%) had their diagnoses changed after ultrasound. However, additional clinical and laboratory data other than ultrasound findings may

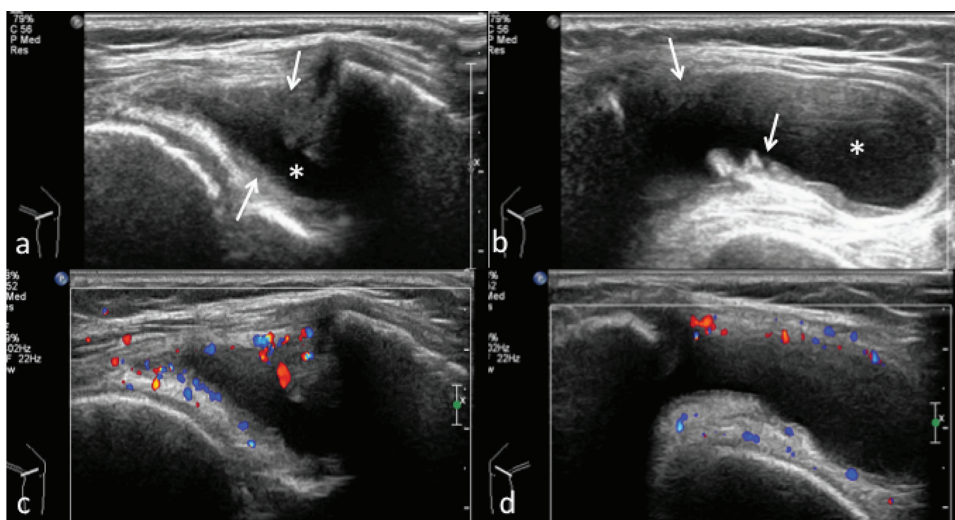


Figure 2. Oligoarthritis-type JIA in a 9-year-old girl with a 2-week history of left knee pain and swelling. Transverse US images of left knee at the medial recess (a) and lateral recess (b) show thickening of hyperechoic synovial tissue (arrows) and large amount of hypoechoic joint effusion (*). (c, d) Color Doppler images show moderate-degree synovial hyperemia. The symptoms responded to intra-articular steroid and medical therapy.

play certain roles in the changing of final diagnoses.

There was limitation when comparing the present study to the previous studies as previous studies evaluated the more specific diseases. However, while previous studies mentioned that ultrasound was more sensitive than physical examination, the present study is different since the authors found that ultrasound correlated with physical examination (in other words, ultrasound was not more sensitive than physical examination). This may be because the present study was a routine-to-research type and was a retrospective study. Some patients received empirical treatment before the ultrasound was performed and resulted in negative ultrasound despite positive clinical examination at the beginning. In addition, the time interval between physical examination and the ultrasound can result in less ultrasound findings compared to the clinical signs and symptoms at presentation.

There are certain limitations in the present study. First, the sample size is rather small, although the recruiting time was six years and five months, and all pediatric patients with clinically first joint pain that undergone ultrasound were included. Second, the present study is not disease specific. The authors studied all cases that got along with the inclusion criteria.

Conclusion

In this routine-to-research study of pediatric

patients with clinically first joint pain, physical examination showed significant association with ultrasound findings. In some cases, ultrasound can provide information to treating clinician despite negative physical examination. Certain ultrasound findings such as synovial thickening, synovial hyperemia, peri-articular soft swelling, and negative finding, showed significant association with the final diagnoses. Synovial thickening and synovial hyperemia had association with JIA.

What is already known on this topic?

It has been known that ultrasound is more sensitive than physical examination, but ultrasound is not specific for the arthritic disease in children.

What this study adds?

This study added information that ultrasound showed significant correlation with physical examination as this study is a routine-to-research-type study. This is because the patients may receive empirical treatment before ultrasound, and the time interval between physical examination and the ultrasound may be longer than in previous studies, which every step was planned for research purpose.

Besides the information above, this study added that certain ultrasound findings such as synovial thickening, synovial hyperemia, peri-articular soft swelling, and negative finding, have significant association with the final diagnoses. Synovial

thickening and synovial hyperemia had association with JIA.

Conflicts of interest

The authors declare no conflict of interest.

References

1. Damasio MB, Malattia C, Martini A, Toma P. Synovial and inflammatory diseases in childhood: role of new imaging modalities in the assessment of patients with juvenile idiopathic arthritis. *Pediatr Radiol* 2010;40: 985-98.
2. Zamzam MM. The role of ultrasound in differentiating septic arthritis from transient synovitis of the hip in children. *J Pediatr Orthop B* 2006;15:418-22.
3. Ravelli A, Martini A. Juvenile idiopathic arthritis. *Lancet* 2007;369:767-78.
4. Palman J, Shoop-Worrall S, Hyrich K, McDonagh JE. Update on the epidemiology, risk factors and disease outcomes of Juvenile idiopathic arthritis. *Best Pract Res Clin Rheumatol* 2018;32:206-22.
5. Barut K, Adrovic A, Şahin S, Kasapçopur O. Juvenile idiopathic arthritis. *Balkan Med J* 2017;34:90-101.
6. Ramos PC, Ceccarelli F, Jousse-Joulin S. Role of ultrasound in the assessment of juvenile idiopathic arthritis. *Rheumatology (Oxford)* 2012;51 Suppl 7: vii10-2.
7. Tok F, Demirkaya E, Ozcakar L. Musculoskeletal ultrasound in pediatric rheumatology. *Pediatr Rheumatol Online J* 2011;9:25.
8. Kane D, Balint PV, Sturrock RD. Ultrasonography is superior to clinical examination in the detection and localization of knee joint effusion in rheumatoid arthritis. *J Rheumatol* 2003;30:966-71.
9. Haslam KE, McCann LJ, Wyatt S, Wakefield RJ. The detection of subclinical synovitis by ultrasound in oligoarticular juvenile idiopathic arthritis: a pilot study. *Rheumatology (Oxford)* 2010;49:123-7.
10. Magni-Manzoni S, Epis O, Ravelli A, Klersy C, Veisconti C, Lanni S, et al. Comparison of clinical versus ultrasound-determined synovitis in juvenile idiopathic arthritis. *Arthritis Rheum* 2009;61:1497-504.
11. Vilaiyuk S, Soponkanaporn S, Jaovisidha S, Benjaponpitak S, Manuyakorn W. A retrospective study on 158 Thai patients with juvenile idiopathic arthritis followed in a single center over a 15-year period. *Int J Rheum Dis* 2016;19:1342-50.
12. Sheybani EF, Khanna G, White AJ, Demertzis JL. Imaging of juvenile idiopathic arthritis: a multimodality approach. *Radiographics* 2013;33:1253-73.
13. Rebollo-Polo M, Koujok K, Weisser C, Jurencak R, Bruns A, Roth J. Ultrasound findings on patients with juvenile idiopathic arthritis in clinical remission. *Arthritis Care Res (Hoboken)* 2011;63:1013-9.