

# Comparison of Sagittal Balance between Radiofrequency Targeted Vertebral Augmentation and Balloon Kyphoplasty in Treatment of Vertebral Compression Fracture: A Retrospective Study

Werasak Sutipornpalangkul PhD, MD\*, Lester Zambrana BSc\*\*,  
Arianna Gianakos BSc\*\*, Joseph M Lane MD\*\*

\* Department of Orthopaedic Surgery, Faculty of Medicine Siriraj Hospital, Mahidol University, Bangkok, Thailand

\*\* Hospital for Special Surgery, Weill Cornell Medical College New York, NY, USA

---

**Objective:** To compare the effectiveness of high viscosity cement radiofrequency targeted vertebral augmentation (RF-TVA) and balloon kyphoplasty on spinal sagittal balance through radiologic evaluation.

**Material and Method:** The present retrospective study included patients whom underwent either balloon kyphoplasty utilizing the Kyphon system or RF-TVA utilizing the DFine system between 2007 and 2014. Medical record reviews included demographic data and radiographic findings including pre- and post-operative lateral radiographs of the whole spine and post-operative computerized topography. All spinal sagittal alignment parameters such as pelvic incidence (PI), sacral slope (SS), pelvic tilt (PT), lumbar lordosis (LL), sagittal vertical axis (SVA), and spinosacral angle (SSA) were measured and evaluated.

**Results:** Thirty-three vertebral compression fracture (VCF) patients were included in the present study. Sixteen of them underwent RF-TVA and 17 underwent balloon kyphoplasty. There were no significant differences in age, gender, and pre-operative spinal sagittal alignment parameters between these two groups of patients. In the RF-TVA group, there were no significant differences in percent of vertebral collapse and kyphotic angle between pre- and post-operative radiographs. In the balloon kyphoplasty group, there were significant improvement in both percent of vertebral collapse and kyphotic angle. The balloon kyphoplasty group also showed a statistically significant change in pelvic tilt ( $p = 0.02$ ). Neither group demonstrated statistically significant changes in any other spinal sagittal alignment parameters ( $p > 0.05$ ).

**Conclusion:** The RF-TVA and balloon kyphoplasty did not play a role in improving the whole spine alignment in the treatment of VCF. However, balloon kyphoplasty did demonstrate regional improvement of the VCF.

**Keywords:** Kyphoplasty, Sagittal balance, Osteoporosis, Vertebral compression fracture

*J Med Assoc Thai* 2016; 99 (9): 1025-32

Full text. e-Journal: <http://www.jmatonline.com>

---

Osteoporosis is a common disease that affects a large population with devastating impacts on patient morbidity and mortality, as well as on socioeconomic costs<sup>(1)</sup>. Osteoporosis compression fractures of the spine also result in significant morbidity and mortality leading to increase back pain and irreversible spinal deformity, usually resulting in kyphosis<sup>(2)</sup>. These abnormalities in spine result in significant health consequences<sup>(3)</sup>.

Based on the current literature, kyphoplasty is useful not only for greater pain relief, functional recovery, and health-related quality of life, but also for

restoring the height of the compression vertebra<sup>(4)</sup>. Recently, Yokoyama et al<sup>(5)</sup> showed that the balloon kyphoplasty not only played a role in the restoration of height of the collapsed vertebra but also improved whole spine sagittal imbalance. Whole spine sagittal balance has been recognized as one of the most important parameters in determining the clinical outcomes of therapeutic intervention on the spine<sup>(6)</sup>. Radiofrequency Targeted ventral augmentation (RF-TVA), which is a novel minimally invasive method, has been proven as an effective technique in the treatment of patients with painful vertebral compression fractures (VCFs)<sup>(7-9)</sup>. The RF-TVA technique allows for an interval balloon to be formed in the vertebra utilizing ultra-high viscosity cement. In contrast, balloon kyphoplasty requires the formation of a temporary cavity utilizing a high pressure balloon for the cement to be quickly delivered into. No

**Correspondence to:**

Sutipornpalangkul W, Department of Orthopaedic Surgery, Faculty of Medicine Siriraj Hospital, Mahidol University, Prannok Road, Bangkoknoi, Bangkok 10700, Thailand.

Phone: +66-81-7512428, Fax: +66-2-4128172

E-mail: [werasak.sut@mahidol.ac.th](mailto:werasak.sut@mahidol.ac.th)

studies have investigated the role of RF-TVA on spinal sagittal alignment. Therefore, the present study aimed to investigate the role of RF-TVA on spinal sagittal alignment. We hypothesize the high viscosity cement RF-TVA will be as effective as balloon kyphoplasty at improving whole spine sagittal balance.

### **Material and Method**

The retrospective chart reviews and image reviews were conducted at Hospital for Special Surgery (HSS) in New York City from 2007 to 2014. Thirty-three patients who had a single painful VCF (pain score on a visual analog scale of five or higher), treated with either RF-TVA utilizing the Dfine system or balloon kyphoplasty utilizing the Kyphon system, and had completed pre- and post-operative lateral radiography of whole spine were included in the present study. All patients had been confirmed by biopsy results as osteoporosis VCF, not pathological fracture. All compression fracture vertebrae showed a high signal intensity on short T1 inversion recovery magnetic resonance (MR) imaging and a low signal intensity on T1-weighted MR imaging. A single senior orthopedic surgeon (Lane JM) operated on all patients. The present study was reviewed and approved by the HSS Ethics Committee.

After enrollment, each patient's medical history was reviewed and demographic data, surgical history, and radiographic findings including plain radiography, computerized tomography, MR imaging were recorded.

### **Surgical techniques**

Under general anesthesia, the patient was positioned prone on a radiolucent table. Antero-posterior and lateral views were arranged by the surgeon using fluoroscopy until excellent images of the compression fracture vertebral body were achieved. The patient was prepped and draped in the routine sterile manner. A pedicle of compression fracture vertebra was identified, and a Jamshidi needle (CareFusion Corporation, San Diego, CA, USA) was placed through the pedicle into the vertebral body. The compression fracture vertebra was needle biopsied via vertebral pedicle, before doing kyphoplasty, to exclude cases with malignancies. For the RF-TVA group, a RF-TVA cavity forming osteotome (VertecoR® Midline Osteotome; RF-TVA Inc., San Jose, CA, USA) was then placed in crossing the midline. Approximately 3-4 ml of RF-TVA heated bone cement (StabiliT® ER2; RF-TVA Inc., San Jose, CA, USA), which is ultra-high

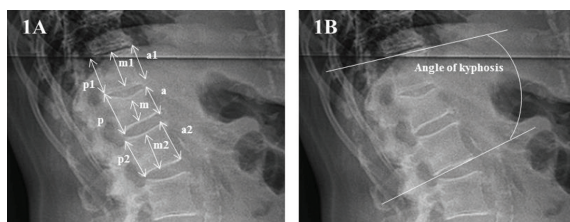
viscosity cement, was delivered into vertebral body. For the balloon kyphoplasty, Kyphon® balloons (Medtronic Inc. Minneapolis, MN, USA) were inserted and inflated to create a space leading to excellent restoration of compression vertebral body. A 5-7 ml of cement was then inserted using Stryker cement (Stryker Corporation, Michigan, USA) into the vertebral body. Continuous fluoroscopic monitoring was performed in both antero-posterior and lateral views during bone cement injection. After finishing bone cement injection, the needle was withdrawn and the surgical wound was closed in the standard fashion. Patients were able to ambulate post-operatively and were discharged in the same day of surgery.

### **Radiographic parameters measurement**

The standing lateral radiographs included the whole spine and both hip joints with hips and knees fully extended. Radiographs were used for analysis both before and after treatment. All parameters were measured on the lateral whole spine standing radiographs a few days before and one week after surgery. All radiographic parameters such as local height and sagittal spinal alignment were measured using an image viewer computer system Sectra IDS7 version 15.1.28.6 (Sectra AB, Sweden). Restoration of vertebral height in anterior, middle, and posterior portion of compression vertebra was calculated as described by Falco et al<sup>(10)</sup>. The heights of the anterior, middle, and posterior portions of the body of each fractured vertebra before and after surgery were measured. These measurements were then compared with the mean heights of the anterior, middle, and posterior portions of the bodies of the upper and lower vertebrae which represented the theoretically normal height of compression vertebra. Then, pre- and post-operative percentage of reduction in vertebral height was calculated by using the formula; % = (height of compression vertebra x 100)/[(height of upper vertebra + height of lower vertebra)/2] (Fig. 1A). The pre- and post-operative angles of kyphosis were also calculated and compared between pre- and post-treatment (Fig. 1B).

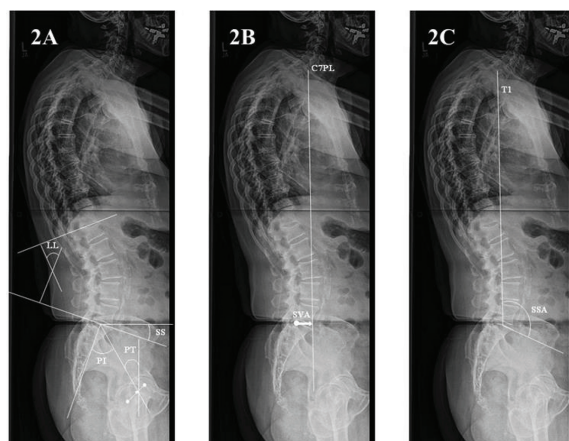
All sagittal pelvic alignment parameters were measured as described by Vrtovec et al<sup>(11)</sup>. The hip axis was defined by the midpoint of the line joining the centers of the femoral heads on the bicoxofemoral axis (Fig. 2A). Pelvic incidence (PI) was the angle between the line joining the hip axis and the center of the S1 endplate and the line orthogonal to the S1 endplate. Sacral slope (SS) was the angle between the line along

the S1 endplate and the reference horizontal line. Pelvic tilt (PT) was the angle between the line joining the hip axis and the center of the S1 endplate and the reference vertical line. Lumbar lordosis (LL) was an angle between the superior endplate of L1 and superior endplate of S1. Sagittal vertical axis (SVA) was the distance between the C7 plumb line and the posterior corner of the sacrum (Fig. 2B). Spinosacral angle (SSA) was angle formed between the line drawn from the front side of T1 to the middle of sacrum and the line passing through the sacral plateau (Fig. 2C).



$$\% = (100xa)/[(a1+a2)/2]$$

**Fig. 1** Representative picture demonstrated the method for calculation of percent collapse of vertebra (1A) and kyphotic angle (1B). Height of the anterior, middle, and posterior portions of the collapsed vertebra body were measured. These were then compared with the means heights of anterior, middle, and posterior portions of the upper and lower non-collapsed vertebra. Then, percent of collapsed vertebra were calculated by the formula:  $\% = (100 \times a) / [(a1 + a2) / 2]$ .



**Fig. 2** Representative radiographic image and drawing line for the measurement of the whole spinal sagittal alignment parameters (PI, SS, PT, LL in 2A, SVA in 2B, and SSA in 2C). All measurements were done by using Sectra IDS7 image viewer computer system.

### Data analysis

All values were expressed as median (min-max). Statistical analysis was performed using StatView for Windows Version 5 (SAS Institute Inc., Cary, NC, USA). Descriptive statistics were calculated, and contingency tables were produced. Chi-squared tests were performed on the categorical variables. Mann-Whitney U tests were used for comparison of the pre-operative radiographic parameters between RF-TVA group and balloon group. For comparison of the parameters between pre- and post-treatment, Wilcoxon signed rank test were used. A  $p$ -value  $< 0.05$  was considered to be statistically significant.

### Results

A total of 33 VCF patients were enrolled in the present study, out of which 16 patients were categorized as RF-TVA group and 17 patients as balloon group. The demographics and pre-operative spinal alignment were shown in Table 1. The average age of the RF-TVA group was  $78.50 \pm 10.41$  years, and that of the balloon group was  $78.29 \pm 6.10$  years. No statistical differences were observed with regard to the age ( $p = 0.94$ ), gender distribution ( $p = 0.29$ ), and all pre-operative spinal alignment parameters (PI, SS, PT, LL, SVA, SSA) ( $p > 0.05$ ) between RF-TVA group and balloon groups.

The effect of either RF-TVA or balloon kyphoplasty on percent collapsed vertebra and kyphotic angle were demonstrated in Table 2. In the RF-TVA group, there were no significant differences in percent collapse of vertebra height between pre- and post-operative ( $p > 0.05$ ) or in kyphotic angle ( $p = 0.17$ ). However, in balloon group, there was a significant difference in percent collapsed vertebral height in post-operative percent especially on anterior ( $p = 0.001$ ) and middle portions ( $p = 0.0008$ ) of the vertebral body. In addition, post-operative kyphotic angle was also significantly decreased when compared with pre-operative kyphotic angle in the balloon group ( $p = 0.03$ ). The degree of correction between pre-operative kyphotic angle and post-operative kyphotic angle for balloon kyphoplasty was  $4.06 \pm 6.04^\circ$ .

The effect of either RF-TVA or balloon kyphoplasty on sagittal alignment were demonstrated in Table 3. There were no significant changes in all sagittal balance parameters (PI, SS, PT, LL, SVA, SSA) in RF-TVA group when comparing pre- and post-operative spinal alignment. However, in balloon group, most of spinal sagittal balance (PI, SS, LL, SVA,

**Table 1.** Demographics data and pre-operative spinal sagittal parameters of osteoporotic compression fracture patients

Parameters	Number of patients (%)		<i>p</i> -value
	RF-TVA group (n = 16)	Balloon group (n = 17)	
Age	80 (49 to 90)	79 (64 to 86)	0.94
Gender			
Male	3 (18%)	6 (35%)	0.29
Female	13 (82%)	11 (65%)	
Pelvic incidence	60.20 (30.5 to 83.5)	61.25 (41.3 to 81.5)	0.95
Sacral slope	36.30 (11.0 to 57.2)	32.70 (19.8 to 50.2)	0.43
Pelvic tilt	23.80 (9.7 to 36.7)	28.45 (8.2 to 40.3)	0.17
Lumbar lordosis	55.45 (11.6 to 78.4)	55.10 (32.4 to 72.2)	0.86
Sagittal vertical axis	5.68 (0.39 to 18.8)	5.77 (-1.0 to 16.0)	0.99
Spinosacral angle	122.60 (93.4 to 140.1)	118.50 (106.5 to 133.5)	0.71

RF-TVA = radiofrequency targeted vertebral augmentation

Data expressed as median (min-max)

*p*-value derived using Mann-Whitney U test for nonparametric unpaired data and Chi-squared test for categorized data

**Table 2.** Comparison of percent collapse (%) of vertebral height and kyphotic angle between pre- and post-treatment in RF-TVA group and balloon group

Parameters	RF-TVA group (n = 16)			Balloon group (n = 17)		
	Pre-treatment	Post-treatment	<i>p</i> -value	Pre-treatment	Post-treatment	<i>p</i> -value
Anterior	62.86 (29.1-98.6)	68.02 (42.3-95.6)	0.14	42.65 (24.4-106.5)	66.21 (36.9-120.5)	0.001
Middle	65.00 (23.1-95.1)	76.15 (30.4-87.9)	0.06	54.47 (29.2-97.1)	70.67 (52.5-100.2)	0.0008
Posterior	84.91 (70.7-101.4)	84.07 (65.6-100.0)	0.07	85.94 (68.8-106.3)	87.93 (72.2-104.6)	0.64
Angle of kyphosis	28.00 (3.0-35.1)	21.20 (2.5-34.4)	0.17	25.45 (0.5-68.9)	22.20 (3.8-61.5)	0.03

Data expressed as median (min-max)

*p*-value derived using Wilcoxon signed rank test for nonparametric paired data

**Table 3.** Comparison of spinal sagittal balance parameters of VCF patients between pre- and post-treatment in RF-TVA group and balloon group

Parameters	RF-TVA group (n = 16)			Balloon group (n = 17)		
	Pre-treatment	Post-treatment	<i>p</i> -value	Pre-treatment	Post-treatment	<i>p</i> -value
Pelvic incidence	60.20 (30.5 to 83.5)	61.70 (36.1 to 84.0)	0.14	61.25 (41.3 to 81.5)	59.50 (35.3 to 73.6)	0.09
Sacral slope	36.30 (11.0 to 57.2)	33.75 (12.7 to 56.1)	0.34	32.70 (19.8 to 50.2)	30.50 (18.2 to 50.9)	0.98
Pelvic tilt	23.80 (9.7 to 36.7)	23.60 (13.5 to 30.2)	0.80	28.45 (8.2 to 40.3)	26.30 (7.4 to 34.3)	0.02
Lumbar lordosis	55.45 (11.6 to 78.4)	55.35 (12.9 to 84.4)	0.06	55.10 (32.4 to 72.2)	54.60 (29.0 to 65.0)	0.68
Sagittal vertical axis	5.68 (0.3 to 18.8)	4.40 (-3.5 to 17.8)	0.33	5.77 (-1.0 to 16.0)	4.94 (-0.5 to 20.5)	0.62
Spinosacral angle	122.60 (93.4 to 140.1)	120.70 (85.1 to 138.4)	0.17	118.50 (106 to 133)	119.70 (100 to 129)	0.82

VCF = vertebral compression fracture

Data expressed as median (min-max)

*p*-value derived using Wilcoxon signed rank test for nonparametric paired data

SSA) were no significant difference except pelvic tilts (*p* = 0.02).

## Discussion

Current literature on vertebral augmentation have shown balloon kyphoplasty to be an effective

procedure in the treatment of VCF providing rapid pain relief, post-operative height restoration, and decreasing in kyphotic angle<sup>(12-14)</sup>. One study by Yokoyama et al demonstrated that kyphoplasty was not only useful for pain relief and improving local spinal kyphosis, but also improved sagittal balance through restoration of

local kyphosis<sup>(5)</sup>. In osteoporosis patients, abnormalities in total spinal alignment have been reported showing a more anterior shift of the C7 plumb line and compensated by a decrease in sacral slope and an increase in pelvic tilt<sup>(5,15,16)</sup>. It has been accepted that the restoration of spinal imbalance correlates with excellent functional outcome<sup>(6,17)</sup>. The RF-TVA had been developed and approved as a minimally invasive procedure effective in improving vertebral height, kyphotic angle, and pain related to compression fracture. It also had less complications when compared to balloon kyphoplasty<sup>(7,9)</sup>. Therefore, we hypothesized that RF-TVA should have equivalent effects as balloon kyphoplasty in correcting both local spinal deformity and the whole spine alignment.

Our results demonstrated that osteoporosis VCF patients in the present study had spinal sagittal imbalance because they had high SVA:  $6.66 \pm 5.48$  cm, and  $6.26 \pm 4.51$  cm in RF-TVA and balloon kyphoplasty groups, respectively. The normal range of SVA in spinal sagittal balance should be in neutral or less than 3 cm from the posterior-superior corner of the S1 body<sup>(16,18,19)</sup>. The high SVA in our VCF patients was also seen in recent studies by Lee et al<sup>(16)</sup> and Yokoyama et al<sup>(5)</sup> reporting values of  $5.97 \pm 3.26$  cm and  $7.0 \pm 3.92$  cm, respectively. Therefore, our results support the hypothesis that osteoporosis VCF patients have anterior wedge deformity leading to progression of kyphotic deformity and an anterior shift of the center of the gravity, resulting in anterior shift of C7 plumb line, and finally causing spinal sagittal balance.

Literature regarding RF-TVA kyphoplasty results on height restoration and kyphotic angle has been controversial. Pflugmacher et al reported that RF-TVA kyphoplasty could increase the height in the middle part of vertebral body and decrease in the average kyphosis angle<sup>(7,9)</sup>. Our results showed that RF-TVA kyphoplasty could not restore vertebral body height in anterior, middle and posterior of vertebral body and could not decrease angle of kyphosis. The lack of improvement in both parameters may be explained by a difference in the amount of bone cement injected into the compressed fracture vertebral body. In contrast to RF-TVA kyphoplasty results, these two parameters (vertebral height restoration and kyphotic angle correction) were improved in our osteoporosis VCF patients treated with balloon kyphoplasty. This has corresponded with the results of many reported studies evaluating the effects of balloon kyphoplasty<sup>(10,13,20)</sup>.

Although balloon kyphoplasty could improve local spinal height and kyphotic angle, our results did

not show statistically significant restoration of the spinopelvic alignment parameters (PI, SS, LL, SVA, and SSA). This finding was controversial, though in the literature, Yokoyama et al demonstrated that balloon kyphoplasty could partial correction of sagittal imbalance in VCF patients on spinal alignment parameters (LL, SVA, and SSA) but not on pelvic parameters (PI, SS, and PT) in one month after surgery<sup>(5)</sup>. Our results showed no change in spinal sagittal balance in balloon kyphoplasty were supported by the study by Korovessis et al<sup>(21)</sup>. Korovessis et al reported no significant changes in the sagittal deviation of plumb line from center of femoral head axis were observed both immediate post-operative and during two years post-operative follow-up<sup>(21)</sup>. The possible explanation for the lack of improvement in spinal sagittal alignment of our VCF patients treated with balloon kyphoplasty was possibly due to the smaller degree of correction in kyphosis angle by balloon kyphoplasty when compared to other techniques such as Smith-Petersen osteotomy<sup>(22)</sup> and pedicle subtraction osteotomy<sup>(23,24)</sup>. These two osteotomy techniques result in an increased degree of kyphotic angle correction at the osteotomy site and compression vertebrae ( $20^\circ$ ) resulting in better overall improvement of the whole spinal sagittal balance than the balloon kyphoplasty ( $4.06 \pm 6.04^\circ$ ). We supposed that multiple level kyphoplasty might improve overall sagittal balance due to cumulative improvements in degrees of correction in kyphotic angle. In addition, late changes may be missed due to the short follow-up period in the present study, and therefore further follow-up time periods may be necessary in order to fully evaluate the effect of local improvement on the whole spinal sagittal balance.

The limitations of the present study included its retrospective design which by nature cannot guarantee unbiased randomization. There were also a limited number of patients who had complete lateral whole spine radiography for radiographic measurement of spinopelvic parameters. The procedures were performed by a single surgeon thus limiting inter-operative variability. While we reported no differences in sagittal balance restoration, the present study did not comment or address the possible differences in safety or leakage rates between the two procedures. Further studies evaluating functional outcomes are required in order to correlate radiographic findings with clinical improvement. Furthermore, longer follow-up periods are necessary to determine if these effects are sustained in the long term. Our group plans to include

more patients and extend the timing for post-operative evaluation to address possible differences in the cement integration and re-fracture rates between both techniques. In addition, the present study did not assess the post-operative pain score in VCF patients in which pain from the fracture also had influence on the sagittal balance<sup>(25)</sup>.

### Conclusion

Both RF-TVA and balloon kyphoplasty did not play a role in improving the whole spine alignment in the treatment of single level VCF. However, balloon kyphoplasty is shown to be an effective procedure leading to regional improvement of the compression vertebral fracture.

### What is already known on this topic?

VCF is known to cause the sagittal imbalance in elderly patients with osteoporosis. For improvement in quality of life, correction of sagittal balance is an important factor. The kyphoplasty now is one of the techniques which can correct the height and kyphotic angle of the compression vertebra. It was recently reported by an orthopedic group in Japan that one level balloon kyphoplasty could corrected the sagittal balance in VCF patients.

### What this study adds?

This study adds the new information about the novel kyphoplasty system (RF-TVA), which could not be used as the tool for correct the whole spine alignment. Up to our knowledge, this is the first report on this topic. Furthermore, we reported the difference results from the previous study by Japanese orthopedic group that balloon kyphoplasty could not correct the whole spine sagittal balance. We suggested that osteoporosis VCF patients who has sagittal imbalance problem should be consider other operative techniques to solve this problem.

### Acknowledgement

The authors would like to thank Ms. Nilsa Flores for assistance in patient's retrieval process and Amelia Ni for IRB approval. The author (Sutipornpalangkul W) would like to thank Siriraj Hospital, Mahidol University, Thailand for financial support on doing the present study.

### Potential conflicts of interest

There was no funding support for the present study. Werasak Sutipornpalangkul, Lester Zambrana,

and Arianna Gianakos declare that they have no conflict of interest. Joseph M Lane is a consultant for Bone Therapeutics, Graftys, Kuros, CollPlant, Agnovos, and Harvest Company.

### References

1. Burge R, Dawson-Hughes B, Solomon DH, Wong JB, King A, Tosteson A. Incidence and economic burden of osteoporosis-related fractures in the United States, 2005-2025. *J Bone Miner Res* 2007; 22: 465-75.
2. Lau E, Ong K, Kurtz S, Schmier J, Edidin A. Mortality following the diagnosis of a vertebral compression fracture in the Medicare population. *J Bone Joint Surg Am* 2008; 90: 1479-86.
3. Edidin AA, Ong KL, Lau E, Kurtz SM. Life expectancy following diagnosis of a vertebral compression fracture. *Osteoporos Int* 2013; 24: 451-8.
4. Savage JW, Schroeder GD, Anderson PA. Vertebroplasty and kyphoplasty for the treatment of osteoporotic vertebral compression fractures. *J Am Acad Orthop Surg* 2014; 22: 653-64.
5. Yokoyama K, Kawanishi M, Yamada M, Tanaka H, Ito Y, Kawabata S, et al. Postoperative change in sagittal balance after kyphoplasty for the treatment of osteoporotic vertebral compression fracture. *Eur Spine J* 2015; 24: 744-9.
6. Le Huec JC, Faundez A, Dominguez D, Hoffmeyer P, Aunoble S. Evidence showing the relationship between sagittal balance and clinical outcomes in surgical treatment of degenerative spinal diseases: a literature review. *Int Orthop* 2015; 39: 87-95.
7. Pflugmacher R, Bornemann R, Koch EM, Randau TM, Muller-Broich J, Lehmann U, et al. Comparison of clinical and radiological data in the treatment of patients with osteoporotic vertebral compression fractures using radiofrequency kyphoplasty or balloon kyphoplasty. *Z Orthop Unfall* 2012; 150: 56-61.
8. Murphy K. Radiofrequency kyphoplasty: a novel approach to minimally invasive treatment of vertebral compression fracture. In: Yue JJ, Guyer R, Johnson JP, Khoo LT, Hochschuler H, Hochschuler SH, editors. *The comprehensive treatment of the aging spine: minimally invasive and advanced techniques*. Philadelphia, PA: Elsevier; 2011: 248-52.
9. Bornemann R, Kabir K, Otten LA, Deml M, Koch EM, Wirtz DC, et al. Radiofrequency kyphoplasty - an innovative method for the treatment of

- vertebral compression fractures - comparison with conservative treatment. *Z Orthop Unfall* 2012; 150: 392-6.
10. de Falco R, Bocchetti A. Balloon kyphoplasty for pure traumatic thoracolumbar fractures: retrospective analysis of 61 cases focusing on restoration of vertebral height. *Eur Spine J* 2014; 23 (Suppl 6): 664-70.
  11. Vrtovec T, Janssen MM, Likar B, Castelein RM, Viergever MA, Pernus F. A review of methods for evaluating the quantitative parameters of sagittal pelvic alignment. *Spine J* 2012; 12: 433-46.
  12. Kumar K, Nguyen R, Bishop S. A comparative analysis of the results of vertebroplasty and kyphoplasty in osteoporotic vertebral compression fractures. *Neurosurgery* 2010; 67: ons171-88.
  13. Kim KH, Kuh SU, Chin DK, Jin BH, Kim KS, Yoon YS, et al. Kyphoplasty versus vertebroplasty: restoration of vertebral body height and correction of kyphotic deformity with special attention to the shape of the fractured vertebrae. *J Spinal Disord Tech* 2012; 25: 338-44.
  14. Voggenreiter G. Balloon kyphoplasty is effective in deformity correction of osteoporotic vertebral compression fractures. *Spine (Phila Pa 1976)* 2005; 30: 2806-12.
  15. Wang HJ, Giambini H, Zhang WJ, Ye GH, Zhao C, An KN, et al. A modified sagittal spine postural classification and its relationship to deformities and spinal mobility in a chinese osteoporotic population. *PLoS One* 2012; 7: e38560.
  16. Lee JS, Lee HS, Shin JK, Goh TS, Son SM. Prediction of sagittal balance in patients with osteoporosis using spinopelvic parameters. *Eur Spine J* 2013; 22: 1053-8.
  17. Berven SH, Deviren V, Smith JA, Hu SH, Bradford DS. Management of fixed sagittal plane deformity: outcome of combined anterior and posterior surgery. *Spine (Phila Pa 1976)* 2003; 28: 1710-5.
  18. Aota Y, Saito T, Uesugi M, Kato S, Kuniya H, Koh R. Optimal arm position for evaluation of spinal sagittal balance. *J Spinal Disord Tech* 2011; 24: 105-9.
  19. Takeda N, Kobayashi T, Atsuta Y, Matsuno T, Shirado O, Minami A. Changes in the sagittal spinal alignment of the elderly without vertebral fractures: a minimum 10-year longitudinal study. *J Orthop Sci* 2009; 14: 748-53.
  20. Van Meirhaeghe J, Bastian L, Boonen S, Ranstam J, Tillman JB, Wardlaw D. A randomized trial of balloon kyphoplasty and nonsurgical management for treating acute vertebral compression fractures: vertebral body kyphosis correction and surgical parameters. *Spine (Phila Pa 1976)* 2013; 38: 971-83.
  21. Korovessis P, Zacharatos S, Repantis T, Michael A, Karachalios D. Evolution of bone mineral density after percutaneous kyphoplasty in fresh osteoporotic vertebral body fractures and adjacent vertebrae along with sagittal spine alignment. *J Spinal Disord Tech* 2008; 21: 293-8.
  22. Cho KJ, Bridwell KH, Lenke LG, Berra A, Baldus C. Comparison of Smith-Petersen versus pedicle subtraction osteotomy for the correction of fixed sagittal imbalance. *Spine (Phila Pa 1976)* 2005; 30: 2030-7.
  23. Chou D, Wang VY, Storm PB. Pedicle subtraction osteotomies for the correction of post-traumatic thoracolumbar kyphosis. *J Clin Neurosci* 2010; 17: 113-7.
  24. Heary RF, Bono CM. Pedicle subtraction osteotomy in the treatment of chronic, posttraumatic kyphotic deformity. *J Neurosurg Spine* 2006; 5: 1-8.
  25. Chaleat-Valayer E, Mac-Thiong JM, Paquet J, Berthonnaud E, Siani F, Roussouly P. Sagittal spino-pelvic alignment in chronic low back pain. *Eur Spine J* 2011; 20 (Suppl 5): 634-40.

---

การศึกษาเปรียบเทียบ *sagittal balance* ระหว่าง *radiofrequency targeted vertebral augmentation* และ *balloon kyphoplasty* ที่ใช้ในการรักษาภาวะกระดูกแตกแบบยุบ: การศึกษาย้อนหลัง

วีระศักดิ์ สุทธิพรพลากร, Lester Zambrana, Arianna Gianakos, Joseph M Lane

**วัตถุประสงค์:** เพื่อเปรียบเทียบประสิทธิผลระหว่างวิธี *high viscosity cement radiofrequency targeted vertebral augmentation (RF-TVA)* และวิธี *balloon kyphoplasty* ต่อ *spinal sagittal balance* ที่ได้จากการประเมินภาพรังสี

**วัสดุและวิธีการ:** ทำการศึกษาย้อนหลังในผู้ป่วยที่ได้รับการรักษาด้วยวิธี *balloon kyphoplasty (Kyphon system)* หรือวิธี *RF-TVA (DFine system)* ระหว่าง พ.ศ. 2550 ถึง พ.ศ. 2557 โดยทำการทบทวนจากเวชระเบียนผู้ป่วยทั้งข้อมูลทั่วไป และผลจากภาพถ่ายรังสีทั้งก่อนและหลังการผ่าตัด โดยตัวแปรที่ทำการวัด ได้แก่ *pelvic incidence (PI)*, *sacral slope (SS)*, *pelvic tilt (PT)*, *lumbar lordosis (LL)*, *sagittal vertical axis (SVA)* และ *spinosacral angle (SSA)*

**ผลการศึกษา:** มีผู้ป่วยจำนวน 33 ราย ที่ถูกรวบรวมเข้ามาในการศึกษานี้ โดย 16 ราย ได้รับการผ่าตัดแบบ RF-TVA และ 17 ราย ได้รับการผ่าตัดแบบ *balloon kyphoplasty* ทั้งสองกลุ่มไม่พบความแตกต่างทั้งอายุ เพศ และ ตัวแปร *spinal sagittal alignment* ก่อนการผ่าตัด ผู้ป่วยกลุ่มที่ได้รับการรักษาด้วยวิธี RF-TVA ไม่พบความแตกต่างของเปอร์เซ็นต์ *vertebral collapse* และมุม *kyphotic* ทั้งก่อนและหลังผ่าตัด แต่ผู้ป่วยกลุ่มที่ได้รับการรักษาด้วยวิธี *balloon kyphoplasty* พบความแตกต่างของเปอร์เซ็นต์ *vertebral collapse* และมุม *kyphotic* ทั้งก่อนและหลังผ่าตัด โดยผู้ป่วยทั้งสองกลุ่มนี้ไม่มี การเปลี่ยนแปลงของ *spinal sagittal alignment* ทั้งก่อนและหลังผ่าตัด

**สรุป:** วิธี RF-TVA และ *balloon kyphoplasty* ที่ใช้ในการรักษาภาวะกระดูกแตกแบบยุบ ไม่มีผลต่อการเพิ่มขึ้นของ *whole spine alignment*

---